

Prevalence of Avascular Necrosis of Femoral Head in Diabetic Patients Who Have Undergone Kidney Transplant

¹ Shruti Sudhir Dubal, ² Dr. Poonam Patil

¹Final Year Student, Krishna College of Physiotherapy, KVV, 415539, Agashivnagar, Malkapur, Maharashtra, India. Email: @gmail.com

²Associated Professor, Department of Cardiopulmonary, Krishna College of Physiotherapy, Krishna Vishwa Vidyapeeth, Karad (Corresponding Author). Email: @gmail.com

ABSTRACT

BACKGROUND-

Avascular necrosis (AVN), or osteonecrosis, is the death of bone tissue due to reduced blood supply, commonly affecting the femoral head. It leads to bone collapse, joint dysfunction, and chronic pain. Kidney transplant patients, especially those with diabetes, are at increased risk due to prolonged use of corticosteroids and other immunosuppressive drugs. Additionally, vascular complications and metabolic imbalances in diabetic individuals may further contribute to AVN development. Despite its clinical importance, awareness of AVN in post-kidney transplant patients remains low. Early diagnosis is essential to prevent joint damage and disability. This study focuses on determining the prevalence of femoral head AVN in diabetic kidney transplant patients in Satara district, aiming to enhance awareness and guide early intervention.

OBJECTIVE-

1. To find out how prevalent is avascular necrosis of femoral head in diabetic patients among people undergone kidney transplant.
2. To calculate the prevalence of AVN in post-transplant patients.
3. To calculate the percentage of post kidney transplant patients who have developed AVN compared to overall population

METHODOLGY-

A retrospective observational study was conducted in Satara using simple random sampling. A total of 49 diabetic post-kidney transplant patients aged 25–50 years were included. Exclusion criteria were metallic joint replacement, other bone diseases, and pre-transplant status. Data collection involved a validated online questionnaire, MRI reports, and consent forms. After obtaining ethical approval, eligible participants were informed, consented, and given the questionnaire. Responses were analysed statistically to assess the prevalence of femoral head avascular necrosis.

RESULT-

The study included 49 participants with a mean age of 36.5 years and a standard deviation of 5.272. The p-value was found to be greater than 0.10, indicating no statistically significant difference. All 49 participants (100%) responded "Yes" to participating in the study. Regarding awareness and experience, 49% reported relevant symptoms or knowledge, while 0% reported none. In terms of transplant status, 100% of participants were post-transplant. Only 6.1% of participants reported having a history of fracture, joint pain, or complications such as AVN, while 93.9% did not. Notably, none of the participants had any metallic joint replacements. These findings suggest that while a significant portion of post-transplant diabetic patients reported relevant joint-related issues, the overall prevalence of complications such as AVN remains relatively low in this sample.

CONCLUSION-

study found hundred percentages of responses. A very few people having history of hip pain. Among 26.5% females and 73.5% males 6.12% of patients suffering through post kidney transplant avascular necrosis.

KEYWORDS- Avascular Necrosis, Femoral Head, Kidney Transplantation, Diabetic Patients, Prevalence Study

How to cite this article: Dubal SS, Patil P. Prevalence of Avascular Necrosis of Femoral Head in Diabetic Patients Who Have Undergone Kidney Transplant. *Int J Drug Deliv Technol.* 2026;16(8s): 997-1000; DOI: 10.25258/ijddt.16.8s.112

INTRODUCTION

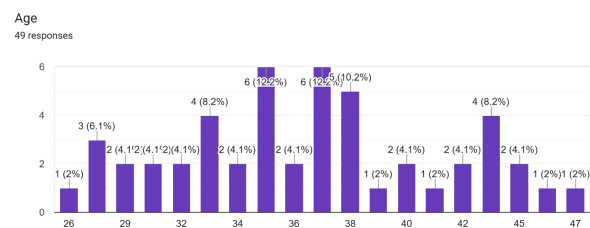
Avascular necrosis (AVN), or osteonecrosis, is the death of bone tissue due to disrupted blood supply. The

PREVALENCE OF AVASCULAR NECROSIS OF FEMORAL HEAD IN DIABETIC PATIENTS WHO HAVE UNDERGONE KIDNEY TRANSPLANT

femoral head is the most commonly affected site, with less frequent involvement of the jaw, talus, knee, and humeral head. It is typically seen in adults aged 20–40 and often occurs bilaterally, causing persistent thigh pain and, over time, secondary osteoarthritis. The main blood supply to the femoral head comes from the medial circumflex femoral artery and retinacular arteries; any disruption can lead to AVN. Risk factors include high corticosteroid use, immunosuppressive therapy, elevated blood urea nitrogen, and vascular issues such as ischemia or thrombosis. Corticosteroids may directly suppress osteoblast activity, reducing bone formation. AVN progresses in stages, from normal radiographs with positive biopsy (Stage 1) to joint destruction and osteoarthritis (Stage 4). Advanced cases often require hip replacement. Chronic kidney disease (CKD) is defined by structural or functional kidney abnormalities lasting over three months. Treatment options include dialysis or kidney transplantation. Post-transplant patients are prone to bone disorders collectively termed post-transplant bone disease, which includes osteoporosis, fractures, renal osteodystrophy, and AVN. The link between kidney transplantation and AVN highlights the need for early detection and management.

any metallic joint replacements, other bone diseases, or who had not yet undergone transplantation were excluded. Data was collected using a validated questionnaire (distributed via Google Forms), MRI reports, and consent forms. The questionnaire gathered information related to kidney transplantation, the presence of joint pain, and any history of fractures. Ethical clearance and permission were obtained from the protocol committee. Participants meeting the inclusion criteria were informed about the study, and consent was taken. The structured questionnaire was then circulated online among eligible kidney transplant patients, and responses were collected and analysed statistically.

4. RESULT:



| Mean | Standard deviation | P value |
|------|--------------------|---------|
| 36.5 | 5.272 | >0.10 |

1. AIM:

To find prevalence of avascular necrosis of femoral head in diabetic patients who have undergone kidney transplant in Satara district.

2. OBJECTIVE:

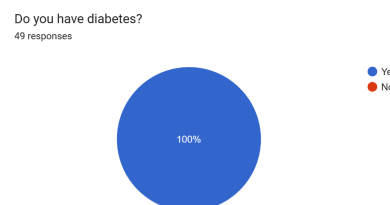
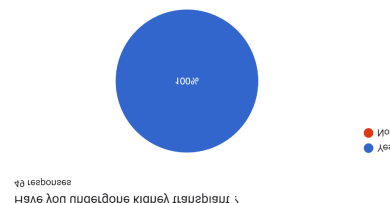- To find out how prevalent is avascular necrosis of femoral head in diabetic patients among people undergone kidney transplant.
- To calculate the prevalence of AVN in post-transplant patients.
- To calculate the percentage of post kidney transplant

| Response | Frequency | Frequency percentage |
|----------|-----------|----------------------|
| Yes | 49 | 100% |
| No | 0 | 0% |

patients who have developed AVN compared to overall population

3. MATERIAL AND METHODOLOGY:

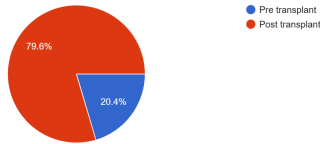
This retrospective observational study was conducted in Satara using a simple random sampling method. The study included 49 male and female participants aged between 25 to 50 years, all of whom were diabetic and had undergone kidney transplantation. Patients with



| Response | Frequency | Frequency percentage |
|----------|-----------|----------------------|
| Yes | 49 | 49% |
| No | 0 | 0% |

PREVALENCE OF AVASCULAR NECROSIS OF FEMORAL HEAD IN DIABETIC PATIENTS WHO HAVE UNDERGONE KIDNEY TRANSPLANT

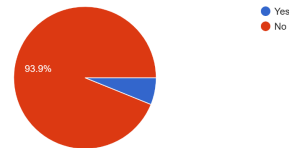
when you developed diabetes?
49 responses



| Response | Frequency | Frequency percentage |
|-----------------|-----------|----------------------|
| Pre transplant | 10 | 20.4% |
| Post transplant | 39 | 79.6% |

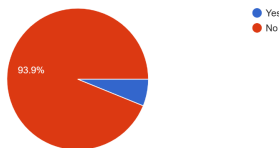
| | | |
|----|----|-----|
| No | 49 | 49% |
|----|----|-----|

Have you done any investigation for hip pain ?
49 responses



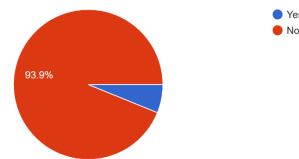
| Response | Frequency | Frequency percentage |
|----------|-----------|----------------------|
| Yes | 3 | 6.1% |
| No | 46 | 93.9% |

Do you have any difficulty in walking ?
49 responses



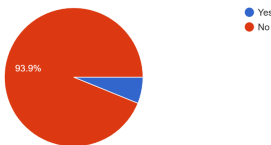
| Response | Frequency | Frequency percentage |
|----------|-----------|----------------------|
| Yes | 3 | 6.1 |
| No | 46 | 93.9 |

Are you on medication for hip pain ?
49 responses



| Response | Frequency | Frequency percentage |
|----------|-----------|----------------------|
| Yes | 3 | 6.1% |
| No | 46 | 93.9% |

Do you have hip pain ?
49 responses



| Response | Frequency | Frequency percentage |
|----------|-----------|----------------------|
| Yes | 3 | 6.1% |
| No | 46 | 93.9% |

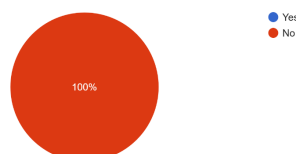
5. DISSCUSSION:

This is observational study aimed to find avascular necrosis in patients who have undergone kidney transplant. In this study we are aimed to find avascular necrosis. For these we conclude results from responses of structured questionnaire with hundred percent response. We conduct survey about sixteen questions among 49 kidney transplant patients. Prevalence of avascular necrosis in male is more than female according to response. According to result among 49 participants 13 females and 36 males. A qualitative studies males are more prone to avascular necrosis. In this study kidney diseased person greatest occurrence of avascular necrosis, it is due to a use of steroids and immunosuppressants. Individuals after kidney transplant can prevent the complications by knowing. This can help to analyse and resolve arising problems in early stage. Educating about these changes in patients after kidney transplant to reduce the risk factor arising due to kidney transplant complications.

6.CONCLUSION:

The study found hundred percentages of responses. A very few people having history of hip pain. Among

Have you had any fracture of hip?
49 responses



| Response | Frequency | Frequency percentage |
|----------|-----------|----------------------|
| Yes | 0 | 0% |

PREVALENCE OF AVASCULAR NECROSIS OF FEMORAL HEAD IN DIABETIC PATIENTS WHO HAVE UNDERGONE KIDNEY TRANSPLANT

26.5% females and 73.5% males 6.12% of patients suffering through post kidney transplant avascular necrosis.

7. LIMITATION: Small sample size. Retrospective design of most available studies limit data quality, as these studies rely heavily on existing medical records may clinically silent in early stages, and without routine screening via MRI many cases are missed.

8. REFERENCE:

1. Mehdi Teimouri¹, Mehdi Motififard¹, Saeed Hatami² Etiology of Femoral Head Avascular Necrosis in Patients A Cross-Sectional Study
2. Young Min Ko, M.D.¹, Hyunwook Kwon, M.D.¹, Sung Jin Chun, M.D.¹, Young Hoon Kim, M.D.¹, Ji Yoon Choi, M.D.¹, Sung Shin, M.D.¹, Joo Hee Jung, M.D.¹, Su-Kil Park, M.D.² and Duck Jong Han, M.D.¹ Predictors of Avascular Necrosis after Kidney Transplantation
3. Nathan R. Hill^{1*}, Samuel T. Fatoba¹, Jason L. Oke¹, Jennifer A. Hirst¹, Christophe A. O'Callaghan², Daniel S. Lasserson¹, F. D. Richard Hobbs¹ Global Prevalence of Chronic Kidney Disease – A Systematic Review and Meta-Analysis
4. Wojciech Konarski ^{1,*}ORCID, Tomasz Poboży ¹ORCID, Andrzej Kotela ², Andrzej Śliwczyński ³ORCID, Ireneusz Kotela ⁴, Martyna Hordowicz ⁵ORCID and Jan Krakowiak ³ORCID Does Diabetes Mellitus Increase the Risk of Avascular Osteonecrosis? A Systematic Review and Meta-Analysis
5. Shih-Wei Lai ORCID logo ; Cheng-Li Lin; Kuan-Fu Liao Real-World Database Examining the Association Between Avascular Necrosis of the Femoral Head and Diabetes in Taiwan
6. Roy K. Aaron, Anne Voisinet, Jennifer Racine, Yousaf Ali, Edward R. Feller Corticosteroid-associated avascular necrosis: dose relationships and early diagnosis
7. Mohammad Amin Kerachian, Edward J. Harvey, Denis Cournoyer, Terry Y. K. Chow & Chantal Séguin Avascular Necrosis of the Femoral Head: Vascular Hypotheses
8. Bailey, George L.; Griffiths, Harry J. L.; Mocelin, Altair J.; Gundy, David H.; Hampers, Constantine L.; Merrill, J. P.. AVASCULAR NECROSIS OF THE FEMORAL HEAD IN PATIENTS ON CHRONIC HEMODIALYSIS. Transactions - American Society for Artificial Internal Organs 18(1):p 401-404, April 1972.
9. Khoury, Jad A.; Brennan, Daniel C.. Infectious Complications in Kidney Transplant Recipients: Review of the Literature. Saudi Journal of Kidney Diseases and Transplantation 16(4): p 453-497, Oct–Dec 2005.
10. CRUESS, RICHARD L.; BLENNERHASSETT, JOHN; MACDONALD, F. ROBERT; MACLEAN, LLOYD D.; DOSSETOR, JOHN. Aseptic Necrosis Following Renal Transplantation. The Journal of Bone & Joint Surgery 50(8):p 1577-1590, December 1968.
11. Nixon JE. Avascular Necrosis of Bone: A Review. *Journal of the Royal Society of Medicine*. 1983;76(8):681-692.
doi:[10.1177/014107688307600810](https://doi.org/10.1177/014107688307600810)