RESEARCH PAPER

Comparison of Proximal Contacts, Contours and Forces of Class-II Dental Composite Restorations in Premolar and Molar Teeth Using Six Different Dental Matrix Systems Following FDI Criteria: An In-Vivo Study

Dr. Srikumar G.P.V.[1*], Dr. Saurabh P. Vairagade[2], Dr. Hrishikesh D. Kande[3], Dr. Trisha Mandal[4], Dr. K. Keerthivasan[5], Dr. Vaibhavee Kurrey[6]

[1]Academic Dean, Professor and H.O.D., Department of Conservative Dentistry and Endodontics, Triveni Institute of Dental Sciences, Hospital and Research Centre, Bilaspur, Chhattisgarh, India

[2]Post-Graduate Student, Department of Conservative Dentistry and Endodontics, Triveni Institute of Dental Sciences, Hospital and Research Centre, Bilaspur, Chhattisgarh, India

[3]Post-Graduate Student, Department of Pedodontics and Preventive Dentistry, Modern Dental College & Research Centre, Indore, India

[4]Post-Graduate Student, Department of Conservative Dentistry and Endodontics, Hazaribag College of Dental Sciences and Hospital, Hazaribag, India

[5]Post-Graduate Student, Department of Conservative Dentistry and Endodontics, Sri Venkateshwaraa Dental College, Puducherry, India

[6]Master of Public Health Graduate, Indian Council of Medical Research, NIHR, Bhubaneswar, India

***Corresponding Author:** Dr. Srikumar G.P.V., Academic Dean, Professor and H.O.D., Department of Conservative Dentistry and Endodontics, Triveni Institute of Dental Sciences, Hospital and Research Centre, Bilaspur, Chhattisgarh, India

Mobile: 9685514220

Email: drsrikumar2611@gmail.com

Received: 25th October 2026; **Revised:** 28th October 2026; **Accepted:** 3rd November 2026; **Available Online:** 7th November 2026

ABSTRACT

Aim:
In-vivo comparative evaluation of proximal contact tightness, floss evaluation, proximal contour, radiographic contour and marginal adaptation of Class-II dental composite restorations in premolar and molar teeth using six different dental matrix systems following FDI criteria.

Materials and Methods:

Ninety patients with Class-II caries lesions in vital premolar and molar teeth were enrolled after written informed consent. Standardized cavities were prepared and restored by a single operator using the same dental adhesive and nano-hybrid composite restoration. Teeth were randomly allocated based on the type of dental matrix system used (15 each). Group 1: Tofflemire; Group 2: Ivory No. 1 circumferential; Group 3: TOR VM Sectional; Group 4: Sectional contoured; Group 5: ET Automatrix; Group 6: Astek Automatrix. All prepared cavities were restored using nano-hybrid composite resin. A single blinded evaluator then assessed all restorations following FDI criteria, dental floss evaluation, and post-operative bitewing radiographic evaluation.

Results:
Data were analysed with SPSS version 22.0 using the Chi-square test; $P<0.05$ was considered statistically significant. The Sectional contoured matrix (Group 4) showed ideal contacts (86.7%), normal contour in 93.3%, and was rated excellent in overall quality of all composite restorations. The ET and Astek Automatrix systems (Groups 5 and 6) exhibited poor contacts, contours and restoration overhangs (86.7% and 93.3%), with restorations rated as not acceptable.

Conclusion:
The sectional contoured dental matrix system showed the most favourable results and was rated as excellent for proximal contact and contours among the six matrix systems tested. The ET and Astek Automatrix systems showed poor contact, contour and marginal adaptability, and all of their composite restorations were rated as not acceptable.

Keywords: Matrix systems, Proximal contact, Class-II composite restorations, FDI criteria, Sectional matrix

How to cite this article: *Srikumar G.P.V.1* Dr. Saurabh P. Vairagade2 Dr. Hrishikesh D. Kande3 Dr. Trisha Mandal4 Dr. K. Keerthivasan5 Dr. Vaibhavee Kurrey6. Comparison of Proximal Contacts, Contours and Forces of Class-II Dental Composite Restorations in Premolar and Molar Teeth Using Six Different Dental Matrix Systems Following FDI Criteria: An In-Vivo Study. Int J Drug Deliv Technol. 2026;16(90s):1657-1667. DOI: 10.25258/ijddt.16.90s.166.*

Source of support: ***Nil.***

Conflict of interest: *None*

INTRODUCTION:

The restoration of tooth structure represents a fundamental objective of Restorative dentistry, requiring the clinician to restore not only the anatomical form, also the function and esthetics of the affected teeth.[1] Among the essential aspects of Class-II restorations, establishing ideal proximal contact and contours is critical for maintaining periodontal health, preventing food impaction, secondary caries and also preserving the integrity of the dental arch.[2] Ideal proximal contacts protect the interdental papilla by preventing food accumulation, transmit occlusal forces along the long axis of the teeth and also contribute significantly to the esthetics of teeth.[3]

Improper proximal contacts in Class-II restorations can lead to multiple complications, including gingival inflamation, secondary caries, food impaction and abnormal tooth migration.[4] Additionally, inadequate proximal contours can result in periodontal pocket formation and compromise the healthy periodontal tissues.[5] Conversely, excessively tight proximal contacts may cause excessive pressure on interdental tissues, potentially leading to tissue damage and patient discomfort.[6] Therefore, achieving the optimal balance of proximal contact tightness and appropriate tooth contour are the most challenging aspects of contemporary restorative dentistry.[7]

The evolution of Dental composite resins over the past decades has shifted the paradigm of restorative dentistry toward a more biologically conservative and adhesive-based treatment approach.[8] Composite resins offer significant advantages over traditional used restorative materials, with its superior esthetics, improved mechanical properties and the ability to be bonded directly to tooth structure with minimal tooth preparation.[9] However, the clinical challenge of achieving and maintaining the tight proximal contacts in Class-II composite restorations remains as a great challenge to many dental clinicians.[10] This challenge gets further complicated due to polymerization shrinkage of composite resins, thereby compromising the marginal adaptation, particularly in the cervical margins of Class-II cavities.[11]

The Dental Matrix system used during composite restoration plays a decisive role to establish and maintain ideal proximal contact and contour of teeth.[12] Various Dental Matrix systems were introduced over the years, each with distinct design features and clinical applications. Traditionally, Circumferential dental matrix systems such as, the Tofflemire Matrices have been widely used in restorative dental practice; however, they have limitations in achieving consistently tight proximal contacts and physiologically appropriate tooth contours.[13] The relatively flat nature of circumferential matrix bands used often results in the inadequate proximal contour reproduction, particularly at the height of the tooth contact.[14]

In recent years, Sectional matrix systems were introduced and gained considerable attention in restorative dentistry. They feature pre-contoured matrix bands and sophisticated contact ring matrix designs that are specifically engineered to produce superior proximal contacts and anatomically ideal tooth contours.[15] These matrix systems combined with separation rings provide significantly tighter proximal contacts compared to traditional circumferential matrix systems.[16] Additionally, the use of separation rings have shown to have a greater influence on proximal contact tightness than the composite resin itself or the placement technique employed during restorative treatment.[17]

The evaluation of Dental restorations using standardized criteria is essential for objective assessment of clinical treatment outcome. The FDI (Federation Dentaire Internationale) criteria, as stated by Hickel R et al[18] have become the accepted standard for evaluation of Direct restorations in contemporary clinical dentistry. This criteria provide comprehensive and precise evaluation in the quality of dental restorations, including assessment of approximal anatomical form encompassing both contact point and contour of teeth, as well as radiographic evaluation of functional characteristics.[19] The FDI criteria have demonstrated superior sensitivity and precision compared to the modified USPHS (United States Public Health Service) criteria, also known as the Ryge criteria.[20]

Proximal contact tightness is traditionally assessed by passing dental floss through the contact area, with resistance to passage scored on a standardized scale ranging from "clinically excellent" (characteristic snap effect) to "clinically poor" (excessively loose contact allowing food

impaction).[21] More objective quantitative methods also exist, includes force measurement techniques using calibrated instruments to measure the maximum resistance encountered during passage of a standardized material through the proximal contact interface.[22] The evaluation of proximal contour morphology involves both clinical assessment using explorers and radiographic examination to determine whether the restoration reproduced physiologic proximal anatomy, maintained appropriate continuity with adjacent tooth surfaces or exhibit under-contoured or over-contoured tooth morphology.[23]

While many previous studies[9,12,16] have compared different matrix systems in the context of single tooth type or specific restorative materials, limited evidence exists regarding direct comparison of multiple dental matrix systems on premolar and molar teeth in a standardized clinical setting using comprehensive FDI evaluation criteria. Furthermore, studies examining the forces associated with proximal contact and the relationship between contact tightness and contour morphology of Class-II composite restorations using different matrix systems are less reported.

Therefore, the objective of our In-vivo study was to compare proximal contacts, contours and forces of Class-II dental composite restorations in premolar and molar teeth using six different Dental Matrix systems following FDI criteria.

Methodology:

A total of 90 patients diagnosed with Class-II dental caries (G.V. Black Criteria) lesions requiring restorative treatment were chosen from the Out-patient clinic in the Department of Conservative Dentistry and Endodontics at Triveni Institute of Dental Sciences, Hospital and Research Centre, Bodri, Bilaspur, Chhattisgarh, India. Clinical evaluation was performed using pulp sensibility test (Electric pulp testing) to ascertain tooth vitality and thus included in the study protocol. Thereafter, standardized pre-operative bitewing radiographs were obtained to assess caries lesion extent into the proximal surface of each tooth and also to check the proximity of the carious lesion to the dental pulp. The study sample (n=90) included teeth with conventional or conservative Mesio-Occlusal (MO) or Disto-Occlusal (DO) caries, without pulpal involvement among the maxillary and mandibular premolar and molar teeth, suitable for restorative treatment were only included in our In-vivo study. After obtaining the Ethical clearance from the Institutional Ethics Committee of TIDSHRC; Approval No. IEC/DHR/2025-2026/SS012 the study was conducted in accordance with the ethical principles outlined in the Declaration of Helsinki.[24]

Following patients (n=90) acceptance for restorative treatment, a detailed explanation of the treatment procedure was provided to the patient and informed written consent was obtained. Restorative treatment commenced with caries excavation using a No. 2 round diamond bur (Mani Inc., Tochigi, Japan) attached to high-speed airoter handpiece under water coolant to ensure efficient removal of carious tooth structure, while minimizing thermal insult. Subsequently standardized Class-II cavity preparations were completed using a No. 245 carbide bur (Mani Inc., Tochigi, Japan) in all patients.

All the patients (n=90) were then randomly assigned into six groups, 15 teeth per group, based on the dental matrix system used during dental composite restorative treatment.

Group 1 (n=15): Tofflemire Matrix System: For teeth allocated to Group 1, Tofflemire matrix system (Keystone Industries, Singen, Germany) was positioned circumferentially around the prepared tooth. Following matrix adaptation, an interdental wedge (Huanghua Promise Dental Co., Ltd. China) was placed to secure the matrix band at the cervical aspect of the tooth. The proximal contact area was subsequently burnished to obtain intimate adaptation of the matrix band against the tooth as well as the adjacent tooth, to prevent any discernible discrepancy at the contact interface.

Group 2 (n=15): Ivory No. 1 Circumferential Matrix System: Ivory No. 1 circumferential matrix system (GDC Fine Crafted Dental Pvt. Ltd., India) was placed around the prepared tooth. An interdental wedge (Huanghua Promise Dental Co., Ltd. China) was then inserted to facilitate stabilization and cervical adaptation of the matrix band. Thereafter, the contact region was burnished to achieve close adaptation between the matrix and the adjacent proximal surface.

Group 3 (n=15): TOR VM Sectional Matrix System: TOR VM sectional matrix system (FilayDent, Mumbai, India) was used. The sectional matrix band was positioned along the prepared proximal surface, followed by insertion of an interdental wedge (Huanghua Promise Dental Co., Ltd. China). A separation ring was subsequently seated using forceps to generate controlled interdental separation and maintain matrix adaptation during the restorative procedure.

Group 4 (n=15): Dental Sectional Contoured Matrix System: Dental Sectional Contoured Matrix system (Contoured Matrix Forming Sheet Clamp; NMD, Mumbai, India) was used. Following placement of the pre-contoured sectional matrix band, an interdental wedge (Huanghua Promise Dental Co., Ltd. China) was inserted to enhance cervical adaptation. A separation ring was then positioned using forceps to provide interdental separation and stabilize the matrix assembly.

Group 5 (n=15): ET Automatrix System: ET Automatrix system (NMD, Nexus Medodent, Mumbai, India) was used. The automatrix band was placed around the prepared tooth and secured within the embrasure. Subsequently, an interdental wedge (Huanghua Promisee Dental Co., Ltd. China) was inserted to facilitate adaptation of the matrix band at the gingival margin and ensure positional stability on the tooth.

Group 6 (n=15): Astek Automatrix System: Astek Automatrix system (Libral Traders, Okhla, Delhi, India) was used. The automatrix band was adapted circumferentially around the prepared tooth and stabilized within the embrasure area. An interdental wedge (Huanghua Promisee Dental Co., Ltd. China) was thereafter inserted to enhance matrix adaptation at the cervical margin and maintain stability of the assembly throughout the operative and restorative procedure.

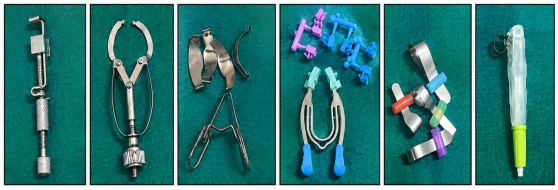

Figure no. 1: Six matrix systems used in our study; A: Tofflemire Matrix System, B: Ivory No. 1 Matrix System, C: TOR VM Sectional Matrix Sy[A], D: Dental [B]onal Contoure[C] Matrix Sy, E: ET Au[D]trix System, [E] Astek Automatrix System.

Following appropriate adaptation of the assigned dental matrix system as per the group, the walls of prepared cavities were first acid etched using 37% phosphoric acid gel (Prime Dental Products Pvt. Ltd., Maharashtra, India) for 15 seconds, thoroughly rinsed with water and gently air-dried. Subsequently, dental adhesive (Coltene® One Coat Bond, Altstatten, Switzerland)) was applied in accordance with the manufacturer's instructions. Restoration of the prepared Class-II cavities were done using Nano-hybrid dental composite resin (Tetric N-Bond, Ivoclar Vivadent, Schaan, Liechtenstein) placed in incremental layering technique of approximately 1 mm thickness. Each increment was photo-polymerized for 20 seconds using a Light-Emitting Diode (LED) composite curing light (Woodpecker iLED; Mayapuri, Delhi, India) following manufacturer instructions in all patients (n=90). Following the removal of the respective matrix assembly in each patient, additional light curing of dental composite resin was done from both buccal and lingual aspects of teeth further 20 seconds. To eliminate inter-operator-dependent variability, in all patients restorative treatment was done by a single experienced clinician.

In all patients, Finishing and polishing of composite restorations was done using abrasive disc system (Super-Snap® Rotary Polishing Instruments Mini Kit; Shofu Inc., Kyoto, Japan). Initial contouring of composite resin was done with coarse and medium-coarse discs to refine gross anatomical form and harmonize the restoration with the adjacent dentition. Subsequent polishing with fine and extra-fine discs (Super-Snap® Rotary Polishing Instruments Mini Kit; Shofu Inc., Kyoto, Japan) was done to enhance surface smoothness. Interproximal finishing strips (Shofu composite Finishing and Polishing Kit Inc., Kyoto, Japan) were then used to remove residual flash and refine proximal embrasures. Finally, occlusal relationship with the opposing teeth were evaluated using articulating paper (Bausch Articulating Paper, 40 mm, Cologne, Germany) and any premature contacts were selectively adjusted to establish a normal physiologic occlusion.

All dental composite restorations were clinically evaluated by a single independent-blinded evaluator not involved in the restorative treatment phase of our study, unaware of the type of matrix system used, thereby minimizing potential assessment bias and outcome determination. Clinical assessment was conducted in accordance with the F[D]Vorld Dental [E]ration criter[F]r the evaluat[ ]f direct resto[ ]ns, with emp[ ]s on the proximal

contact integrity and proximal contour morphology of composite resin restoration. Proximal contact integrity was evaluated using a standardized protocol involving the passage of dental floss and a 25-µm metallic blade along the interdental contact area, the resistance encountered during its passage were recorded and categorized according to pre-defined scoring criteria,[18] (Table no. 1 and Table no. 2). Simultaneously, proximal contour was assessed to determine the extent to which the restoration reproduced normal physiologic anatomy and maintained appropriate continuity with adjacent tooth surfaces.

Score	Category	Criteria (Dental Floss)	Clinical Interpretation
1	Clinically Excellent	Dental floss passes through the contact with a characterist	Normal physiological proximal contact.

		ic snap effect.	
2	Clinically Good	Dental floss passes only with noticeable pressure; no snap or a reduced snap effect.	Slightly tighter than ideal but clinically acceptable with no disadvantage .
3	Clinically Satisfactory	Dental floss passes easily with minimal resistance.	Contact is somewhat weak but does not cause damage to the tooth, gingiva, or periodontal tissues.
4	Clinically Unsatisfacto ry	Dental floss passes very freely with little or no resistance.	Contact is too weak, increasing the risk of food impaction.
5	Clinically Poor	Contact is absent or extremely loose; food impaction, pain, or gingival inflammati on is present.	Repair or replacement of the restoration is indicated.

Table no. 1: Evaluation of Proximal Contact Using Dental Floss[18]

Scor e	**Category**	**Criteria (Metal Blade)**	**Clinical Interpretati on**
1	Clinically Excellent	**25-µm** metal blade passes through the contact with a characterist ic resistance (snap effect).	Normal physiological proximal contact.
2	Clinically Good	**25-µm** metal blade passes only with firm pressure.	Contact is slightly stronger than ideal but clinically acceptable.
3	Clinically Satisfactory	**50-µm** metal blade can pass through the contact.	Contact is somewhat weak but without damage to the tooth, gingiva, or periodontal tissues.
4	Clinically Unsatisfacto ry	**100-µm** metal blade can pass through the contact.	Contact is too weak, with a potential risk of food impaction.
5	Clinically Poor	Contact is excessively open; associated with food impaction, pain, and/or gingivitis.	Repair or replacement of the restoration is required.

Table no. 2: Evaluation of Proximal Contact Using Metal Blade[18]

Standardized post-operative bitewing radiographs were obtained for each composite restoration and assessed for Quality of the proximal restoration, including the presence or absence of proximal overhangs of composite resin, proximal contact integrity and contour. Assessment was performed according to pre-defined FDI evaluation criteria[3] and all observational data was recorded and tabulated to facilitate objective comparison among the study groups.

Score	**Category**	**Radiographic Description**
1	Correct	Proximal contour of the restoration is smooth, physiologically convex, and continuous with the adjacent tooth surface

		without step formation
2	Undercontour	Proximal surface of the restoration is concave or flat relative to the adjacent tooth, indicating deficient material placement in the contact area
3	Overcontour	Proximal surface of the restoration is excessively convex or bulging beyond the normal tooth contour, indicating excess material

Table no. 3: Evaluation of Proximal Contour (Radiographic)[18]

Proximal contact tightness was assessed immediately following completion of the restorative treatment by the same independent blinded examiner unaware of the type of dental matrix system allocation throughout the study period. Quantitative assessment was performed using a modified Pull-through technique coupled with Force measurement using a Portable Electronic scale (WH-A08; The Nextstore, New Delhi, India), a calibrated weight-based measuring device.

For the Pull-through Force measurement, a standardized matrix strip (0.05 mm thickness, 6 mm width, with working length of approximately 20–25 mm) was passed along the restored proximal contact area of each tooth in all patients attached to the electronic scale. The maximum force required to withdraw the matrix strip from inter-dental space was recorded and tabulated. The measuring protocol was standardized with an upper force limit of 5 Newton (N), representing the maximum measurable contact tightness within the predefined assessment range.[3] Values below this threshold were interpreted as indicative of comparatively reduced proximal contact tightness of the composite resin. To improve the measurement reliability and reduce random error, two consecutive measurements were obtained under identical testing conditions. The mean of the two recorded values was subsequently calculated and the data was used for statistical analysis.

RESULTS:

The tabulated data in Microsoft Excel was analysed with SPSS (Statistical Package for the Social Sciences) version 22.0 software. The Chi-square test was used for the statistical analysis. P value < 0.05 was considered statistically significant.

Proximal contact tightness: An ideal contact was seen most often in Group 4 (86.7%), followed by Group 1 (33.3%), and in not seen in the other groups tested. Strong contacts were common in Group 3 (93.3%) and 2 (73.3%), whereas, contacts that were too weak were seen only in Group 5 (73.3%) and 6 (66.7%). No group showed loose or open contact. The difference among the groups was statistically significant (P < 0.001) (Table no. 4 & Graph no. 1).

ontact tightn	**roup =15(%**	**roup =15(%**	**roup =15(%**	**roup =15(%**	**roup =15(%**	**roup =15(%**
Ideal contact	(33.	0	0	(86.	0	0
Slightly weak	(66.	(26.	(6.7	(13.	(6.7	(20.
Strong	0	(73.	(93.	0	(20.	(13.
Too weak	0	0	0	0	(73.	(66.

Table no. 4: Proximal Contact tightness among the six groups tested, n (%: Percentage)

Floss evaluation: Floss passed with a slight snap (ideal) only in Group 4 (53.3%) and Group 1 (40.0%). Floss passed loosely in most restorations of Group 3 (73.3%) and in about half of Group 5 and 6. Floss shredded only in Group 5 (40.0%), 6 (26.7%) and in Group 3. The difference was statistically significant (P < 0.001) (Table no. 5 & Graph no. 2).

Floss evaluation	**Group 1 n=15(%)**	**Group 2 n=15(%)**	**Group 3 n=15(%)**	**Group 4 n=15(%)**	**Group 5 n=15(%)**	**Group 6 n=15(%)**
Passes with slight snap (ideal)	6 (40.0)	0 (0.0)	0 (0.0)	8 (53.3)	0 (0.0)	0 (0.0)
Passes with	8 (53.	11 (73.	3 (20.	7 (46.	2 (13.	3 (20.

pressure	3)	3)	0)	7)	3)	0)
Passes loosely	1 (6.7)	4 (26.7)	11 (73.3)	0 (0.0)	7 (46.7)	8 (53.3)
Floss shreds	0 (0.0)	0 (0.0)	1 (6.7)	0 (0.0)	6 (40.0)	4 (26.7)

Table no. 5: Floss evaluation among the six groups tested, n (%: Percentage)

Proximal contour: A normal contour was achieved in 93.3% of Group 4, 40.0% of Group 1 and 13.3% of Group 2 and in none of Group 3, 5 and 6. Visible contour deficiency was most common in Group 6 (80.0%) and 5 (66.7%) and they were also the only groups with grossly inadequate contours. The difference was statistically significant (P < 0.001) (Table no. 6 & Graph no. 3).

Proximal contour	**Group 1 n=15(%)**	**Group 2 n=15(%)**	**Group 3 n=15(%)**	**Group 4 n=15(%)**	**Group 5 n=15(%)**	**Group 6 n=15(%)**
Normal contour	6 (40.0)	2 (13.3)	0 (0.0)	14 (93.3)	0 (0.0)	0 (0.0)
Slightly over/ undercontoured	9 (60.0)	8 (53.3)	13 (86.7)	1 (6.7)	2 (13.3)	2 (13.3)
Visible contour deficiency	0 (0.0)	5 (33.3)	1 (6.7)	0 (0.0)	10 (66.7)	12 (80.0)
Grossly inadequate	0 (0.0)	0 (0.0)	0 (0.0)	0 (0.0)	3 (20.0)	1 (6.7)

Table no. 6: Proximal contour among the six groups tested, n (%: Percentage)

Radiographic analysis: Ideal radiographic contour and contact were seen most often in Group 4 (60.0%) and Group 2 (53.3%), and in none of Group 3, 5 and 6. All restorations in Group 3 were slightly compromised, while compromised contour or contact was seen mainly in Groups 5 (66.7%) and 6 (53.3%). No group showed an open contact or gross deficiency. The difference was statistically significant (P < 0.001) (Table no. 7).

Radiographic analysis	**Group 1 n=15(%)**	**Group 2 n=15(%)**	**Group 3 n=15(%)**	**Group 4 n=15(%)**	**Group 5 n=15(%)**	**Group 6 n=15(%)**
Ideal contour and contact	4 (26.7)	8 (53.3)	0 (0.0)	9 (60.0)	0 (0.0)	0 (0.0)
Slightly compromised	10 (66.7)	7 (46.7)	15 (100)	6 (40.0)	5 (33.3)	7 (46.7)
Compromised	1 (6.7)	0 (0.0)	0 (0.0)	0 (0.0)	10 (66.7)	8 (53.3)

Table no. 7: Radiographic analysis among the six groups tested, n (%: Percentage)

Radiographic marginal adaptation: Excellent cervical adaptation was seen in all restorations of Group 2 (100%), followed by Group 4 (93.3%) and Group 1 (73.3%). Radiographic overhangs were most frequent seen in Group 6 (93.3%) and 5 (86.7%). No underfilled margin was seen in any group tested. The difference was statistically significant (P < 0.001) (Table no. 8 & Graph no. 4).

Marginal adaptation	**Group 1 n=15(%)**	**Group 2 n=15(%)**	**Group 3 n=15(%)**	**Group 4 n=15(%)**	**Group 5 n=15(%)**	**Group 6 n=15(%)**
Excellent cervical adaptation	11 (73.3)	15 (100)	6 (40.0)	14 (93.3)	2 (13.3)	1 (6.7)
Radiographic overhang	4 (26.7)	0 (0.0)	9 (60.0)	1 (6.7)	13 (86.7)	14 (93.3)

Table no. 8: Radiographic marginal adaptation among the six groups tested, n (%: Percentage)

Overall restoration quality: Among the total 90 Dental composite restorations in patients; 21 restorations (23.3%) were rated as Excellent, 32 (35.6%) as Acceptable and 37 (41.1%) as Not acceptable. All restorations in Group 4 were Excellent, in Group 2 were Acceptable and in Groups 5 and 6 were Not acceptable. The difference among the groups was statistically significant (P < 0.001) (Table no. 9).

Quality of Dental Composite restoration	**Group 1 n=15(%)**	**Group 2 n=15(%)**	**Group 3 n=15(%)**	**Group 4 n=15(%)**	**Group 5 n=15(%)**	**Group 6 n=15(%)**
Rated as Excellent	6 (40.0)	0 (0.0)	0 (0.0)	15 (100)	0 (0.0)	0 (0.0)
Rated as Acceptable	9 (60.0)	15 (100)	8 (53.3)	0 (0.0)	0 (0.0)	0 (0.0)
Rated as Not acceptable	0 (0.0)	0 (0.0)	7 (46.7)	0 (0.0)	15 (100)	15 (100)

Table no. 9: Overall restoration quality among the six groups tested, n (%: Percentage)

Overall comparison of Dental Matrix band systems showed; Group 4 (Contoured sectional matrix with separation ring) consistently produced the most favourable clinical and radiographic outcomes, followed by Groups 1 and 2, while Group 3 showed a mixed profile. Groups 5 and 6 (automatrix systems) consistently produced the poorest proximal contact, contour and marginal adaptation.

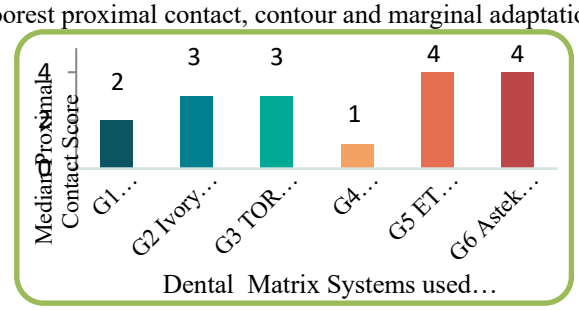

Graph no. 1: Bar Graph Showing Comparison of Median Proximal Contact Tightness Scores Among the Six Matrix Systems

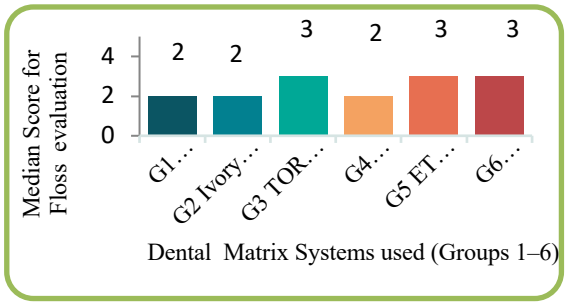

Graph no. 2: Bar Graph Showing Comparison of Median Floss Evaluation Scores Among the Six Matrix Systems

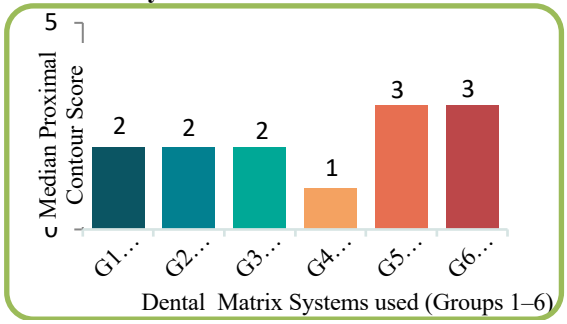

Graph no. 3: Bar Graph Showing Comparison of Median Proximal Contour Assessment Scores Among the Six Matrix Systems

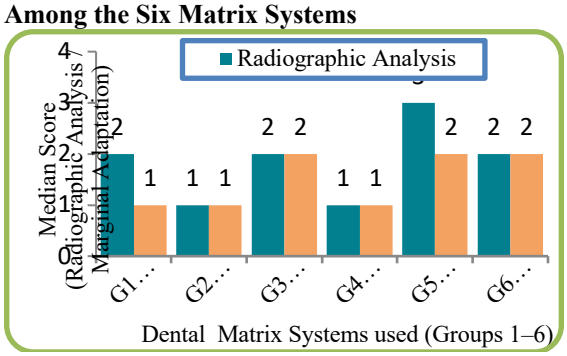

Graph no. 4: Comparative Bar Graph of Median Radiographic Contour and Marginal Adaptation Scores among the Six Matrix Systems

DISCUSSION:

The proximal contact and contour of a Class-II Dental composite restoration are among its most important features, because they protect the interdental papilla, prevent food impaction and preserve the integrity of the dental arch.[1,2,3] Dental Composite resin offers little internal resistance to the force applied by the matrix band, so the matrix system largely determines whether an ideal contact and contour can be achieved (or) not.[12]

In our In-vivo study, FDI criteria was used, as it is the most accepted standard for evaluating direct restorations and is more sensitive and precise than the modified USPHS (Ryge) criteria.[18,20] Floss assessment was supplemented with force measurement because, floss alone is subjective and is affected by the thickness of the floss and by moisture.[10] The use of a blinded evaluator and a single operator reduced observer and treatment technique variability.

In the present study, Group 4 achieved an ideal proximal contact in 86.7% of restorations, and 33.3% in the Tofflemire group and none in the other four groups. This agrees with randomised trials conducted by Wirsching E et al[6] and Loomans BA et al[11] showed that the use of sectional matrices with separation rings provided tighter contacts compared to circumferential systems. Tolba ZO et al[25] reported higher contact tightness with sectional matrix and separation ring. Our findings are also in accordance with another systematic review by Kamble S et al[26] which pooled six randomised trials and concluded that sectional matrices with separation rings produced significantly tighter and more consistent contacts than circumferential matrix systems. The separating force of the ring is thought to compensate for the thickness of the matrix band and for the polymerisation shrinkage of the composite and it has been reported to influence contact tightness more than the composite or the placement technique does.[11]

The Tofflemire (Group 1) and Ivory no. 1 (Group 2) matrice systems showed acceptable results but not ideal in Group 1; contacts were weak (66.7%) and in Group 2; contacts remained strong (73.3%). Comparable results were reported for circumferential matrice systems by Kampouropoulos D et al[27] The relatively flat form of circumferential bands has long been associated with inadequate contact and contour and poor adaptation to the adjacent tooth and a higher likelihood of restoration overhangs of these systems. Contacts that are too strong are equally undesirable, since they cause discomfort to the patient and cause damage to the interdental tissues.[6]

The portable electronic scale used in our In-vivo study provided a practical, quantitative and objective means of recording the maximum force required to withdraw the test strip through the proximal contacts of teeth, thereby enabling direct numerical comparison among the study groups. The use of force-based measurements to quantify proximal contact tightness is supported by Wirsching E et al[6] and Tolba ZO et al[25] investigations employing digital force analyzers, portable dental pressure meters and other force-measuring devices.[11] Such approaches provides measurable outcomes for evaluating the resistance encountered during strip withdrawal and facilitate standardized comparisons between the restorative techniques used. According to Southard TE et al[28] the absence of a statistically significant difference in our present study suggested that the tested matrix systems exhibited similar pull-through force values, supporting the potential to establish proximal contacts comparable in tightness to those produced by the conventional matrice system. Furthermore, according to Dorfer CE et al[29], when both the clinical and radiographic findings were assessed, the force measurements contributes to restorations proximal contact quality. Collectively, these findings support the utility of the portable electronic scale as a practical quantitative assessment tool.

The findings of our study showed that among the Proximal contours, the largest inter-group difference was seen; Ideal contour was recorded in 93.3% of Group 4 restorations, compared to 40.0% in Group 1 and 13.3% in Group 2. A pre-contoured sectional band reproduces proximal convexity, whereas flat circumferential bands tend to leave a flat or under-contoured surface unless they are contoured beforehand.[13] Distortion of the thin band at its most bulbous point, and concave contours, as reported by Bailey O et al.[30] Kampouropoulos D et

al[27] also observed over-contouring with sectional matrices. Tolba ZO et al[25] found that both sectional and circumferential systems showed some contour deficiency, this explains how 86.7% in Group 3 restorations were over-contoured or under-contoured despite the use of a sectional band with a ring.

In our present study, in Group 3 (Torr VM) Contacts were rated strong in 93.3% of restorations, yet floss passed loosely in 73.3% and radiographic overhangs were seen in 60.0%. A tight contact and a loose floss pass can coexist if the contact is narrow or poorly shaped, because floss resistance depends on the breadth and morphology of the contact area as well as on its tightness, as a band with limited pre-contouring combined with ring tension produced poor contact. Our study findings are not in agreement with the studies of Shaalan OO and Ibrahim SH[31], Abdelaziz et al,[32] reported Torr VM system exhibited optimum contact and contour, compared to circumferential matrice system. The findings of our study showed that sectional matrix design with separation ring does not by itself guarantee an ideal contact and contour of restorations.

Our study showed, both the automatrix systems (Groups 5 and 6) performed worst. Contacts were too weak in 73.3% and 66.7% of restorations, visible contour deficiency was observed in 66.7% and 80.0% and radiographic overhangs in 86.7% and 93.3% respectively. Our findings are in accordance with Cenci MS et al[12] reported that retainer-less, self-forming bands lack a true tooth separation mechanism and therefore show the least predictable proximal anatomy of restoration. Without a ring, when a thin matrix band is drawn inward around the tooth, it adapts poorly at the cervical margin and leave excess restorative material at the gingival wall. Because overhangs and under-contoured proximal restoration surfaces promote plaque retention, food impaction and periodontal inflammation.[2,3,4,5]

In our In-vivo study, in Group 2 composite restorations showed the excellent cervical adaptation (100%), followed by Group 4 (93.3%) and Group 1 (73.3%), probably because of firm adaptation of the matrix band at the gingival margin and the presence of overhangs restoration is linked to the placement technique of separation rings.[33] When all parameters (evaluation of Proximal contact using Dental floss, proximal contact using Metal blade, Radiographic proximal contour, Radiographic marginal adaptation) were assessed together, every composite restoration in Group 4 was rated as excellent and every restoration in Group; 5 and 6 were rated, acceptable. In our In-vivo study, all composite restorations were done by one clinician using the same restorative material and treatment protocol. So, the differences observed in our findings among the six groups are more likely attributable to the six different dental matrix systems used and not the clinician's skill alone. So the type of matrix systems used plays a decisive role in the success of Class-II composite restorations in clinical dental practice. Clinicians treatment competence, experience and technique sensitivity of individual dental matrix systems remains important factors to be considered.[26] The findings of our In-vivo study are in accordance with an another In-vivo study by Sankhyan V et al[33] reported sectional matrix systems showed significantly better contacts than the Tofflemire matrix systems and also concluded that no matrix systems recreated all the characteristic features of an ideal contact.

The comprehensive comparison among six different dental matrix system used in our In-vivo study provides clinical evidence to guide clinicians in selecting the most effective dental matrix system for achieving optimal proximal contact tightness and anatomically correct contour morphology of restored teeth in restorative dentistry.

CONCLUSION:

Within the limitations of our In-vivo study, the type of matrix system used during Class-II composite restorations significantly influenced its proximal contact tightness, proximal contour and marginal adaptation. The sectional contoured Dental matrix system showed the most favourable and rated as Excellent for proximal contact and contours among the six matrix systems tested, the circumferential matrix systems performed moderately. The Tofflemire matrix system exhibited weak contacts, whereas the Ivory matrix system exhibited strong contacts with the best cervical adaptation. The Torr VM sectional matrix system showed proximal radiographic restoration overhangs. The ET and Astek automatrix system showed the poor contact, contour and marginal adaptability with all of their composite restorations were rated as not acceptable.

From a clinical perspective, the findings of our In-vivo study suggest that selecting a Dental matrix system based on its ability to reproduce anatomical contact and contour is essential for protecting periodontal health and also mainly for longevity of Class-II Dental composite restorations. So, a Sectional contoured dental matrix system is recommended to obtain ideal proximal contact, contour and marginal adaptation of composite restorations. Whereas, the automatrix systems remains unsuitable. Further long-term follow-up,

multi-centre clinical trials with larger sample size are warranted to correlate the findings of our In-vivo study.

Conflict of Interest: Nil
Source of Funding: Nil

REFERENCES :

1. Ash MM. Wheeler's Dental anatomy, Physiology and Occlusion. 8th ed. St. Louis, MO: Elsevier; 2003. p. 121-129.
2. Hancock EB, Mayo CV, Schwab RR, Wirthlin MR. Influence of interdental contacts on periodontal status. J Periodontol. 1980;51:8:445-449.
3. Jernberg GR, Bakdash MB, Keenan KM. Relationship between proximal tooth open contacts and periodontal disease. J Periodontol. 1983;54:9:529-533.
4. Saber MH, Loomans BA, El Zohairy A, Dorfer CE, El-Badrawy W. Evaluation of proximal contact tightness of Class II resin composite restorations. Oper Dent. 2010;35:1:37-43.
5. Loomans BA, Opdam NJ, Roeters JF, Bronkhorst EM, Plasschaert AJ. Influence of composite resin consistency and placement technique on proximal contact tightness of class II restorations. J Adhes Dent. 2006;8:305-310.
6. Wirsching E, Loomans BA, Klaiber B, Dorfer CE. Influence of matrix systems on proximal contact tightness of 2- and 3-surface posterior composite restorations in vivo. J Dent. 2011;39:5:386-390.
7. Loomans BA, Roeters FJ, Opdam NJ, Kuijs RH. The effect of proximal contour on marginal ridge fracture of Class II composite resin restorations. J Dent. 2008;36:10:828-832.
8. Shivakumar AT, Kalgeri SH, Dhir S. Clinical considerations in restorative dentistry – a narrative review. J Int Clin Dent Res Organ. 2015;7:2:122-129.
9. Chuang SF, Su KC, Wang CH, Chang CH. Morphological analysis of proximal contacts in class II direct restorations with 3D image reconstruction. J Dent. 2011;39:6:448-456.
10. Keogh TP, Bertolotti RL. Creating tight, anatomically correct interproximal contacts. Dent Clin North Am. 2001;45:83-102.
11. Loomans BA, Opdam NJ, Roeters FJ, Bronkhorst EM, Burgersdijk RC, Dorfer CE. A randomized clinical trial on proximal contacts of posterior composites. J Dent. 2006;34:4:292-297.
12. Cenci MS, Lund RG, Pereira CL, de Carvalho RM, Demarco FF. In vivo and in vitro evaluation of class II composite resin restorations with different matrix systems. J Adhes Dent. 2006;8:2:127-132.
13. Ramya R, Raghu S. Optimizing tooth form with direct posterior composite restorations. J Conserv Dent. 2011;14:4:330-336.
14. Cerdan F, Ceballos L, Fuentes MV. Quality of approximal surfaces of posterior restorations in primary molars. J Oral Sci. 2021;63:347-351.
15. Casagrande L, Dalpian DM, Ardenghi TM, Zanatta FB, Balbinot CE, Garcia-Godoy F, De Araujo FB. Randomized clinical trial of adhesive restorations in primary molars. 18-month results. Am J Dent. 2013;26:6:351-355.
16. Khan FR, Umer F, Rahman M. Comparison of proximal contact and contours of premolars restored with composite restoration using circumferential matrix band with and without separation ring: a randomized clinical trial. Int J Prosthodont Restor Dent. 2013;3:1:7-13.
17. Loomans BA, Opdam NJ, Roeters FJ, Bronkhorst EM, Plasschaert AJ. The long-term effect of a composite resin restoration on proximal contact tightness. J Dent. 2007;35:104-108.
18. Hickel R, Peschke A, Tyas M, Mjor I, Bayne S, Peters M, et al. FDI World Dental Federation: clinical criteria for the evaluation of direct and indirect restorations – update and clinical examples. Clin Oral Investig. 2010;14:349-366.
19. Paula EA, Tay LY, Kose C, Mena-Serrano A, Reis A, Perdiao J, et al. Randomized clinical trial of four adhesion strategies in cervical lesions: 12-month results. Int J Esthet Dent. 2015;10:122-145.
20. Cvar JF, Ryge G. Reprint of criteria for the clinical evaluation of dental restorative materials. 1971. Clin Oral Investig. 2005;9:215-232.
21. Mesinger S, Heck K, Crispin A, Frankenberger R, Cadenaro M, Burgess J, et al. Evaluation of direct restorations using the revised FDI criteria: results from a reliability study. Clin Oral Investig. 2023;27:4:1519-1528.
22. Volety S, Rao AS, Kishan KV, Shah NC, Solanki D, Jain G. Comparison of proximal contact tightness and contour of bioclear biofit HD versus Composi-tight 3DXR matrix systems in Class-II composite restoration: a randomized clinical study. J Oral Biol Craniofac Res. 2025;15:4:696-702.

23. Noorudeen AA, Shetty SV, Harikrishnan N, Mariyam N. Effects of two sectional matrix systems on proximal contact tightness and mesiodistal dimension in class II composite restorations: an in vitro study. Front Dent Med. 2026;7:1932605.
24. World Medical Association. Declaration of Helsinki: recommendations guiding doctors in clinical research - 1964 version [Internet]. Ferney-Voltaire (France): World Medical Association; 1964.
25. Tolba ZO, Oraby E, Abd El Aziz PM. Impact of matrix systems on proximal contact tightness and surface geometry in class II direct composite restoration in-vitro. BMC Oral Health. 2023;1:23-29
26. Kamble S, Ramugade M, Sayed A, Sapkale K, Gulhane A, Magar A. The effectiveness of circumferential and sectional matrix systems in obtaining optimum proximal contact in class II composite restorations: a systematic review. Cureus. 2025;17:5:e84967.
27. Kampouropoulos D, Paximada C, Loukidis M, Kakaboura A. The influence of matrix type on the proximal contact in Class II resin composite restorations. Oper Dent. 2010;35:4:454-462.
28. Dorfer CE, Von Bethlenfalvy ER, Staehle HJ, Pioch T. Factors influencing proximal dental contact strengths. Eur J Oral Sci. 2000;108:5:368-377.
29. Southard TE, Southard KA, Tolley EA. Variation of approximal tooth contact tightness with postural change. J Dent Res. 1990;69:1776-1779.
30. Bailey O. Sectional matrix solutions: The distorted truth. Br Dent J. 2021;231:547-555.
31. Shaalan OO, Ibrahim SH. Clinical evaluation of sectional matrix versus circumferential matrix for reproduction of proximal contact by undergraduate students and postgraduate dentists: a randomized controlled trial. J Int Oral Health. 2021;13:10-16.
32. Abdelaziz M, Fahim S, Abdelwahed A. Clinical and radiographic evaluation of sectional versus circumferential matrix systems: a one-year randomized clinical trial. Egypt Dent J. 2024;70:2:1923-1934.
33. Sankhyan V, Makkar S, Negi S, Gupta S, Jain A, Arora G. Comparison of proximal contact and contours of class II restoration in premolars and molars restored with three different matrix systems using FDI criteria: an in vivo study. J Conserv Dent Endod. 2024;27:913-919.