RESEARCH PAPER

Diagnostic accuracy of single-voxel proton magnetic resonance spectroscopy versus conventional magnetic resonance imaging for malignant brain lesions, with histopathology as the reference standard: a cross-sectional study

[1]Dr Shehzad Karim Bhatti, [2]Dr. Huma Iqbal, [3]Dr. Amnah Hanif, [4]Noor Shahzad, [5]Dr. Ahshum AbuBaker, [6]Eman Sehar, [7]Sana Zaheer Qureshi*

Author Details:

[1]MBBS, FCPS radiology, Associate Professor of Radiology, Department of Diagnostic Radiology & Medical Imaging,Mayo Hospital / King Edward Medical University, Lahore.

[2] MBBS, FCPS Radiology, Senior Registrar, Department of Diagnostic Radiology & Medical Imaging, Mayo Hospital, Lahore

[3] MBBS, FCPS Radiology, Department of Radiology, Jinnah Hospital, Lahore .

[4] BS Honors Computer Sciences, PGD Public Health, Health Services Academy, Islamabad.

[5] MBBS, Shalamar Medical and Dental College, Lahore .

[6] B.Sc. Honors MIT, M.Phil. Allied Health Sciences (Radiology), Saleem Memorial Hospital, Lahore

[7]B.Sc. Medical Imaging Technology, MPA, M.Phil. ELPS, Lecturer in Medical Imaging Technology, Department of Diagnostic Radiology & Medical Imaging, Mayo Hospital / King Edward Medical University , Lahore,

Corresponding Author: Sana Zaheer Qureshi, Email: sanazaheerqureshi@kemu.edu.pk

ABSTRACT

Background: Conventional magnetic resonance imaging (MRI) cannot always separate malignant from non-malignant intracranial lesions, and histopathological confirmation requires an invasive procedure.

Objective: To compare the diagnostic accuracy of single-voxel proton magnetic resonance spectroscopy (^{1}H-MRS) with that of conventional MRI for malignant brain lesions, using histopathology as the reference standard.

Methods: This cross-sectional diagnostic accuracy study was conducted in the Department of Diagnostic Radiology, Shaikh Zayed Hospital, Lahore, Pakistan. One hundred and fifty consecutive adults (20–65 years) with a suspected brain tumour measuring at least 1.5 cm underwent conventional and contrast-enhanced MRI followed by single-voxel point-resolved spectroscopy (echo time 135 ms; repetition time 1500 ms) at 1.5 T. A spectrum was considered positive for malignancy when the choline/creatine ratio exceeded 1.5 and the N-acetylaspartate/choline ratio was below 1.2. Sensitivity, specificity, predictive values and accuracy were calculated with Wilson 95% confidence intervals (CIs).

Results: Participants comprised 85 men (56.7%) and 65 women (43.3%); histopathology confirmed malignancy in 100 (66.7%). Conventional MRI had a sensitivity of 74.0% (95% CI 64.6–81.6), specificity of 82.0% (69.2–90.2) and accuracy of 76.7% (69.3–82.7). ^{1}H-MRS had a sensitivity of 89.0% (81.4–93.7), specificity of 96.0% (86.5–98.9), positive predictive value of 97.8% (92.3–99.4), negative predictive value of 81.4% (69.6–89.3) and accuracy of 91.3% (85.7–94.9). False-positive results fell from 9 to 2 and false-negative results from 26 to 11.

Conclusion: Single-voxel ^{1}H-MRS identified malignant brain lesions more accurately than conventional MRI. It is a useful non-invasive adjunct to routine MRI, but it does not replace histopathological and molecular diagnosis.

Keywords: Brain Neoplasms; Magnetic Resonance Spectroscopy; Magnetic Resonance Imaging; Choline; Sensitivity and Specificity; Histology

HOW TO CITE THIS ARTICLE: 1DR SHEHZAD KARIM BHATTI 2DR. HUMA IQBAL 3DR. AMNAH HANIF 4NOOR SHAHZAD 5DR. AHSHUM ABUBAKER 6EMAN SEHAR 7SANA ZAHEER QURESHI*. DIAGNOSTIC ACCURACY OF SINGLE-VOXEL PROTON MAGNETIC RESONANCE SPECTROSCOPY VERSUS CONVENTIONAL MAGNETIC RESONANCE IMAGING FOR MALIGNANT BRAIN LESIONS, WITH HISTOPATHOLOGY AS THE REFERENCE STANDARD: A CROSS-SECTIONAL STUDY. INT J DRUG DELIV TECHNOL. 2026;16(90S):553-559. DOI: 10.25258/IJDDT.16.90S.52.

INTRODUCTION

Intracranial neoplasms comprise primary tumours of the brain and its coverings as well as metastases from extracranial primaries, and together they account for considerable morbidity and mortality across all age groups [1]. Accurate preoperative characterisation matters because the

distinction between a malignant tumour and a benign or non-neoplastic lesion determines whether a patient proceeds to resection, stereotactic biopsy, medical treatment or imaging surveillance. The 2021 World Health Organization (WHO) classification has further shifted definitive diagnosis towards an integrated histological and molecular assessment, which can only be made on tissue [2].

Conventional and contrast-enhanced MRI is the first-line modality for suspected brain tumours, but it depicts anatomy, signal change and blood–brain barrier disruption rather than tissue biochemistry [3,4]. Abscesses, tuberculomas, subacute infarcts, tumefactive demyelination and resolving haematomas can enhance, cause oedema and mass effect, and so mimic high-grade neoplasms, whereas some malignant tumours enhance little or not at all [3,5]. As a result, a proportion of lesions remain indeterminate after conventional imaging and patients may undergo invasive sampling that, in retrospect, was not required.

Proton magnetic resonance spectroscopy (^{1}H-MRS) adds metabolic information to the same examination. After suppression of the water signal, the spectrum displays resonances from N-acetylaspartate (NAA, approximately 2.0 ppm), a marker of neuronal integrity; creatine (Cr, approximately 3.0 ppm), which reflects cellular energy metabolism and is commonly used as an internal reference; and choline-containing compounds (Cho, approximately 3.2 ppm), which rise with membrane turnover and cellular proliferation [3,4]. Lactate (1.33 ppm) and mobile lipids (0.9–1.3 ppm) indicate anaerobic metabolism and necrosis. Malignant tumours typically show raised Cho with reduced NAA, so metabolite ratios such as Cho/Cr and NAA/Cho can help distinguish neoplastic from non-neoplastic tissue [5,6].

Published series indicate that adding ^{1}H-MRS to MRI increases the number of correct diagnoses and reduces equivocal reports [6], but a systematic review concluded that the evidence base is heterogeneous, frequently lacks blinded interpretation and needs further high-quality studies [7]. Data from South Asian centres, where access to advanced techniques such as perfusion imaging and positron emission tomography is limited and where infective mass lesions are common, remain scarce [8]. This study therefore compared the diagnostic accuracy of single-voxel ^{1}H-MRS with that of conventional MRI for malignant brain lesions in adults, using histopathology as the reference standard.

METHODS

Study design and setting

This cross-sectional comparative diagnostic accuracy study was conducted in the Department of Diagnostic Radiology, Shaikh Zayed Hospital (Postgraduate Medical Institute), Lahore, Pakistan, over 12 months following approval of the study protocol. The study is reported in accordance with the STARD 2015 guideline [9].

Participants

Consecutive patients referred from the neurology and neurosurgery outpatient clinics, inpatient wards and emergency department were screened using non-probability consecutive sampling. Patients of either sex aged 20–65 years were eligible if a brain tumour was suspected on the basis of clinical findings and prior computed tomography (CT) or MRI, and the lesion measured at least 1.5 cm in its greatest axial dimension. Exclusion criteria were contraindications to MRI (cardiac pacemaker, metallic stents, prosthetic heart valves, cochlear implants, intracranial aneurysm clips or coils), previous brain surgery, recurrent tumour, involuntary movements precluding a diagnostic examination, and a life expectancy of less than 3 months. Demographic and clinical data were recorded on a structured proforma.

Index test 1: conventional MRI

All examinations were performed on a 1.5 T scanner (GE Healthcare) using a head coil. The protocol comprised axial T1-weighted, T2-weighted and fluid-attenuated inversion recovery (FLAIR) images, sagittal T2-weighted images and coronal FLAIR images, followed by gadolinium-enhanced T1-weighted images in the axial, coronal and sagittal planes (Table 2). Each lesion was classified as positive or negative for malignancy on the basis of its signal characteristics, enhancement pattern, necrosis, perilesional oedema and mass effect.

Index test 2: single-voxel ^{1}H-MRS

^{1}H-MRS was acquired in the same session after conventional imaging, using a single-voxel point-resolved spectroscopy (PRESS) sequence with water suppression, an echo time (TE) of 135 ms and a repetition time (TR) of 1500 ms. The voxel was placed over the enhancing solid component of the lesion and positioned away from necrotic, haemorrhagic, calcified and cystic areas, cerebrospinal fluid, bone and air to minimise partial-volume and susceptibility effects [10]. Peak heights of NAA, Cr and Cho and the presence of lactate and lipid peaks were recorded, and Cho/Cr, NAA/Cho and NAA/Cr ratios were calculated with the vendor software. A lesion was classified as positive for malignancy when the Cho/Cr ratio exceeded 1.5 and the NAA/Cho ratio was below 1.2 (reference values in normal parenchyma approximately 1.2 and 1.6, respectively). These thresholds were defined before the study began and are consistent with ratio-based criteria reported previously [5,6,11].

Conventional MRI and ^{1}H-MRS were interpreted by consultant radiologists experienced in neuro-MRS. All imaging was performed and

reported before surgery, so readers were unaware of the histopathological result.

Table 2. Imaging protocol and spectroscopic criteria for malignancy

Parameter	Specification
Scanner and coil	1.5 T MRI system (GE Healthcare); head coil
Conventional sequences	Axial T1W, T2W and FLAIR; sagittal T2W; coronal FLAIR
Post-contrast sequences	Gadolinium-enhanced T1W in axial, coronal and sagittal planes
Spectroscopy technique	Single-voxel PRESS with water suppression
TE / TR	135 ms / 1500 ms
Voxel placement	Enhancing solid component; avoiding necrosis, haemorrhage, calcification, cyst, CSF, bone and air
Metabolites assessed	NAA (2.0 ppm), Cr (3.0 ppm), Cho (3.2 ppm), lactate (1.33 ppm), lipids (0.9–1.3 ppm)
Criteria for malignancy	Cho/Cr > 1.5 and NAA/Cho < 1.2 (normal approximately 1.2 and 1.6, respectively)

Cho, choline-containing compounds; Cr, creatine; CSF, cerebrospinal fluid; FLAIR, fluid-attenuated inversion recovery; NAA, N-acetylaspartate; ppm, parts per million; PRESS, point-resolved spectroscopy; T1W/T2W, T1-/T2-weighted; TE, echo time; TR, repetition time.

Reference standard

The reference standard was histopathological examination of tissue obtained at surgical resection or stereotactic biopsy, reported by consultant histopathologists. Each case was classified as positive or negative for malignancy, and the imaging classifications were then cross-tabulated against the histopathological result.

Sample size

A sample of 150 participants was planned on the basis of an expected diagnostic accuracy of 88.7% for ^{1}H-MRS, a 95% confidence level and an absolute precision of approximately 5%; with 150 participants the achieved precision is ±5.1%.

Statistical analysis

Data were analysed with SPSS version 23.0 (IBM Corp., Armonk, NY, USA). Categorical variables are presented as frequencies and percentages. For each index test, true-positive, false-positive, false-negative and true-negative results were derived from 2 × 2 tables against histopathology, and sensitivity, specificity, positive predictive value (PPV), negative predictive value (NPV) and overall accuracy were calculated using standard definitions [12]. Ninety-five per cent confidence intervals (CIs) for proportions were calculated with the Wilson score method [13]. Positive and negative likelihood ratios (LR+ and LR−) and the diagnostic odds ratio (DOR) were calculated with log-transformed 95% CIs. Because MRS and MRI results were cross-classified only against the reference standard and not against each other at the individual-patient level, differences between the two tests are reported as point estimates with their 95% CIs rather than with a paired significance test.

Ethical considerations

The study protocol was approved by the Institutional Review Board of the Postgraduate Medical Institute/Shaikh Zayed Hospital, Lahore. Written informed consent was obtained from all participants, and the study was conducted in accordance with the Declaration of Helsinki.

RESULTS

Participants

One hundred and fifty patients were enrolled and all completed conventional MRI, ^{1}H-MRS and histopathological examination; no index test result was indeterminate and no participant was excluded after enrolment (Figure 1). There were 85 men (56.7%) and 65 women (43.3%). Thirty-three participants (22.0%) were aged 20–35 years, 40 (26.7%) were aged 36–50 years and 77 (51.3%) were aged 51–65 years (Table 1). Histopathology confirmed malignancy in 100 participants (66.7%; 95% CI 58.8–73.7) and excluded it in 50 (33.3%).

Table 1. Characteristics of the study participants (n = 150)

Characteristic	n	%
Sex		
Male	85	56.7
Female	65	43.3
Age group		
20–35 years	33	22.0
36–50 years	40	26.7
51–65 years	77	51.3
Positive for malignancy		
Conventional MRI	83	55.3
^{1}H-MRS	91	60.7
Histopathology (reference standard)	100	66.7

MRI, magnetic resonance imaging; ^{1}H-MRS, proton magnetic resonance spectroscopy.

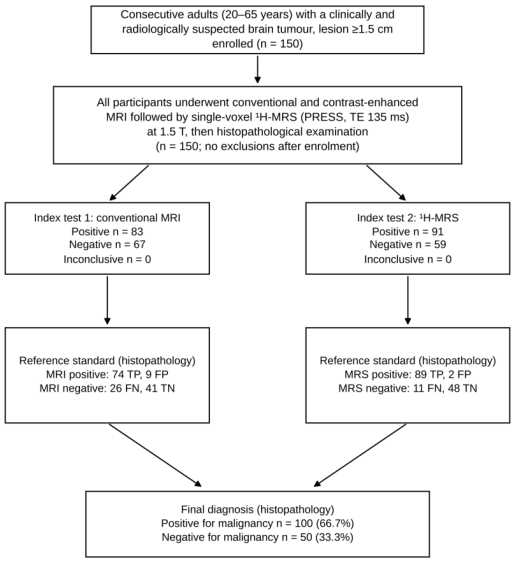

Figure 1. STARD flow diagram of participants through the study. All 150 enrolled participants underwent both index tests and the reference standard. MRS, magnetic resonance spectroscopy; PRESS, point-resolved spectroscopy; TE, echo time; TP, true positive; FP, false positive; FN, false negative; TN, true negative.

Diagnostic performance of conventional MRI

Conventional MRI was positive in 83 participants (55.3%) and correctly identified 74 of the 100 malignant lesions, with 9 false-positive and 26 false-negative results (Table 3). Sensitivity was 74.0% (95% CI 64.6–81.6), specificity 82.0% (69.2–90.2), PPV 89.2% (80.7–94.2), NPV 61.2% (49.2–72.0) and overall accuracy 76.7% (69.3–82.7) (Table 4).

Diagnostic performance of ^{1}H-MRS

^{1}H-MRS was positive in 91 participants (60.7%) and correctly identified 89 of the 100 malignant lesions, with 2 false-positive and 11 false-negative results (Table 3). Sensitivity was 89.0% (95% CI 81.4–93.7), specificity 96.0% (86.5–98.9), PPV 97.8% (92.3–99.4), NPV 81.4% (69.6–89.3) and overall accuracy 91.3% (85.7–94.9). The LR+ was 22.3 (5.7–86.7) for ^{1}H-MRS compared with 4.1 (2.3–7.5) for conventional MRI, and the LR− was 0.11 (0.07–0.20) compared with 0.32 (0.22–0.45) (Table 4).

Table 3. Cross-tabulation of conventional MRI and ^{1}H-MRS results against histopathology (n = 150)

Index test result	Histopathology positive	Histopathology negative	Total
Conventional MRI			
Positive	74 (TP)	9 (FP)	83
Negative	26 (FN)	41 (TN)	67
^{1}H-MRS			
Positive	89 (TP)	2 (FP)	91
Negative	11 (FN)	48 (TN)	59
Total (reference standard)	**100**	**50**	**150**

FN, false negative; FP, false positive; TN, true negative; TP, true positive.

Table 4. Diagnostic performance of conventional MRI and ^{1}H-MRS for malignant brain lesions, with histopathology as the reference standard

Measure	Conventional MRI	^{1}H-MRS
Sensitivity, % (95% CI)	74.0 (64.6–81.6)	89.0 (81.4–93.7)
Specificity, % (95% CI)	82.0 (69.2–90.2)	96.0 (86.5–98.9)
PPV, % (95% CI)	89.2 (80.7–94.2)	97.8 (92.3–99.4)
NPV, % (95% CI)	61.2 (49.2–72.0)	81.4 (69.6–89.3)
Accuracy, % (95% CI)	76.7 (69.3–82.7)	91.3 (85.7–94.9)
LR+ (95% CI)	4.1 (2.3–7.5)	22.3 (5.7–86.7)
LR− (95% CI)	0.32 (0.22–0.45)	0.11 (0.07–0.20)
DOR (95% CI)	13.0 (5.6–30.3)	194.2 (41.3–912.2)

Prevalence of malignancy on histopathology was 66.7% (100/150). Confidence intervals for proportions were calculated with the Wilson score method and those for likelihood ratios and diagnostic odds ratios with the log method. CI, confidence interval; DOR, diagnostic odds ratio; LR+/LR−, positive/negative likelihood ratio; NPV, negative predictive value; PPV, positive predictive value.

Compared with conventional MRI, ^{1}H-MRS increased sensitivity by 15.0 percentage points and

specificity by 14.0 percentage points, and reduced the total number of misclassified lesions from 35 to 13. The 95% CIs for overall accuracy did not overlap (Figure 2).

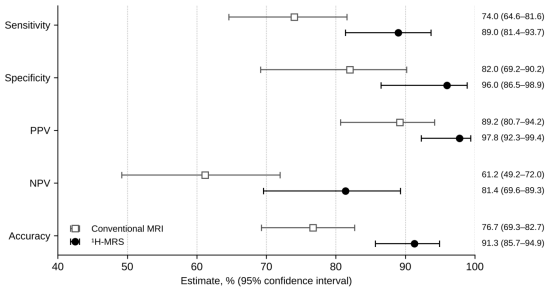

Figure 2. Sensitivity, specificity, positive predictive value (PPV), negative predictive value (NPV) and overall accuracy of conventional MRI (open squares) and ^{1}H-MRS (filled circles), with Wilson 95% confidence intervals. Numerical values are shown on the right.

DISCUSSION

In this cohort of 150 adults with suspected brain tumours, single-voxel ^{1}H-MRS identified malignant lesions more accurately than conventional MRI, with higher sensitivity, specificity and predictive values. The improvement was most marked for specificity and PPV: only 2 of 91 lesions classified as malignant on spectroscopy were benign or non-neoplastic on histopathology, compared with 9 of 83 on conventional MRI. Spectroscopy also reduced false-negative classifications by more than half, which was reflected in an NPV of 81.4% compared with 61.2% for MRI alone.

These findings are consistent with previous reports. In a series of 164 evaluable intracranial mass lesions, adding single-voxel ^{1}H-MRS to routine MRI increased correct diagnoses by 15.4% and reduced equivocal diagnoses by 16% [6]. A systematic review identified a large study in which accuracy for indeterminate lesions rose from 55% with MRI alone to 71% when spectroscopy was added, although the authors noted that many studies did not report blinded interpretation [7]. Hourani et al. reported a sensitivity of 72.2% and a specificity of 91.7% when combined spectroscopic and perfusion thresholds were used to separate tumours from non-neoplastic lesions [5], and Alam et al. described the value of MRS in characterising focal brain lesions in a Pakistani tertiary-care setting [8]. The higher sensitivity in the present study may partly reflect the inclusion of lesions of at least 1.5 cm, which allow placement of a voxel within solid enhancing tissue, and a cohort with a high prevalence of malignancy.

The biochemical basis of these results is well established. Elevated Cho reflects increased membrane synthesis and turnover in proliferating tumour cells, whereas reduced NAA reflects the replacement or destruction of normal neurons; normalising both to Cr, which is relatively stable in normal parenchyma, yields ratios that are less sensitive to coil loading and scanner variation than absolute peak heights [3,4]. Tumour types also show characteristic spectral patterns, such as near-absent NAA and alanine in meningioma and prominent lipids in metastases and lymphoma, which can support categorisation beyond a binary malignant or non-malignant decision [14,15]. Myo-inositol, which is best seen at short TE, helps to separate low-grade astrocytomas from higher-grade tumours [16].

The high specificity observed here is clinically relevant because the principal non-neoplastic mimics in this region are infective and inflammatory. Pyogenic abscesses show amino acid, acetate and succinate resonances that are absent from necrotic tumours [17], and spectroscopy can help distinguish primary central nervous system lymphoma from tumefactive demyelination [18]. Further refinements include sampling the peritumoral region to separate glioblastoma from solitary metastasis [19] and combining spectroscopy with diffusion or perfusion imaging for glioma grading [11,20]. A meta-analysis has confirmed moderate-to-high accuracy of MRS metabolite ratios for distinguishing high-grade from low-grade gliomas [21].

In practice, a high PPV and LR+ mean that a spectrum meeting the malignancy criteria substantially raises the probability of malignancy and can support decisions on surgical planning and biopsy targeting. Spectroscopic findings have been shown to alter treatment decisions for focal brain lesions [22] and, when combined with expert neuroradiological review, to provide diagnoses of glioblastoma reliable enough to limit invasive intervention in selected patients [23,24]. However, under the 2021 WHO classification definitive diagnosis depends on histological and molecular features [2]. ^{1}H-MRS should therefore be regarded as an adjunct that refines pretest probability and guides tissue sampling, not as a substitute for histopathology. Spectroscopic detection of 2-hydroxyglutarate in isocitrate dehydrogenase-mutant gliomas suggests that MRS may eventually provide non-invasive molecular information [25].

Strengths and limitations

The strengths of this study include consecutive enrolment, a standardised acquisition protocol, prespecified positivity criteria and verification of every participant by histopathology, which avoids partial verification bias. Several limitations should be considered. First, this was a single-centre study at 1.5 T with a single-voxel technique at an intermediate TE of 135 ms, so metabolites best detected at short TE, such as myo-inositol and lipids, were not fully exploited, and heterogeneous lesions may have been incompletely sampled. Second, the cohort was restricted to patients with suspected tumours of at least 1.5 cm

and had a high prevalence of malignancy (66.7%), which may limit applicability to smaller lesions and to settings with a lower pretest probability; predictive values in particular depend on prevalence. Third, it was not documented whether readers of the spectra were blinded to the conventional MRI findings, and both tests were reported by the same team, which may have introduced review bias. Fourth, individual-level cross-classification of MRI against MRS results was not available, which precluded a paired comparison such as McNemar's test. Fifth, the histological subtypes of malignant and non-malignant lesions were not analysed separately, so performance could not be reported for individual tumour types or for specific non-neoplastic mimics. Finally, the fixed ratio thresholds were not optimised with receiver operating characteristic analysis, and quantitative spectral quality criteria were not recorded.

CONCLUSION

Single-voxel ^{1}H-MRS performed at the time of routine MRI identified malignant brain lesions more accurately than conventional MRI alone, with notably higher specificity and positive predictive value. It is a feasible, non-invasive adjunct that can improve preoperative characterisation and guide biopsy, but histopathological and molecular diagnosis remains the definitive standard. Multicentre studies with blinded interpretation, short-TE and multivoxel techniques, and analysis by lesion subtype are needed to confirm these findings.

DECLARATIONS

Ethics approval and consent to participate: Approved by the Institutional Review Board of the Postgraduate Medical Institute/Shaikh Zayed Hospital, Lahore. Written informed consent was obtained from all participants.

Consent for publication: Not applicable; no identifiable patient data or images are included.

Conflicts of interest: The authors declare that they have no conflicts of interest. All authors have completed the ICMJE disclosure form.

Funding: This research received no specific grant from any funding agency in the public, commercial or not-for-profit sectors.

Data availability: The data that support the findings of this study are available from the corresponding author on reasonable request.

Use of artificial intelligence: An AI-assisted tool Claude AI was used for data representation and formatting of the manuscript. The authors reviewed and verified all content and take full responsibility for the work.

REFERENCES

1. Ostrom QT, Barnholtz-Sloan JS. Current state of our knowledge on brain tumor epidemiology. Curr Neurol Neurosci Rep. 2011;11(3):329-35.
2. Louis DN, Perry A, Wesseling P, et al. The 2021 WHO Classification of Tumors of the Central Nervous System: a summary. Neuro Oncol. 2021;23(8):1231-51.
3. Horská A, Barker PB. Imaging of brain tumors: MR spectroscopy and metabolic imaging. Neuroimaging Clin N Am. 2010;20(3):293-310.
4. Öz G, Alger JR, Barker PB, et al. Clinical proton MR spectroscopy in central nervous system disorders. Radiology. 2014;270(3):658-79.
5. Hourani R, Brant LJ, Rizk T, Weingart JD, Barker PB, Horská A. Can proton MR spectroscopic and perfusion imaging differentiate between neoplastic and nonneoplastic brain lesions in adults? AJNR Am J Neuroradiol. 2008;29(2):366-72.
6. Möller-Hartmann W, Herminghaus S, Krings T, et al. Clinical application of proton magnetic resonance spectroscopy in the diagnosis of intracranial mass lesions. Neuroradiology. 2002;44(5):371-81.
7. Hollingworth W, Medina LS, Lenkinski RE, et al. A systematic literature review of magnetic resonance spectroscopy for the characterization of brain tumors. AJNR Am J Neuroradiol. 2006;27(7):1404-11.
8. Alam MS, Sajjad Z, Hafeez S, Akhter W. Magnetic resonance spectroscopy in focal brain lesions. J Pak Med Assoc. 2011;61(6):540-3.
9. Bossuyt PM, Reitsma JB, Bruns DE, et al. STARD 2015: an updated list of essential items for reporting diagnostic accuracy studies. BMJ. 2015;351:h5527.
10. Callot V, Galanaud D, Le Fur Y, Confort-Gouny S, Ranjeva JP, Cozzone PJ. 1H MR spectroscopy of human brain tumours: a practical approach. Eur J Radiol. 2008;67(2):268-74.
11. Law M, Yang S, Wang H, et al. Glioma grading: sensitivity, specificity, and predictive values of perfusion MR imaging and proton MR spectroscopic imaging compared with conventional MR imaging. AJNR Am J Neuroradiol. 2003;24(10):1989-98.
12. Šimundić AM. Measures of diagnostic accuracy: basic definitions. EJIFCC. 2009;19(4):203-11.
13. Newcombe RG. Two-sided confidence intervals for the single proportion: comparison of seven methods. Stat Med. 1998;17(8):857-72.
14. Majós C, Alonso J, Aguilera C, et al. Proton magnetic resonance spectroscopy (1H MRS) of human brain tumours: assessment of differences between tumour types and its

applicability in brain tumour categorization. Eur Radiol. 2003;13(3):582-91.
15. Howe FA, Barton SJ, Cudlip SA, et al. Metabolic profiles of human brain tumors using quantitative in vivo 1H magnetic resonance spectroscopy. Magn Reson Med. 2003;49(2):223-32.
16. Castillo M, Smith JK, Kwock L. Correlation of myo-inositol levels and grading of cerebral astrocytomas. AJNR Am J Neuroradiol. 2000;21(9):1645-9.
17. Garg M, Gupta RK, Husain M, et al. Brain abscesses: etiologic categorization with in vivo proton MR spectroscopy. Radiology. 2004;230(2):519-27.
18. Lu SS, Kim SJ, Kim HS, et al. Utility of proton MR spectroscopy for differentiating typical and atypical primary central nervous system lymphomas from tumefactive demyelinating lesions. AJNR Am J Neuroradiol. 2014;35(2):270-7.
19. Tsougos I, Svolos P, Kousi E, et al. Differentiation of glioblastoma multiforme from metastatic brain tumor using proton magnetic resonance spectroscopy, diffusion and perfusion metrics at 3 T. Cancer Imaging. 2012;12(3):423-36.
20. Server A, Kulle B, Gadmar ØB, Josefsen R, Kumar T, Nakstad PH. Measurements of diagnostic examination performance using quantitative apparent diffusion coefficient and proton MR spectroscopic imaging in the preoperative evaluation of tumor grade in cerebral gliomas. Eur J Radiol. 2011;80(2):462-70.
21. Wang Q, Zhang H, Zhang J, et al. The diagnostic performance of magnetic resonance spectroscopy in differentiating high-from low-grade gliomas: a systematic review and meta-analysis. Eur Radiol. 2016;26(8):2670-84.
22. Adamson AJ, Rand SD, Prost RW, et al. Focal brain lesions: effect of single-voxel proton MR spectroscopic findings on treatment decisions. Radiology. 1998;209(1):73-8.
23. Fellows GA, Wright AJ, Sibtain NA, et al. Combined use of neuroradiology and 1H-MR spectroscopy may provide an intervention limiting diagnosis of glioblastoma multiforme. J Magn Reson Imaging. 2010;32(5):1038-44.
24. Lin A, Ross BD, Harris K, Wong W. Efficacy of proton magnetic resonance spectroscopy in neurological diagnosis and neurotherapeutic decision making. NeuroRx. 2005;2(2):197-214.
25. Choi C, Ganji SK, DeBerardinis RJ, et al. 2-hydroxyglutarate detection by magnetic resonance spectroscopy in IDH-mutated patients with gliomas. Nat Med. 2012;18(4):624-9.