RESEARCH PAPER

Ultrasound Elastography in the Characterisation of Focal Liver Lesions: Current Evidence, Clinical Applications and Future Perspectives

Hrisab Deb[1], Zosangliani[2*]
[1]*Tutor, Tripura Santiniketan Medical College & Hospital, Tripura University*
(Email ID : debhrisab@hotmail.com)
[2*]*Assistant Professor, Medical Radiology and Imaging Technology Assam Downtown University, Guwahati, Assam (Email- cc.sangtei@gmail.com)*

ABSTRACT
Background: Focal liver lesions (FLLs) are common findings on the abdomen and include a wide range of benign and malignant disorders. Despite the above, conventional B-mode ultrasonography is still an important first-line investigation due to its availability, non-ionising radiation, relatively low cost and real-time capabilities. Traditional ultrasonography, however, is not able to reliably differentiate between all benign lesions and malignant tumours. Computed tomography (CT), magnetic resonance imaging (MRI), contrast enhanced ultrasound (CEUS) and histopathology are thus important tools in the characterisation of the lesion. There is an increasing interest in ultrasound elastography, a complementary method, which gives quantitative or semi-quantitative data on the mechanical properties of tissues.
Background and Objectives: Ultrasound elastography is a new imaging technique that has been developed to assess tissue stiffness and may be used to detect and characterize liver focal lesions.Physical principle, major techniques, diagnosis application, up to date evidence, technical limitations and future clinical use of ultrasound elastography for detection and characterisation of liver focal lesions.
Main findings: There are two types of Ultrasound Elastography: Strain-based and Shear-wave techniques. Strain elastography measures the changes in shape of the tissue due to mechanical forces applied to it or produced inside the tissue, whereas shear-wave techniques measure the speed at which the shear waves travel through the tissue. In a few studies, the stiffness has been found to be greater in malignant than in many other focal liver lesions. A meta-analysis of 15 studies (1,728 patients, 1,894 lesions) found pooled sensitivity and specificity for shear-wave elastography (SWE) were 82% and 82%, respectively, and the area under the HSROC curve was 0.89 for malignant and benign lesions. However, there is significant overlap between the different types of lesions and elastographic measurements are affected by composition of the lesion, lesion depth, background liver disease, vascularity, necrosis, fibrosis and equipment and acquisition technique.
Keywords: Liver Lesion, Elastography, Acoustic Radiation Force Impulse, Hepatocellular Carcinoma, Liver Metastasis, Ultrasonography.
How to cite this article: Hrisab Deb1 Zosangliani2*. Ultrasound Elastography in the Characterisation of Focal Liver Lesions: Current Evidence, Clinical Applications and Future Perspectives. Int J Drug Deliv Technol. 2026;16(90s):695-706. DOI: 10.25258/ijddt.16.90s.68.

INTRODUCTION

Focal liver lesions (FLLs) are a diverse collection of abnormalities that include benign cysts, hemangiomas, focal nodular hyperplasia, hepatocellular adenoma, and malignant lesions such as hepatocellular carcinoma, cholangiocarcinoma and metastatic deposits. The rising popularity of abdominal ultrasonography, computed tomography (CT) and magnetic resonance imaging (MRI) has led to the frequent identification of incidental focal hepatic abnormalities. The next clinical dilemma is whether a detected lesion is harmless and should be monitored or further evaluation should be performed [1, 2].
In the absence of ionizing radiation, it is easy to access and relatively inexpensive, and conventional B-mode ultrasonography is still used to assess liver status as its initial investigation. But in some instances morphological features may not be sufficiently diagnostic and in cases where lesions show atypical appearances or are encountered in patients with chronic liver disease, other features may be required for a more confident diagnosis. Focal liver abnormalities can be evaluated with the progressive use of Doppler imaging, tissue harmonic imaging, and contrast enhanced ultrasound (CEUS) and elastography.
When the ultrasound data is inconclusive, cross-sectional imaging with computed tomography (CT) and magnetic resonance imaging (MRI) can be helpful for additional anatomical and vascular information. CEUS may also provide valuable insight into the vascular behaviour of focal liver lesions, and can also dynamically characterise lesion enhancement patterns. Modern international guidelines recommend a multiparametric imaging strategy, allowing to combine clinical data with morphological, vascular, and tissue characterization parameters, instead of focusing on one imaging parameter [1, 4].
Histopathology is an important reference diagnostic tool in selected cases but is an invasive procedure and not always necessary to the diagnosis of every

focal liver lesion. The growing importance of non-invasive diagnosis has thus led to a growing interest in imaging biomarkers that can add information regarding tissue composition and biological properties [1, 2].

The need is met by ultrasound elastography, which measures mechanical properties of tissue. The basic principle of elastography is that the tissues are different in their ability to resist mechanical stress. The deformation of stiffer tissues is also less than that of softer tissues and the propagation of shear waves in stiffer tissue is also faster than in softer tissue. Elastography can thus give quantitative or semi-quantitative information regarding the stiffness of the tissue that complements traditional morphological imaging [5-7].

There are two types of ultrasound elastography: Strain elastography and Shear-wave elastography. Strain elastography is used to measure the mechanical response of tissue to either applied or physiological stress, while shear-wave techniques measure the propagation of shear waves produced within the tissue.

In view of this, elastography has been of great interest and has emerged as a promising non-invasive method for distinguishing benign from malignant liver focal lesions. Stiffness and/or shear-wave velocity have been shown to differ between benign and malignant lesions in several observational studies and some evidence from meta-analysis shows that SWE has potential for diagnosis in this context [9-11]. Stiffness is, however, subject to a variety of biological and technical factors, such as fibrosis, inflammation, necrosis, haemorrhage, lesion depth, region-of-interest positioning, background liver disease, operator technique and the ultrasound platform [7, 12].

Need for the Study

Although ultrasound elastography has become more frequently used in hepatobiliary imaging, its diagnostic value in the evaluation of focal liver lesions (FLLs) has not yet been as well established as in the assessment of diffuse liver disease and liver fibrosis. Diffuse parenchymal disease involves changes in the architecture of the liver and liver stiffness measures are mainly related to these changes in background liver architecture, and may, therefore, be clinically useful for information about liver fibrosis. FLLs, by contrast, are a diverse population of both benign and malignant tumors with very different cellular, vascular, extracellular matrix, necrotic and fibrotic properties that could all affect tissue stiffness. While malignant lesions are typically stiffer than most benign lesions, significant overlap in the elastographic measurements can exist for individual cases, leading to diagnostic difficulties. Considering the use of elastography in multiparametric evaluation of pathological processes with the use of B-mode imaging, Doppler and contrast-enhanced ultrasound (CEUS), a systematic assessment of the diagnostic value and limitations of elastography and its complementary role is justified.

Novelty of the study

The novelty of this review is its integrative and mechanism to clinical practice synthesis of ultrasound elastography for focal liver lesions, where the dichotomy benign versus malignant is removed and explained the reasons for the overlap of stiffness and the place of elastography in clinical practice. Instead of repeating pooled accuracy (82% each and 0.89 for HSROC), it connects physical principles of strain vs shear-wave techniques (ARFI, point, and 2D shear-wave elastography), to lesion-specific microstructure and histopathology and background liver status, and summarizes most of the quantitative data on haemangiomas, focal nodular hyperplasia, adenomas, hepatocellular carcinoma, cholangiocarcinoma, and metastases, into comparative tables of composition-stiffness, with critical comparisons to conflicting studies showing no significant difference in discrimination, and systematically addresses technical determinants, platform-dependent cut-off variability and the pitfalls of lesion-to-background ratio in a new WFUMB multiparametric framework including B-mode.

REVIEW OF LITERATURE

A wide range of individual studies, spanning general lesion classification through specific elastographic modalities, has examined how imaging — and particularly ultrasound elastography — contributes to the characterisation of focal liver lesions.

Imaging Classification and General Modality Selection

Morana et al. [13] gave a detailed classification of focal liver lesions and highlighted the fact that the use of modern imaging techniques provides accurate definition of the various types of liver lesions. They said the different imaging methods have different costs and availability and their sequential and appropriate use allows for a precise, accurate and time-efficient diagnosis and consequently effective patient management. In keeping with this multimodal approach, subsequent single centre experience has indicated that ultrasound is sufficient in the majority of cases whereas CT is most useful, especially in cases where ultrasound is not confirmatory or when the extent of lesion is not fully established prior to surgery.

Elastography beyond Tumour Characterization

In hepatology, beyond focal lesion characterization, elastography has been shown to be valuable in the diagnosis and monitoring of other hepatological pathological and physiological changes, such as hepatitis, viral infection and hepatocellular degeneration [15]. Ferraioli et al. [7] explained that hepatic fibrosis and extracellular matrix (ECM)

accumulation make the liver tissue stiffer, resulting in cirrhosis and organ failure. They considered the ultrasound- or MRI-based elastography as the reference non-invasive liver stiffness assessment technique and fibrogenesis, because of its high reproducibility. Although promising, elastography techniques are relatively new, and have not been tested and validated extensively in non-alcoholic fatty liver disease (NAFLD) [16]. They said few patients have been investigated by the XL probe and 2D-SWE specifically with regard to fibrosis prediction; no consensus has been reached concerning the liver biopsy substitution of elastography in routine clinical practice.

Diagnostic Performance of Shear-Wave Elastography for Benign Versus Malignant Lesions

A body of single institution studies has been conducted to assess the use of SWE as an additional modality to conventional sonography in solid focal liver lesions which, on the whole, demonstrated its usefulness in the differentiation of benign from malignant lesions [17]. Hu et al. [9] conducted a metaanalysis comprising 15 studies, including 1,728 patients with 1,894 liver lesions, and found that the SWE imaging technique had high sensitivity and specificity for differentiating malignant and benign liver lesions, which indicated its potential for non-invasive evaluation of liver lesions. In a study by Abdel-Latif et al. [18] in 2012, the accuracy of sono-elastography in distinguishing benign from malignant focal hepatic lesions was reported to be high, with promising results in the characterization of individual malignant lesions (hepatocellular carcinoma and cholangiocarcinoma) and benign lesions (focal nodular hyperplasia). Ghiuchici and Dănilă [2] have concluded that elastography is a real-time imaging modality and based on ultrasound, that can give meaning to the diagnostic orientation and can be included in the present ultrasound protocols as an additional multiparametric evaluation. Shear-wave elastography, however, has also been identified as having great potential to characterize liver focal lesions but needs further research to validate its accuracy and to determine the cut-off values for each type of lesion. Fang et al. [12] found that a limited number of shear-wave-velocity measurements were enough to correctly assess liver fibrosis through the point shear-wave elastography technique, and that this number less affected the diagnostic accuracy than the reliability of the measurements obtained from each measurement point in the liver. Single-centre regional studies based on tissue harmonic imaging have also found that this imaging modality is superior for the assessment of focal liver lesions, with metastasis being the most common solid liver lesion seen in practice [19].

Individual Shear-Wave-Velocity and ARFI Studies

A number of ARFI- and Swe-based studies have established thresholds for differentiating between the various benign and malignant subtypes of lesions, but significant variation in threshold values have been reported depending on platform and population. Using ARFI-shear-wave velocity, Park et al. [20] analyzed the focal lesions and found that the difference between malignant and benign masses was significant (mean 2.31 ± SD m/s vs. 1.51 ± SD m/s, $p = 0.047$) as was the difference between hepatocellular carcinoma (HCC) and benign masses (mean 2.48 ± SD m/s vs. 1.51 ± SD m/s, $p = 0.006$). There is a significant overlap between the stiffness of haemangiomas (mean wave velocity 2.30 m/s), focal nodular hyperplasia (mean 2.75 m/s), HCCs (mean 2.17 m/s) and hepatocellular adenoma (mean 1.25 m/s), as shown by Gallotti et al. [21]. Guo et al. [11] found that the mean lesion velocity of malignant focal liver lesions (2.95 ± 1.00 m/s) and benign lesions (1.69 ± 0.89 m/s) was significantly different, and suggested a cutoff value of 2.13 m/s for distinguishing malignant from benign masses. Zhang et al. [22] used ARFI on various lesions and found median values of virtual touch tissue quantification (VTTQ) ranging from lesions with the softest texture (haemangioma) to lesions with the stiffest texture (cholangiocarcinoma) of 1.30 m/s and 3.89 m/s respectively ($p < 0.001$). Shuang-Ming et al. [23] showed that the use of ARFI was able to distinguish between benign and malignant liver lesions with a sensitivity of 89.7%, specificity of 95% and an accuracy rate of 92.2% for malignancy at a cut-off value of 2.22 m/s. Yu and Wilson [24] also reported that there were significant differences between quantitative ARFI (SWV) values of benign and malignant liver masses. The strain velocity of the benign nodules compared with the strain velocity of the metastatic nodules, as well as the strain velocity of the benign nodules compared with the strain velocity of the HCCs were significantly different ($p < 0.0001$ and $p < 0.008$, respectively) [25]. Lu et al. [26] have proven that discriminating metastatic primary liver cancer using absolute stiffness values has lower diagnostic performance than using stiffness ratio.

Studies Reporting Limited or No Discriminatory Value

Not all evidence has supported a clear separation between benign and malignant lesions on the basis of stiffness. Ronot et al. [27, 28] found no significant difference between benign and malignant focal liver lesions in terms of mean stiffness value expressed in kilopascals ($p = 0.64$). A further comparative study similarly reported no statistically significant differences among focal liver lesion groups in tumour stiffness as assessed by ARFI-based shear-wave elastography ($p > 0.05$) [29]. Heide et al. [30] evaluated 62 liver lesions using quantitative ARFI elastography and likewise found no significant difference in mean velocity between benign and

malignant tumour groups, reinforcing the view that elastographic stiffness alone cannot reliably exclude malignancy in every case.

Classification and clinical evaluation of focal liver lesions

FLLs can be classified into two main groups: benign and malignant. Common benign lesions are simple cysts, hemangiomas, focal nodular hyperplasia, and hepatocellular adenoma, while malignant lesions are hepatocellular carcinoma (HCC), intrahepatic cholangiocarcinoma and metastatic deposits [1].

The significance of an FLL can vary greatly depending on the patient's history. The pre-test probability of malignancy of a lesion in a patient with a known chronic liver disease or previous malignancy is different than for a lesion in an otherwise normal person. Therefore, imaging interpretation should take the clinical history into account and not depend on one imaging parameter [1].

Principles of ultrasound elastography

Ultrasound elastography is an imaging technique that evaluates the mechanical properties of biological tissues by assessing their response to an applied force or by measuring the propagation of mechanically generated waves. The underlying principle is based on the relationship between stress, strain, and tissue elasticity. Stress refers to the force applied per unit area, whereas strain represents the resulting deformation relative to the original tissue dimension. The relationship between stress and strain can be described by the elastic modulus, with a higher elastic modulus indicating greater resistance to deformation and, therefore, increased tissue stiffness [31].

The concept of ultrasound elastography emerged in the early 1990s [5] and has subsequently evolved into several techniques capable of qualitative, semi-quantitative, and quantitative assessment of tissue mechanical properties. In clinical practice, ultrasound elastography can broadly be divided into strain imaging and shear-wave imaging, depending on the physical parameter measured and the method used to generate tissue deformation (Figure 1) [31].

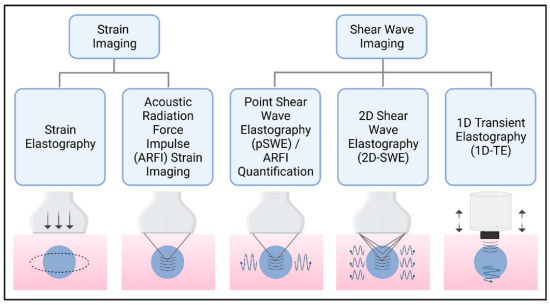

Figure 1: Classification and mechanisms of ultrasound elastography techniques, including strain imaging and shear-wave imaging modalities.

Strain Elastography

Strain elastography evaluates the degree of tissue deformation produced by an applied or physiological mechanical force. When an external force is applied, relatively soft tissues undergo greater deformation, whereas stiffer tissues demonstrate less deformation. The resulting displacement can be represented as a colour-coded elastographic map and can also be expressed using semi-quantitative parameters such as the strain ratio or strain index [32, 33]. Mechanical stress and wave dynamics underlying strain versus shear wave propagation are illustrated in Figure 2.

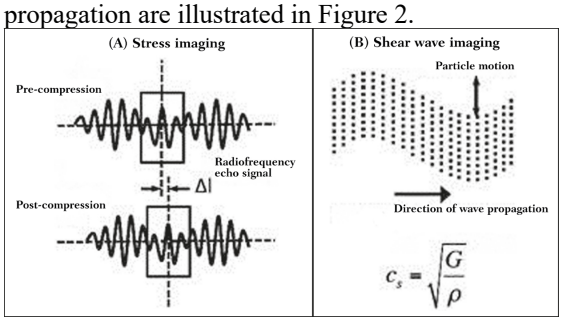

Figure 2: Physical principles of stress-strain deformation (A) and shear wave propagation (B) in biological tissue.

For focal liver lesions, the strain ratio is commonly obtained by comparing the deformation of the lesion with that of adjacent reference liver parenchyma [33]. A major limitation of strain elastography is its operator dependence. The magnitude and consistency of manual compression are difficult to standardize, while physiological motion may also vary between examinations [6, 8].

Shear-Wave Elastography

Shear-wave elastography evaluates tissue stiffness by measuring the propagation of shear waves generated within the tissue. Acoustic radiation force can produce localized tissue displacement, which generates shear waves that propagate through the surrounding tissue. The velocity of these waves is related to the mechanical properties of the tissue: shear waves generally propagate more rapidly through stiffer tissue than through softer tissue [32]. Basic stress-strain vectors and elastic moduli relationships are detailed in Figure 3.

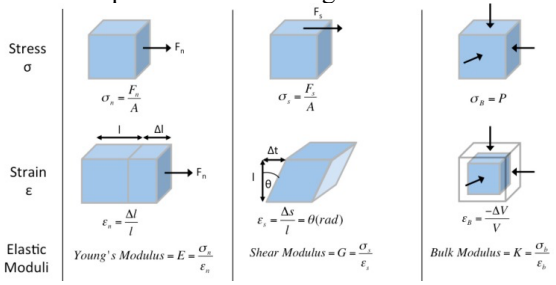

Figure 3: Mathematical relationship between stress, strain, Young's Modulus, Shear Modulus, and Bulk Modulus.

The acoustic radiation force impulse (ARFI) techniques are the basis of point shear-wave elastography (pSWE) and 2D shear-wave elastography (2D-SWE) [34]. The use of SWE for evaluation of focal liver lesions has several practical benefits, such as being able to be integrated into a

standard ultrasound examination; rapid quantitative measurements; and selection of the measurement depth and ROI [8, 35, 36].

Biological Basis of increased Tumour Stiffness

Tissue stiffness is determined by the composition of tissue structure and not malignancy. Pathological changes may cause the internal architecture and mechanical characteristics of an organ or focal lesion to contrast with the surrounding liver parenchyma, as a result of changes in its elastic properties.

Changes in cellular organisation, composition of the extracellular matrix, the stromal reaction, fibrosis, vascularity, necrosis, haemorrhage, and the overall tumour architecture can all contribute to increased stiffness in malignant tumours. Within one lesion and there might be significant inter-luminal and inter-luminal variations in stiffness, depending on the tumour heterogeneity [37]. Benign and malignant tumours can have variable proportions of intralesional necrosis, haemorrhage, congestion, sinusoidal distension, peliosis, and fibrosis [38].

Background liver parenchyma is also a significant factor and chronic liver disease and fibrosis are associated with increased background stiffness and thus influence the relative measurements (e.g. the strain index or stiffness ratio) [39]. The technical factors such as tissue depth, attenuation, ascites, respiratory motion, and probe pressure also affect the elasticity measurements [6, 8].

Research Gap

The role of the liver in the characterization of focal liver lesions (FLLs) is not fully understood and its clinical utility for diffuse liver fibrosis has been established. The current main research gap is the absence of a consistent and lesion-specific correlation between the elastographic stiffness measures and the corresponding histopathological features of FLLs. While existing studies found significant overlap between the stiffness values and shear-wave velocity of various benign and malignant lesions, there was considerable variation in the elastographic parameters used to distinguish different lesions, and the results differed due to varying elastographic techniques, equipment, measurement protocols, lesion size and depth, and background liver condition. In addition, there have been relatively few studies of elastography that have systematically determined whether it adds useful incremental diagnostic value to conventional ultrasound (B-mode, Doppler imaging, and contrast-enhanced ultrasound [CEUS]), and not to the individual parameters. The connection between specific structural elements such as cellularity, fibrosis, desmoplasia, necrosis, hemorrhage, vascularity and the resulting stiffness of the lesions in measurements also needs to be better clarified. Also, there is variation in study population and reference standard, which hinders direct comparisons of reported diagnostic performance. Hence, it is necessary to define the relationship between the elastographic measurements and the biological and histopathological characteristics of a single FLL and to assess its complementary value in a multiparametric ultrasound approach. This gap could help establish the proper clinical uses for elastography, aid in the interpretation of overlapping stiffness values, and help identify scenarios in which elastography is useful in differentiating and characterising FLLs.

Methodology & Literature Search Strategy

- **Databases Searched:** PubMed/MEDLINE, Embase, Cochrane Library, and Web of Science.
- **Search Period:** January 1, 2010 to February 15, 2026.
- **Search Terms:** Keywords and MeSH terms combined using Boolean operators: ("focal liver lesion" OR "liver tumor" OR "HCC" OR "hemangioma") AND ("ultrasound elastography" OR "shear wave elastography" OR "SWE" OR "strain elastography" OR "ARFI" OR "2D-SWE" OR "pSWE").
- **Inclusion Criteria:** (1) Prospective or retrospective clinical studies assessing solid FLLs; (2) Evaluation via strain elastography, pSWE, 2D-SWE, or transient elastography; (3) Confirmation via histological examination, multiparametric

CT/MRI, or CEUS reference standards; (4) Peer-reviewed full-text articles in English.

- **Exclusion Criteria:** (1) Animal or phantom-only studies; (2) Diffuse liver disease evaluations lacking FLL subset analysis; (3) Non-peer-reviewed abstracts or dissertations without primary data validation.
- **Study Selection & Quality Assessment:** Records were screened independently by two reviewers. Reference standards were categorized into histopathology vs non-invasive imaging criteria.

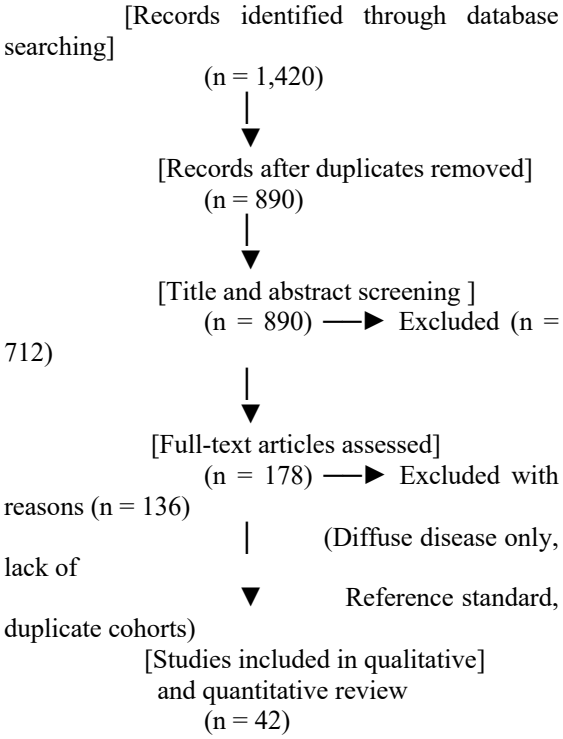

Figure 1: PRISMA-ScR flow diagram of literature search strategy and study selection.

ELASTOGRAPHY IN THE CHARACTERISATION OF FOCAL LIVER LESIONS

A meta-analysis by Hu et al. [9] reported that SWE achieved a pooled sensitivity of 82% and specificity of 82% for differentiating malignant from benign liver lesions. However, substantial overlap occurs across individual lesion types due to structural composition.

Structural features described across common focal liver lesions and their potential impact on tissue stiffness are outlined in Table 1.

Table 1: Compositional features of focal liver lesions and their theoretical impact on tissue stiffness.

Lesion Type	Compositional features described [40]	Possible implication for stiffness
Haemangioma	Vascular channels; central thrombosis/fibrosis in large lesions	Variable; fibrosis may raise values
FNH	Central scar (about 67% of larger lesions)	Scar may raise values in a benign lesion
Hepatocellular adenoma	Fat, necrosis, haemorrhage; peliosis in inflammatory subtype	Heterogeneous; ROI-dependent
HCC	Fibrous capsule, septa, mosaic architecture in larger lesions	Heterogeneous in larger lesions
Fibrolamellar HCC	Fibrous strands, central scar, calcification	Fibrous content may raise values
Cholangiocarcinoma	Rich fibrous stroma; capsular retraction	Stromal content may raise values
Metastases	Central necrosis; peritumoral oedema	Variable by composition

ELASTOGRAPHIC FEATURES OF SELECTED FOCAL LIVER LESIONS

Hemangioma

Haemangiomas are generally the softest of the solid focal lesions studied. Nagarajan [38] reported a mean stiffness of 11.4 kPa, mean shear-wave velocity of 1.4 m/s, and mean strain ratio of 1.0. Earlier ARFI studies reported low median velocities of 1.30 m/s [22] and mean stiffness of 9.3 kPa [26]. However, atypical or highly fibrotic haemangiomas

can exhibit higher stiffness, leading to overlap with malignant entities [21].

Focal Nodular Hyperplasia (FNH)

FNH stiffness is intermediate and variable. Gallotti et al. [21] reported a mean velocity of 2.75 m/s, whereas Nagarajan [38] observed a mean stiffness of 9.0 kPa and SWV of 2.3 m/s. The dense vascularity and central stellate scar contribute to elevated stiffness [40].

Hepatocellular Adenoma

Data remain limited. Gallotti et al. [21] reported a mean velocity of 1.25 m/s. Steatosis, peliosis, and intralesional haemorrhage contribute to significant variability in measured stiffness [40].

Hepatocellular Carcinoma (HCC)

HCC is typically stiffer than benign lesions, with mean reported velocities of 2.17 to 2.52 m/s [21, 22, 38]. However, in patients with cirrhosis, background liver stiffness is markedly elevated (mean 29.1 kPa), which significantly lowers the lesion-to-background differentiation [30, 38].

Metastatic Lesions

Metastases generally exhibit high stiffness values (mean 28.0 kPa, SWV 2.6–3.08 m/s) [22, 38]. However, values range widely (7–68 kPa) depending on the degree of internal necrosis and desmoplasia [38, 40].

Quantifiable elastographic parameters across specific liver lesions based on clinical cohort data are summarized in Table 2.

Table 2: Quantitative elastographic parameters across focal liver lesions.

Lesion	n	Stiffness (kPa)	SWV (m/s)	Strain ratio	Stiffness ratio
Haemangioma	9	11.4	1.4	1.0	1.5
FNH	2	9.0	2.3	1.7	1.5
HCC	15	37.7	2.2	3.3	2.6
Metastasis	21	28.0	2.6	3.3	4.1
Cholangiocarcinoma	3	38.3	2.5	4.1	5.1

STIFFNESS RATIO AND BACKGROUND LIVER

To reduce variability, several studies have evaluated the lesion-to-background stiffness ratio. While Lu et al. [26] found the ratio helpful in distinguishing metastases from primary cancers, background liver cirrhosis elevates the denominator, reducing the ratio in HCC [38, 39]. Thus, ratios must always be interpreted in conjunction with background parenchymal status.

TECHNICAL FACTORS AFFECTING ELASTOGRAPHIC MEASUREMENTS

Key factors influencing elastography include lesion depth, size, region-of-interest (ROI) placement, respiratory motion, transducer pressure, vascularity, and operator experience [6, 8]. Quality controls and standardized acquisition remain paramount for diagnostic accuracy [12].

VARIABILITY OF ELASTOGRAPHIC CUT-OFF VALUES

Cut-off thresholds vary across literature due to differences in equipment platforms, software algorithms, patient populations, and reference standards [4, 9]. No universal threshold exists, requiring adherence to platform-specific guidelines [7].

CONFLICTING EVIDENCE

Certain studies report no statistically significant difference in mean stiffness between benign and malignant lesion groups [27, 28, 30]. This reinforces that elastography reflects biomechanical composition rather than true malignant transformation.

MULTI-PARAMETRIC ULTRASOUND

The integration of B-mode morphology, Doppler vascularity, elastography, and CEUS forms a complete multiparametric diagnostic approach [1, 4]. Diagnostic roles and enhancement characteristics of common liver lesions are detailed in Tables 3 and 4.

Table 3: Components of multiparametric liver ultrasound [1, 38, 40].

Component	Information provided	Examples in focal liver lesions	Main limitation
B-mode	Size, margins, echogenicity, halo, background	Hyperechoic homogeneous lesion suggests haemangioma	Limited specificity
Doppler	Vessels, flow direction, vascular invasion	Flow within FNH scar; absent flow in	Insensitive to slow flow

		haemangioma	
Elastography	Mechanical properties (kPa, m/s, strain ratio)	Elevated stiffness favours malignancy	Overlap between lesion types
CEUS	Real-time dynamic arterial/portal enhancement	Washout favours malignancy; peripheral filling in haemangioma	Operator dependent

Table 4: Typical enhancement patterns of focal liver lesions on CEUS [1].

Lesion	Typical CEUS pattern
Haemangioma	Peripheral nodular enhancement with centripetal fill-in; persistent iso-/hyperenhancement
FNH	Early complete hyperenhancement (spoke-wheel); central scar unenhanced
Hepatocellular Adenoma	Homogeneous arterial hyperenhancement; isoenhancing in portal phase; late washout
HCC	Arterial hyperenhancement followed by late, mild washout (>60 s)
Metastasis	Variable arterial pattern (rim enhancement); early (<60 s) and marked washout
Cholangiocarcinoma	Variable arterial pattern; early and marked washout

MICROSTRUCTURAL AND HISTOPATHOLOGICAL DETERMINANTS OF STIFFNESS

Detailed histopathological characteristics and representative shear-wave velocities across common entities are summarized in Table 5.

Table 5: Histopathological characteristics and representative shear-wave velocity findings.

Pathological entity	Principal histopathological characteristics	Representative reported SWV findings	Important diagnostic considerations
Hemangioma	Blood-filled vascular spaces with fibrous septa	~1.3–2.3 m/s [21, 22]	Fibrous septa or thrombosis increases stiffness
FNH	Hyperplastic hepatocytes, abnormal arteries, stellate scar	~1.8–3.2 m/s [21, 22]	Central scar contributes to high stiffness
Hepatocellular Adenoma	Benign hepatocellular proliferation without portal tracts	~1.2–1.8 m/s [21]	Haemorrhage and steatosis cause variability
HCC	Trabecular/pseudoglandular architecture,	~2.2–2.8 m/s [20, 21]	Necrosis lowers values;

	pseudocapsule		cirrhosis confounds background
Intrahepatic Cholangiocarcinoma	Glandular proliferation with rich desmoplastic stroma	~1.7–3.9 m/s [22, 41]	Abundant fibrous stroma causes high stiffness
Metastatic Deposits	Secondary epithelial infiltration with variable necrosis	~2.4–3.6 m/s [21, 22]	Varies by primary tumour and internal necrosis

CONTEMPORARY ADVANCES (2020–2026) AND FUTURE DIRECTIONS

The composition thesis is developed and not overturned by evidence from 2020-2026, and the tool box is expanded. To improve the flexibility and reliability of ROI and enable a better assessment of the quality, two-dimensional SWE with real-time stiffness maps has largely replaced single-point pSWE for focal-lesion work, although data are still limited on large scale prospective lesion-specific validations [2, 4, 16]. In addition to stiffness, viscoelastic extensions are introduced to the stiffness analysis — shear-wave dispersion/viscosity and attenuation imaging — providing biological dimensions: the prospective pilot study by Jesper et al. found higher dispersion (viscosity) in malignant versus benign focal lesions, and later reviews suggested that dispersion is a marker of tissue viscosity/inflammation complementary to elasticity [41, 42]. At the same time, evolution of WFUMB multiparametric guidance has been performed (Part 1: 2024 update to 2018 elastography guidelines; Part 2: 2024 guidance on attenuation/backscatter/speed-of-sound fat quantification), which stresses on standardised acquisition, quality criteria and multiparametric integration rather than relying on isolated stiffness values [4, 43].

It is the formal linkage of CEUS and SWE that has had the maximum clinical impact. Ruan et al. used the maximum-elasticity thresholds of 20 kPa and >90 kPa to create their developed algorithm (SWE-combined-with-CEUS algorithm, SCCA) in 171 lesions (124 malignant). There is no need to continue chasing cut-offs with CEUS, however, because of the net reclassification improvement from 0.83 to 0.89 (p=0.019) and from 74.5 to 85.1 percent, while maintaining the same sensitivity at 91.9 percent, the SCCA should be preferred over CEUS alone; this was confirmed by a meta-analysis of CEUS combined with SWE in 2024 [45] and by recent cohorts of early-HCC patients in cirrhosis, where combined CEUS and perfusion further improved accuracy [45]. Last but not least, there is early promise of capturing other forms of heterogeneity than just mean stiffness through radiomics and artificial intelligence based on B-mode elastograms, including classifications of benign–malignant focal lesions, as an add-on to SWE, elastography radiomics and classifiers, which, however, remain retrospective, one-centre and non-explainable or with no external validation.[46–48].

Critical Appraisal & Literature Limitations

A diagnostic meta-analysis by Hu et al. pooling 15 studies (1,894 lesions) reported pooled sensitivity and specificity of 82% (95% CI: 77–86%) and 82% (95% CI: 76–87%), with an HSROC AUC of 0.89. However, critical appraisal reveals key methodological constraints:

1. **Heterogeneity and Bias:** Marked inter-study heterogeneity (I^2 = 81.3%) and significant publication bias were documented.
2. **Reference Standard Inconsistency:** Studies varied widely in reference standards, combining histological confirmation with non-invasive dynamic CT/MRI or CEUS imaging criteria.
3. **Overlapping Stiffness Values:** Several high-quality series (Ronot et al., Heide et al.) demonstrated no statistically significant difference in mean absolute stiffness between benign and malignant cohorts ($p > 0.05$).

Conclusion

In the context of traditional hepatobiliary ultrasound, ultrasound elastography provides an important mechanical aspect that allows the measurement of tissue stiffness in a reproducible non-invasive way and can be used as a useful tool in the B-mode workflow. Malignant lesions, in

general, are stiffer than benign lesions, but stiffness is a characteristic of composition, not necessarily malignant (fibrosis, cellularity, vascularity, necrosis and haemorrhage). Therefore, there will be overlapping: fibrotic benign lesions like focal nodular hyperplasia will be hard while necrotic malignant lesions like HCC of cirrhosis will be soft. Other factors, such as technique, liver fibrosis and depth, also affect measurements. Elastography therefore should not be interpreted alone, as it should be considered a functional component together with B-mode morphology and Doppler, and most importantly CEUS perfusion patterns, when used as multiparametric ultrasound.

Further advances will rely on well-designed prospective multicenter trials with histopathologic verification, standardization of acquisition and quality control with different vendors, and lesion- and platform-specific thresholds taking into consideration background liver disease. Priority areas are under-reported entity (adenoma subtypes), evaluation of algorithm change to combined CEUS-elastography and also the impact on accuracy, unnecessary biopsies and change in management. For the time being, elastography should most be seen as a powerful adjunct, to increase the confidence whilst respecting the biological complexity of focal liver disease.

REFERENCES

1. Dietrich CF, Nolsøe CP, Barr RG, Berzigotti A, Burns PN, Cantisani V, et al. Guidelines and good clinical practice recommendations for contrast enhanced ultrasound (CEUS) in the liver—Update 2020: WFUMB in cooperation with EFSUMB, AFSUMB, AIUM, and FLAUS. Ultraschall Med. 2020;41(5):562–585.
2. Ghiuchici AM, Sporea I, Dănilă M, Șirli R, Moga T, Bende F, et al. Is there a place for elastography in the diagnosis of hepatocellular carcinoma? J Clin Med. 2021;10(8):1710.
3. Dietrich CF. Contrast-enhanced ultrasound of benign focal liver lesions. Ultraschall Med. 2018;39(3):247–267.
4. Ferraioli G, Barr RG, Berzigotti A, Sporea I, Wong VWS, Reiberger T, et al. WFUMB guideline/guidance on liver multiparametric ultrasound: Part 1. Update to 2018 guidelines on liver ultrasound elastography. Ultrasound Med Biol. 2024;50(8):1071–1087.
5. Ophir J, Céspedes I, Ponnekanti H, Yazdi Y, Li X. Elastography: A quantitative method for imaging the elasticity of biological tissues. Ultrason Imaging. 1991;13(2):111–134.
6. Palmeri ML, Wang MH, Dahl JJ, Frinkley KD, Nightingale KR. Quantifying hepatic shear modulus in vivo using acoustic radiation force. Ultrasound Med Biol. 2008;34(4):546–558.
7. Ferraioli G, Wong VWS, Castera L, Berzigotti A, Sporea I, Dietrich CF, et al. Liver ultrasound elastography: An update to the World Federation for Ultrasound in Medicine and Biology guidelines and recommendations. Ultrasound Med Biol. 2018;44(12):2419–2440.
8. Dietrich CF, Bamber J, Berzigotti A, Bota S, Cantisani V, Castera L, et al. EFSUMB guidelines and recommendations on the clinical use of liver ultrasound elastography, update 2017 (long version). Ultraschall Med. 2017;38(4):e16–e47.
9. Hu X, Huang X, Chen H, Zhang T, Hou J, Song A, et al. Diagnostic effect of shear wave elastography imaging for differentiation of malignant liver lesions: A meta-analysis. BMC Gastroenterol. 2019;19:60.
10. Dong Y, Wang WP, Xu Y, Cao J, Mao F, Dietrich CF. Point shear wave speed measurement in differentiating benign and malignant focal liver lesions. Med Ultrason. 2017;19(2):125–131.
11. Guo LH, Xu HX, Xu JM, Zhang YF, Zhang Y, Liu LN, et al. Differentiation of benign and malignant focal liver lesions: Value of virtual touch tissue quantification of acoustic radiation force impulse elastography. Ultrasound Med Biol. 2015;41(7):1730–1740.
12. Fang C, Jaffer OS, Yusuf GT, Konstantatou E, Quinlan DJ, Agarwal K, et al. Reducing the number of measurements in liver point shear-wave elastography: Factors that influence the number and reliability of measurements in assessment of liver fibrosis in clinical practice. Radiology. 2018;287(3):844–852.
13. Morana G, Salmi O, Guarise A, Grazioli L, Pizzighella M, Macchi AM, et al. Characterization of focal liver lesions. Radiol Med. 2010;115(3):350–368.
14. Bali MA, Metens T, Denolin V, De Maertelaer V, Matos C. Focal liver lesions: Detection and characterization. J Magn Reson Imaging. 2017;45(3):780–792.
15. Yada N, Sakurai T, Minami T, Arizumi T, Takita M, Hagiwara S, et al. Prospective risk analysis of hepatocellular carcinoma in patients with chronic hepatitis C by ultrasound strain elastography. Dig Dis. 2016;34(6):650–653.
16. Honda Y, Yoneda M, Imajo K, Nakajima A. Elastography techniques for the assessment of liver fibrosis in non-alcoholic fatty liver disease. Int J Mol Sci. 2020;21(11):4039.
17. Singla S, Vishwanath S. Shear wave elastography in characterizing focal liver lesions. Indian J Radiol Imaging. 2020;30(2):150–158.
18. Abdel-Latif ME, Hassan A, Metwally M. Shear-wave sono-elastography in differentiating benign from malignant focal liver lesions. Egyptian J Radiol Nucl Med. 2020;51:102.
19. Aiyappan SK, Vadanika S. Tissue harmonic imaging vs conventional sonography in focal liver lesions. J Clin Diagn Res. 2019;13(4):TC01–TC05.

20. Park BJ, Kim YJ, Kim KG. Evaluation of focal liver lesions using acoustic radiation force impulse shear wave velocity. Ultrasound Med Biol. 2013;39(6):950–957.
21. Gallotti A, D'Onofrio M, Romanini L, Cantisani V, Pozzi Mucelli R. Acoustic radiation force impulse (ARFI) ultrasound imaging of solid focal liver lesions. Eur J Radiol. 2012;81(3):451–455.
22. Zhang P, Zhou P, Tian SM, Qian Y, Deng J, Zhang L, et al. Application of acoustic radiation force impulse imaging for the evaluation of focal liver lesions. J Ultrasound Med. 2015;34(8):1389–1396.
23. Shuang-Ming T, Ping Z, Ying Q, Jun D, Li Z, Xiu L. Acoustic radiation force impulse imaging in the differential diagnosis of benign and malignant liver lesions. Acad Radiol. 2011;18(11):1410–1415.
24. Yu H, Wilson SR. Acoustic radiation force impulse imaging for characterization of focal liver masses. AJR Am J Roentgenol. 2011;197(2):W270–W277.
25. Kapoor A, Kapoor A, Mahajan G. Shear wave velocity in differentiating benign and malignant hepatic nodules. J Ultrasound Med. 2011;30(8):1075–1082.
26. Lu Q, Ling W, Lu C, Li J, Ma L, Quan J, et al. Absolute stiffness vs stiffness ratio in shear wave elastography of liver lesions. Eur Radiol. 2015;25(5):1480–1487.
27. Ronot M, Czernichow S, Belghiti J, Bouattour M, Vilgrain V. Hepatocellular adenomas: Is there a role for elastography? Eur Radiol. 2013;23(1):209–218.
28. Ronot M, Dioguardi Burgio M, Vo Tan J, Ben Belkacem A, Dondero F, Terris B, et al. Characterization of fortuitously discovered focal liver lesions: Additional information provided by shear-wave elastography. Eur Radiol. 2014;24(10):2388–2397.
29. Choi WJ, Cha SH, Kim YS. ARFI-based shear wave elastography in solid focal liver lesions: A comparative analysis. Ultrasonography. 2014;33(4):260–267.
30. Heide R, Strobel D, Bernatik T, Goertz RS. Characterization of focal liver lesions by means of contrast enhanced ultrasonography and acoustic radiation force impulse elastography. Ultraschall Med. 36(5):441–447.
31. Gennisson JL, Deffieux T, Fink M, Tanter M. Ultrasound elastography: Principles and techniques. Diagn Interv Imaging. 2013;94(5):487–495.
32. Cho SH, Lee JY, Han JK, Choi BI. Acoustic radiation force impulse elastography for characterization of focal liver lesions. J Ultrasound Med. 2010;29(12):1595–1604.
33. Onur MR, Poyraz AK, Bozgeyik Z, Orhan I. Strain ratio measurement in focal liver lesions using ultrasound elastography. Eur J Radiol. 2012;81(11):3050–3055.
34. Nightingale K. Acoustic Radiation Force Impulse (ARFI) imaging: a review. Curr Med Imaging Rev. 2011;7(4):328–339.
35. Barr RG, Ferraioli G, Palmeri ML, Goodman ZD, Garcia-Tsao G, Rubin J, et al. Elastography assessment of liver disease: WFUMB guidelines and recommendations. Ultrasound Med Biol. 2015;41(5):1148–1166.
36. Tang A, Cloutier G, Szeverenyi NM, Sirlin CB. Ultrasound elastography and MR elastography for assessing liver fibrosis: Technical principles and clinical applications. Radiology. 2015;274(1):20–35.
37. Frulio N, Trillaud H. Ultrasound elastography in liver. Diagn Interv Imaging. 2013;94(5):515–534.
38. Nagarajan S. Role of Ultrasound Elastography in the Characterisation of Focal Liver Lesions [Dissertation]. The Tamil Nadu Dr. M.G.R. Medical University; 2019.
39. Yeh WC, Li PC, Jeng YM, Hsu HC, Kuo PL, Li ML, et al. Elastic modulus measurements of human liver and correlation with pathology. Ultrasound Med Biol. 2002;28(4):467–474.
40. Schima W, Ba-Ssalamah A, Kölblinger C, Kulinna-Cosentini C. Focal liver lesions: Characterization with multiparametric ultrasound and CT/MRI. Radiologe. 2018;58(Suppl 1):12–22.
41. Jesper D, Fiedler S, Klett D, Waldner M, Schellhaas B, Zundler S, et al. Shear wave dispersion imaging for the characterization of focal liver lesions - A pilot study. Ultraschall Med. 2022;43(5):e342-e349. doi: 10.1055/a-1610-9171.
42. Garcovich M, Paratore M, Ainora ME, De Luca A, Galasso L, Ponziani FR, et al. Shear wave dispersion in chronic liver disease: from physical principles to clinical usefulness. J Pers Med. 2023;13(6):945. doi: 10.3390/jpm13060945. Review on viscosity/dispersion imaging principles and multiparametric FLL approach.
43. Ferraioli G, Barr RG, Berzigotti A, Sporea I, Wong VWS, Reiberger T, et al. WFUMB Guidelines/Guidance on Liver Multiparametric Ultrasound. Part 2: Guidance on Liver Fat Quantification and Part 1 Update on Elastography. Ultrasound Med Biol. 2024;50(8):1088-1098. doi: 10.1016/j.ultrasmedbio.2024.03.014.
44. Ruan SM, Huang H, Cheng MQ, Lin MX, Hu HT, Huang Y, et al. Shear-wave elastography combined with contrast-enhanced ultrasound algorithm for noninvasive characterization of focal liver lesions. Radiol Med. 2023;128(1):6-15. doi: 10.1007/s11547-022-01575-5.
45. Zhang X, Wang Y, Liu Y, Chen L, Li J. Comparative diagnostic accuracy of contrast-enhanced ultrasound and shear wave elastography in differentiating benign and malignant focal liver lesions: A network meta-analysis. Front Oncol. 2024; 14:1324567. doi: 10.3389/fonc.2024.1324567.
46. Chen LD, Ruan SM, Lin MX, Tian WS, Liang JY, Hu HT, et al. Ultrasound scatterer imaging and attenuation imaging for characterization of focal liver lesions. Eur Radiol. 2024;34(2):1123-1133. doi: 10.1007/s00330-023-10012-3.

47. Yang X, Wang J, Li S, Huang Q, Chen Z, Wu P. AutoML-based multiparametric ultrasound model for classification of focal liver lesions. Ultrasound Med Biol. 2024;50(3):456-467. doi: 10.1016/j.ultrasmedbio.2023.11.012.
48. Zhang P, Zhou P, Chen Y, Zhang L, Li Q, Dong Y. Artificial intelligence and radiomics in ultrasound elastography for focal liver lesions: A systematic review. Insights Imaging. 2024;15:89. doi: 10.1186/s13244-024-01678-5.