RESEARCH PAPER

Clinical and Dermoscopic Evaluation of Intradermal Tranexemic acid Versus Microneedling-Assisted Topical Tranexamic Acid in the Treatment of Melasma: A Prospective Randomized Comparative Study

Dr Dikshith B Swamy[1] Dr Sangeethaspoorthy S[2] Dr Fathimatul Mursida[3] Dr Sathish Shankar[4]

1. Dr Dikshith B Swamy. Senior Resident, Department of dermatology, venerology and leprosy, Email : dikshithbs.dbs@gmail.com
2. Dr Sangeethaspoorthy S. post graduate, Department of dermatology,venerology and leprosy , Email- sangeethasspoorthy2000@gmail.com
3. Dr Fathimatul Mursida. post graduate, Department of dermatology,venerology and leprosy , Email- drfathimaderma@gmail.com
4. Dr Sathish Shankar. Associate Professor , Department of dermatology,venerology and leprosy

Corrosponding Author : Dr Dikshith B Swamy. Senior Resident, Department of dermatology, venerology and leprosy, Email : dikshithbs.dbs@gmail.com

Abstract

Background:

Melasma is a chronic acquired hyperpigmentary disorder with a significant psychosocial impact. Tranexamic acid (TXA) has emerged as an effective treatment, but evidence directly comparing intradermal TXA with microneedling-assisted topical TXA remains limited.

Objective: To compare the clinical efficacy, dermoscopic outcomes, patient satisfaction, and safety of intradermal tranexamic acid and microneedling-assisted topical tranexamic acid in patients with melasma.

Materials and Methods: This prospective, randomized comparative study included 60 patients with melasma, equally allocated to receive either intradermal TXA (Group A, n=30) or microneedling-assisted topical TXA (Group B, n=30). Treatments were administered once weekly for 12 weeks. Clinical outcomes were assessed using the Melasma Area and Severity Index (MASI), Investigator's Global Assessment (IGA), Patient Global Assessment (PGA), dermoscopic evaluation, and adverse-effect profile.

Results: Both treatment modalities produced significant clinical improvement. However, intradermal TXA demonstrated significantly greater reductions in MASI and IGA scores and greater dermoscopic improvement from Week 4 onward ($p < 0.001$). At Week 12, the mean MASI score was **3.46 ± 1.26** in Group A versus **5.99 ± 0.42** in Group B, while the mean IGA score was **0.97 ± 0.67** versus **2.10 ± 0.61**, respectively. Patient satisfaction was significantly higher in the intradermal group, with **66.7%** of patients reporting excellent or very good improvement compared with **26.7%** in the microneedling-assisted topical TXA group (p = 0.008). Both treatments were well tolerated, although pain was more common with intradermal TXA, whereas erythema and burning sensation were more frequent following microneedling-assisted topical TXA, with a significant overall difference in the adverse-effect profile (p = 0.031).

Conclusion: Both treatment modalities were effective in the treatment of melasma; however, intradermal tranexamic acid showed significantly better clinical and dermoscopic improvement than microneedling-assisted topical tranexamic acid, with higher patient satisfaction and an acceptable safety profile.

Keywords: Melasma; Tranexamic acid; Intradermal tranexamic acid; Microneedling; Dermoscopy; Melasma Area and Severity Index.

How to cite this article: Dikshith B Swamy1 Dr Sangeethaspoorthy S2 Dr Fathimatul Mursida3 Dr Sathish Shankar4. Clinical and Dermoscopic Evaluation of Intradermal Tranexemic acid Versus Microneedling-Assisted Topical Tranexamic Acid in the Treatment of Melasma: A Prospective Randomized Comparative Study . Int J Drug Deliv Technol. 2026;16(90s):801-808. DOI: 10.25258/ijddt.16.90s.79.

Introduction

Melasma is a common acquired hyperpigmentary disorder characterized by symmetrical light- to dark-brown or gray-brown macules and patches affecting predominantly sun-exposed areas of the face. Although benign, its chronic relapsing course, cosmetic disfigurement, and frequent recurrences can have a substantial psychosocial impact and adversely affect patients' quality of life **(1–3).**

Melasma has a multifactorial etiology. Ultraviolet (UV) radiation is the principal triggering factor, while genetic predisposition, hormonal influences, pregnancy, oral contraceptive use, thyroid dysfunction, cosmetic products, photosensitizing medications, and visible light exposure are recognized contributors. The pathogenesis is complex and involves melanocyte hyperactivity, oxidative stress, inflammatory mediators, and vascular alterations. Ultraviolet-induced reactive oxygen species stimulate melanogenesis through activation of tyrosinase, while increased vascular endothelial growth factor (VEGF) expression

contributes to angiogenesis and persistence of pigmentation **(2–5).**

Melasma predominantly affects women of reproductive age and individuals with Fitzpatrick skin phototypes III–V, particularly in tropical and subtropical regions. Management remains challenging because treatment responses are often incomplete and recurrences are common. Current therapeutic options include topical depigmenting agents such as hydroquinone, azelaic acid, kojic acid, retinoids, cysteamine, and triple-combination creams, as well as oral tranexamic acid, chemical peels, laser and light-based procedures, and combination therapies. Despite these modalities, an ideal treatment that is consistently effective, safe, and associated with a low recurrence rate remains elusive **(4–7).**

Among the available therapeutic agents, tranexamic acid (TXA), a synthetic lysine analogue with antifibrinolytic properties, has emerged as a promising treatment for melasma. By inhibiting the plasminogen–plasmin pathway, TXA suppresses ultraviolet-induced melanogenesis by reducing the release of arachidonic acid and prostaglandins, decreasing tyrosinase activity, and downregulating vascular endothelial growth factor (VEGF) expression, thereby targeting both the pigmentary and vascular components of the disease. Tranexamic acid can be administered orally, topically, intradermally, or through microneedling. Microneedling-assisted topical delivery has recently gained attention as a minimally invasive technique that enhances transdermal drug penetration with minimal systemic exposure **(6–9).**

The Melasma Area and Severity Index (MASI) (Figure 1) is the most widely used clinical tool for assessing treatment response, although it is observer dependent. Dermoscopy is a simple, non-invasive imaging technique that enables objective evaluation of pigment distribution and vascular changes, thereby improving assessment of disease severity and therapeutic outcomes **(10–12).**

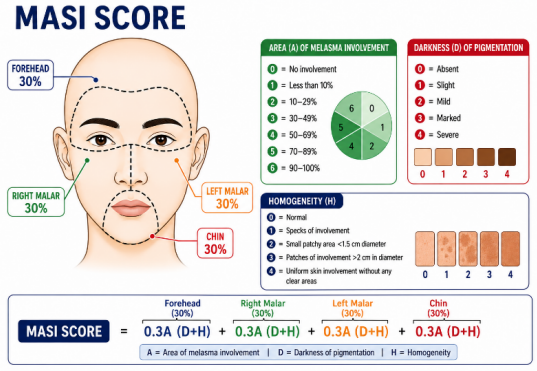

Figure 1

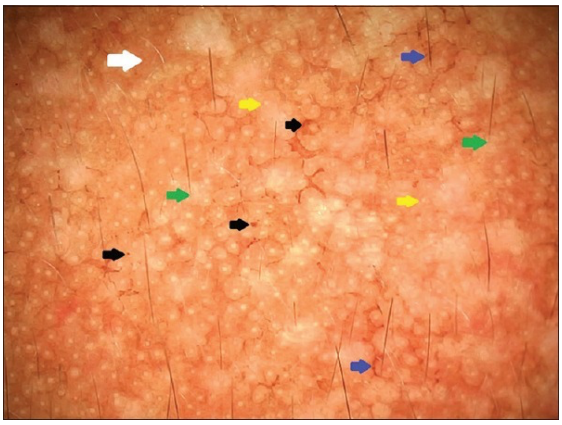

Figure 2: Dermoscopy of the melasma lesion revealing diffuse light-to-dark brown (white arrow) pseudoreticular network, multiple brown dots, granules and globules (black arrows), arcuate and annular structures (blue arrows), with sparing of the perifollicular region (green arrows), and around the openings of sweat glands (yellow arrows) (polarizing mode, ×20)

Although both intradermal tranexamic acid and microneedling-assisted topical tranexamic acid have demonstrated promising efficacy in the treatment of melasma, direct comparative evidence between these two delivery modalities remains limited, particularly with concurrent dermoscopic evaluation. Therefore, the present prospective randomized comparative study was undertaken to compare the clinical efficacy and dermoscopic outcomes of intradermal tranexamic acid and microneedling-assisted topical tranexamic acid in patients with melasma.

MATERIALS AND METHODS

Study design and participants

This prospective, randomized, comparative study was conducted in the Department of Dermatology, Venereology and Leprosy, Mysore medical college and research institute, Mysore, over a period of **6 months**. Written informed consent was obtained from all participants prior to enrolment.

A total of **60 patients** with clinically diagnosed melasma, aged **18–50 years**, of either sex, were enrolled and randomly allocated into two equal groups (30 patients each) using a computer-generated randomization schedule.

- **Group A:** Intradermal tranexamic acid (TXA)
- **Group B:** Microneedling-assisted topical tranexamic acid (TXA)

Inclusion criteria

- Patients aged 18–50 years.
- Clinically diagnosed melasma.

• Willingness to participate and comply with the study protocol.

Exclusion criteria

• Pregnant or lactating women.
• History of hypersensitivity to tranexamic acid.
• Patients receiving hormonal therapy or anticoagulants.
• History of thromboembolic disease or coagulation disorders.
• Active facial infection, inflammatory dermatoses, or keloidal tendency over the treatment area.
• Use of topical depigmenting agents, chemical peels, laser therapy, or systemic treatment for melasma within the preceding four weeks.

Baseline demographic characteristics, duration of melasma, precipitating factors, Fitzpatrick skin phototype, and clinical pattern of melasma (centrofacial, malar, or mandibular) were recorded.

Study procedure

A detailed history and clinical examination were performed at baseline. Standardized digital photographs were obtained under identical camera settings and lighting conditions. Disease severity was assessed using the Melasma Area and Severity Index (MASI), Investigator's Global Assessment (IGA), and Patient's Global Assessment (PGA) scales. Dermoscopic examination was performed using a DermLite DL5 dermoscope (3Gen Inc., San Juan Capistrano, CA, USA; ×10 magnification) to evaluate pigment distribution, pigment network, perifollicular pigmentation, and vascularity.

Before each treatment session, topical eutectic mixture of lidocaine(2.5% w/w) and prilocaine(2.5% w/w) [EMLA] cream was applied over the treatment area under occlusion for **60 minutes**, followed by cleansing with normal saline. A test dose of intradermal tranexamic acid was administered on the volar aspect of the forearm before the first treatment session, and patients were observed for 30 minutes for any immediate hypersensitivity reaction.

Group A: Intradermal tranexamic acid

12.5 mg/ml of tranexamic acid injection was prepared by adding 88 units of 0.9%Normal Saline to 12 units of tranexamic acid (100mg/ml), which is available in vials of 500mg per 5mL solution. Using a 1 mL insulin syringe (32G, 6mm), 0.1 mL of the diluted solution was injected intradermally at approximately 1 cm intervals throughout the melasma lesions to produce small wheals. Ice compresses were applied immediately after the procedure.

Group B: Microneedling-assisted topical tranexamic acid

Approximately 1 mL of 12.5 mg/mL tranexamic acid solution was applied uniformly over the melasma lesions. Microneedling was performed using a Dermapen fitted with a 12-pin disposable cartridge, making vertical, horizontal, and diagonal passes until uniform pinpoint bleeding was achieved. Tranexamic acid solution was reapplied and gently massaged over the treated area to facilitate enhanced transdermal drug delivery.

The subjects were observed for 2 hours post procedure and instructed to follow strict photo protective measures.

Both groups received treatment once weekly for 12 weeks. Throughout the study period, all patients were advised to avoid excessive sun exposure, apply and reapply a broad-spectrum tinted sunscreen (SPF 50), and refrain from using any additional topical or systemic depigmenting therapies.

Outcome assessment

Patients were evaluated at baseline and at 4, 8, and 12 weeks. The primary outcome measure was the change in the Melasma Area and Severity Index (MASI) score. Secondary outcome measures included the Investigator's Global Assessment (IGA), Patient Global Assessment (PGA), and dermoscopic findings. Standardized clinical photographs and dermoscopic images were obtained at each visit under identical camera settings and lighting conditions. Polarized dermoscopy was performed using a DermLite DL5 dermatoscope (3Gen Inc., San Juan Capistrano, CA, USA; ×10 magnification), and images were captured using an iPhone 15 Pro. For each patient, six dermoscopic images were obtained from the affected area under standardized conditions. Dermoscopic findings were interpreted and recorded according to previously described patterns in the literature. Dermoscopic images were systematically evaluated for the following pre-specified features: pseudoreticular enhancement (accentuation of the normal pseudoreticular pigmentary network corresponding to follicular openings and epidermal pigmentation), globules (discrete round-to-oval hyperpigmented structures), dots (small brownish pigmentary deposits), arcuate structures (curved pigmented streaks), perifollicular sparing (hypopigmented halos around follicular openings), and telangiectasias (fine linear or arborizing blood vessels). Treatment-related adverse effects, including pain, erythema, edema, burning sensation, post-inflammatory hyperpigmentation, infection, and other complications, were documented at every follow-up visit.

Statistical Analysis

The collected data were entered into Microsoft Excel and analyzed using Statistical Package for the Social Sciences (SPSS) software version 24.0 (IBM Corp., Armonk, NY, USA). Continuous

variables were expressed as mean ± standard deviation (SD), while categorical variables were expressed as frequencies and percentages. The normality of data distribution was assessed using the Shapiro–Wilk test. Between-group comparisons of continuous variables were performed using the independent-samples *t*-test for normally distributed data or the Mann–Whitney U test for non-normally distributed data, as appropriate. Categorical variables were analysed using the Chi-square test or Fisher's exact test, as appropriate. A *p*-value of <0.05 was considered statistically significant.

Results

A total of 60 patients were enrolled in the study, with 30 patients allocated to each treatment group. There were no statistically significant differences between Group A (intradermal tranexamic acid) and Group B (microneedling-assisted topical tranexamic acid) regarding age (30.93 ± 3.59 vs. 29.33 ± 3.99 years; $p = 0.108$), sex distribution ($p = 0.600$), diagnostic categories ($p = 0.915$), or baseline Investigator's Global Assessment (IGA) score (3.80 ± 0.71 vs. 3.97 ± 0.72; $p = 0.340$).

These findings indicate that the two treatment groups were comparable at baseline, ensuring an appropriate basis for subsequent comparison of treatment outcomes.

Table 1. Baseline Demographic and Clinical Characteristics of the Study Participants

Variable	Group A (Intradermal TXA) (n = 30)	Group B (Microneedling-assisted Topical TXA) (n = 30)	p value
Age (years), Mean ± SD	30.93 ± 3.59	29.33 ± 3.99	0.108
Male, n (%)	11 (36.7)	14 (46.7)	
Female, n (%)	19 (63.3)	16 (53.3)	0.600
Baseline MASI score, Mean ± SD	8.52 ± 0.68	8.66 ± 0.66	0.410
Baseline IGA score, Mean ± SD	3.80 ± 0.71	3.97 ± 0.72	0.340

Values are presented as mean ± standard deviation (SD) or number (percentage). Continuous variables were compared using the independent-samples *t*-test. Categorical variables were compared using the Chi-square test or Fisher's exact test, as appropriate. A *p*-value <0.05 was considered statistically significant.

The mean baseline MASI scores were comparable between Group A and Group B (8.52 ± 0.68 vs. 8.66 ± 0.66; $p = 0.410$), indicating similar disease severity before treatment. (Table 2). Both treatment groups showed a progressive reduction in mean MASI scores over the 12-week follow-up period. Between-group comparisons showed significantly lower mean MASI scores in Group A than in Group B from Week 4 onward (all $p < 0.001$). At Week 12, the mean MASI score was 3.46 ± 1.26 in Group A compared with 5.99 ± 0.42 in Group B, indicating greater clinical improvement with intralesional tranexamic acid. Representative clinical photographs demonstrating treatment response in both groups are shown in Figure 2.



Figure 3. Representative before-and-after clinical photographs of melasma following 12 weeks of treatment: (3A) before and (3B) after intradermal tranexamic acid; (3C) before and (3D) after microneedling-assisted topical tranexamic acid.

Table 2. Comparison of Mean Melasma Area and Severity Index (MASI) Scores Between the Two Treatment Groups During Follow-up

Time Point	Group A (Intralesional TXA) Mean ± SD	Group B (Microneedling + Topical TXA) Mean ± SD	p value
Baseline	8.52 ± 0.68	8.66 ± 0.66	0.410
Week 4	7.18 ± 0.70	8.07 ± 0.52	<0.001
Week 8	5.64 ± 1.02	7.17 ± 0.48	<0.001
Week 12	3.46 ± 1.26	5.99 ± 0.42	<0.001

Values are presented as mean ± standard deviation (SD). Between-group comparisons were performed using the independent-samples *t*-test. A *p*-value <0.05 was considered statistically significant.

The mean baseline Investigator's Global Assessment (IGA) scores were comparable between Group A and Group B (3.80 ± 0.71 vs. 3.97 ± 0.72; $p = 0.340$), indicating similar baseline clinical severity (Table 3). Both treatment groups showed progressive reductions in mean IGA scores throughout the 12-week follow-up period. Between-group comparisons revealed significantly lower mean IGA scores in Group A than in Group B from Week 4 onward (all $p < 0.001$). By Week 12, the mean IGA score had decreased to **0.97 ± 0.67** in Group A compared with **2.10 ± 0.61** in Group B, indicating greater clinical improvement with intralesional tranexamic acid.

Table 3. Comparison of Mean Investigator's Global Assessment (IGA) Scores Between the Two Treatment Groups During Follow-up

Time Point	Group A (Intralesional TXA) Mean ± SD	Group B (Microneedling + Topical TXA) Mean ± SD	p value
Baseline	3.80 ± 0.71	3.97 ± 0.72	0.340
Week 4	2.87 ± 0.63	3.63 ± 0.56	<0.001
Week 8	1.90 ± 0.66	2.93 ± 0.64	<0.001
Week 12	0.97 ± 0.67	2.10 ± 0.61	<0.001

Values are presented as mean ± standard deviation (SD). Between-group comparisons were performed using the independent-samples *t*-test. A *p*-value <0.05 was considered statistically significant.

Representative serial dermoscopic images illustrating the progressive therapeutic regression of melasma are shown in Figure 4. Image **A** demonstrates dense brown pseudoreticular pigmentation with numerous fine pigmented dots and a confluent reticular architecture. Image **B** shows partial regression characterized by attenuation of the pseudoreticular network, reduced pigment density, and increasing areas of intervening normal skin. Image **C** depicts near-complete dermoscopic clearance with marked loss of the reticular pigmentation pattern and only minimal residual focal pigmentation.

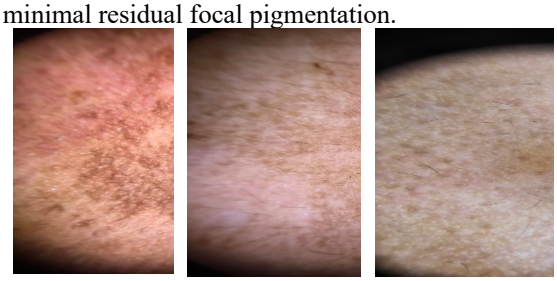

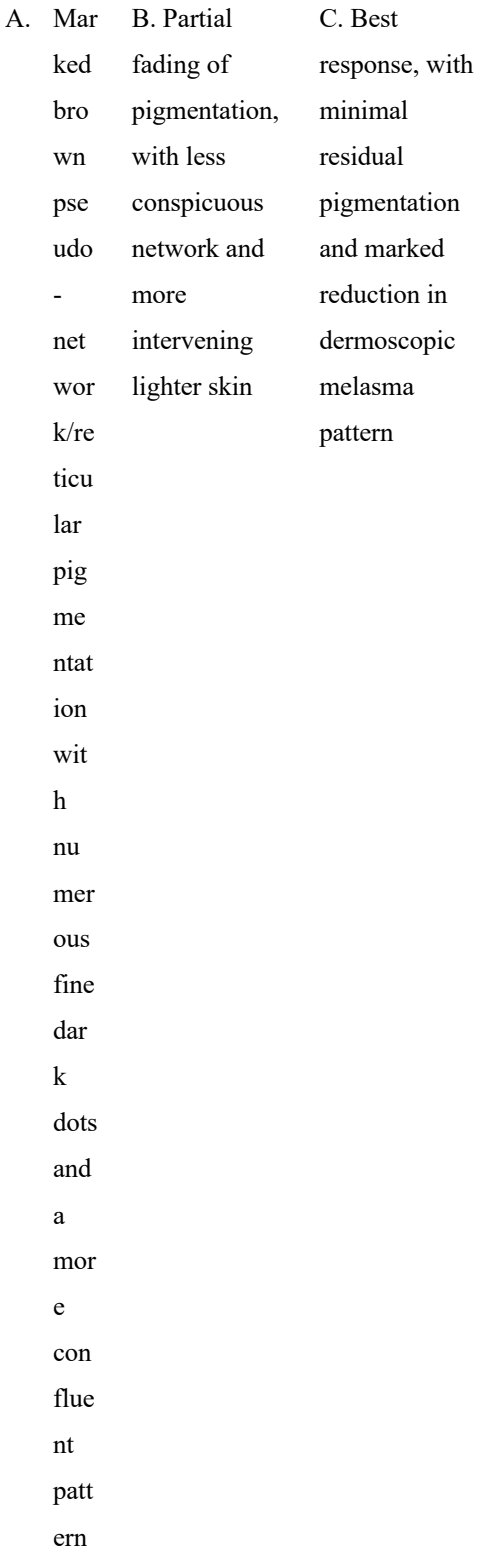

Figure 4 Representative serial dermoscopic images demonstrating progressive therapeutic regression of melasma following treatment. From left to right, there is sequential attenuation of the brown pseudoreticular pigment network, reduction in pigment density, restoration of normal background skin, and near-complete dermoscopic clearance.

Patient Global Assessment (PGAS) scores differed significantly between the two treatment groups ($p = 0.008$). A higher proportion of patients in Group A reported excellent or very good improvement compared with Group B (66.7% vs. 26.7%). In contrast, fair or poor/no improvement responses were more frequently observed in Group B (30.0%) than in Group A (6.7%), indicating greater patient satisfaction with intralesional tranexamic acid.

Table 5. Comparison of Patient Global Assessment (PGAS) Between the Two Treatment Groups

Patient Global Assessment	Group A n (%)	Group B n (%)	Fisher's exact *p* value
Excellent	9 (30.0)	2 (6.7)	0.042
Very good	11 (36.7)	6 (20.0)	0.252
Good	8 (26.7)	13 (43.3)	0.279
Fair	2 (6.7)	8 (26.7)	0.080
Poor/No improvement	0 (0.0)	1 (3.3)	1.000
Overall comparison	30 (100)	30 (100)	0.008

Values are presented as number (percentage). Between-group comparison was performed using the Chi-square test. A p value <0.05 was considered statistically significant.

Both treatment modalities were generally well tolerated. Pain at the treatment site was the most common adverse effect in **Group A** (26.7%), whereas erythema (20.0%) and burning sensation (23.3%) were reported more frequently in **Group B**. No adverse effects were observed in **63.3%** of patients in Group A compared with **40.0%** in Group B. The overall distribution of treatment-related adverse effects differed significantly between the two groups ($p = 0.031$).

Table 6. Comparison of Treatment-related Adverse Effects Between the Two Treatment Groups

Adverse Effect	Group A (Intradermal TXA) n (%)	Group B (Microneedling + Topical TXA) n (%)	*p* value
Pain	8 (26.7)	3 (10.0)	0.181
Erythema	2 (6.7)	6 (20.0)	0.254
Burning sensation	1 (3.3)	7 (23.3)	0.052
Edema	0 (0.0)	2 (6.7)	0.492
No adverse effects	19 (63.3)	12 (40.0)	0.120
Overall comparison			0.031

Values are presented as number (percentage). Overall between-group comparison was performed using the Chi-square test. A *p*-value <0.05 was considered statistically significant.

Discussion

Melasma is a chronic acquired hyperpigmentary disorder with a multifactorial pathogenesis involving pigmentary, vascular, and inflammatory mechanisms. Tranexamic acid has emerged as an effective treatment by inhibiting the plasminogen–plasmin pathway, thereby reducing melanogenesis and VEGF-mediated angiogenesis **(5,6).**

In the present study, both treatment groups were comparable with respect to age, sex, diagnosis, and baseline disease severity, ensuring reliable comparison of treatment outcomes. These findings are consistent with those reported by **Agrawal et al. (13).**

Both treatment modalities resulted in significant clinical improvement; however, intradermal tranexamic acid produced significantly greater reductions in MASI and IGA scores than microneedling-assisted topical tranexamic acid. Similar results were reported by **Agrawal et al. (13)**, who also demonstrated superior clinical efficacy with intradermal tranexamic acid. This greater efficacy is likely attributable to direct dermal delivery, resulting in higher local drug concentrations and more effective inhibition of melanogenesis and angiogenesis.

Dermoscopic assessment also showed significantly greater improvement in the intradermal tranexamic acid group. These findings agree with **Sarah et al. (11)**, who demonstrated marked improvement in dermoscopic pigmentation and vascular features following intradermal tranexamic acid therapy and highlighted dermoscopy as an objective tool for monitoring treatment response. **Sonthalia and Sarkar (10)** also emphasized the value of dermoscopy in identifying characteristic pigmentary and vascular features of melasma and in evaluating treatment response.

The serial dermoscopic images in the present study demonstrated progressive attenuation of the brown pseudoreticular pigment network, reduction in pigment density, restoration of normal background skin, and near-complete dermoscopic clearance by week 12. Similar sequential dermoscopic changes have been described in the literature, supporting the role of serial dermoscopy as a reliable, non-invasive, and objective method for monitoring therapeutic response in melasma **(10,11).**

Patient Global Assessment scores were significantly better in the intradermal tranexamic acid group, indicating greater patient satisfaction. This finding is consistent with the reports of **Agrawal et al. (13)** and **Sarah et al. (11)** and likely reflects the superior clinical and dermoscopic improvement achieved with intradermal treatment.

Both treatment modalities were well tolerated, with only mild and self-limiting adverse effects. Pain was more frequent after intradermal tranexamic acid, whereas erythema and burning sensation occurred more commonly following microneedling-assisted topical tranexamic acid. Similar observations were reported by **Agrawal et al. (13)**, and no serious adverse events were encountered.

The strengths of this study include its prospective comparative design, relatively larger sample size than previous comparative studies, and comprehensive assessment using MASI, IGA, serial dermoscopic evaluation, Patient Global Assessment, and adverse-effect monitoring. However, the study was limited by its single-center design and short follow-up period, which precluded assessment of long-term efficacy and recurrence. Further multicenter studies with larger sample sizes and longer follow-up are required to validate these findings and establish the long-term comparative efficacy and safety of intradermal tranexamic acid and microneedling-assisted topical tranexamic acid in the management of melasma.

Conclusion

Both intradermal tranexamic acid and microneedling-assisted topical tranexamic acid were effective in the treatment of melasma. However, intradermal tranexamic acid demonstrated significantly greater clinical and dermoscopic improvement, higher patient satisfaction, and an acceptable safety profile. These findings suggest that intradermal tranexamic acid is a more effective therapeutic option for melasma. Further

studies with larger sample sizes and longer follow-up are needed to confirm its long-term efficacy and recurrence rates.

1. Passeron T, Picardo M. Melasma, a photoaging disorder. *Pigment Cell Melanoma Res.* 2018;31(4):461-465.

2. Ogbechie-Godec OA, Elbuluk N. Melasma: an up-to-date comprehensive review. *Dermatol Ther (Heidelb).* 2017;7(3):305-318.

3. Rodrigues M, Pandya AG. Melasma: clinical diagnosis and management options. *Australas J Dermatol.* 2015;56(3):151-163.

4. Sarkar R, Arora P, Garg VK, Sonthalia S, Gokhale N. Melasma update. *Indian Dermatol Online J.* 2014;5(4):426-435.

5. Kwon SH, Hwang YJ, Lee SK, et al. Heterogeneous pathology of melasma and its clinical implications. *Int J Mol Sci.* 2016;17(6):824.

6. Sarma N, Chakraborty S, Poojary SA, et al. Evidence-based review, grade of recommendation, and suggested treatment recommendations for melasma. *Indian Dermatol Online J.* 2017;8(6):406-442.

7. Lee HC, Thng TGS, Goh CL. Oral tranexamic acid in the treatment of melasma: a retrospective analysis. *J Am Acad Dermatol.* 2016;75(2):385-392.

8. Na JI, Choi SY, Yang SH, et al. Effect of tranexamic acid on melasma: a clinical trial with histological evaluation. *J Eur Acad Dermatol Venereol.* 2013;27(8):1035-1039.

9. Budamakuntla L, Loganathan E, Suresh DH, Shanmugam S, Suryanarayan S, Dongare A, et al. A randomized, open-label, comparative study of tranexamic acid microinjections and tranexamic acid with microneedling in patients with melasma. *J Cutan Aesthet Surg.* 2013;6(3):139-143.

10. Sonthalia S, Jha AK, Langar S. Dermoscopy of melasma. *Indian Dermatol Online J.* 2017;8(6):525-526.

11. Sarah OTB, Tawfik AA, Soliman M, Shaarawy E, Abdallah N. A dermoscopic evaluation of melasma treated with tranexamic acid. *Open Access Maced J Med Sci.* 2022;10(B):1686-1691.

12. Pandya AG, Hynan LS, Bhore R, et al. Reliability assessment and validation of the Melasma Area and Severity Index (MASI) and a modified MASI scoring system. *J Am Acad Dermatol.* 2011;64(1):78-83.

13. Agrawal B, Anand JB, Priyadarsini NP, Saravanan N. To study the efficacy and safety of intralesional tranexamic acid vs microneedling with topical tranexamic acid in facial melanosis: a randomised comparative study from a tertiary care centre. *IP Indian J Clin Exp Dermatol.* 2025;11(4):562-566.