RESEARCH PAPER

Schwannoma and Neurofibroma of the Posterior Tibial Nerve Presenting as Tarsal Tunnel Syndrome: A Case Series

Dr. Darshansingh Rajput[1], Dr Apoorva Reddy B V[2*]
[1]*M. Ch Plastic Surgery, Department of Plastic surgery, Jawaharlal Nehru Medical College, Belagavi*
[2]*Senior resident, Dept of Plastic surgery, Jawaharlal Nehru Medical College, Belagavi*

ABSTRACT

Background Tarsal tunnel syndrome (TTS) is an entrapment neuropathy of the tibial nerve within the tarsal tunnel. Although a variety of intrinsic and extrinsic factors may cause TTS, peripheral nerve sheath tumours are uncommon structural causes. Schwannomas and neurofibromas involving the posterior tibial nerve may produce symptoms that mimic other causes of tarsal tunnel syndrome and can therefore be diagnosed late.

Objective To describe the clinical presentation, radiological findings, surgical management, histopathological characteristics, and postoperative outcomes of four patients with posterior tibial nerve schwannoma or neurofibroma presenting as TTS.

Methods A retrospective review was performed of four patients with histo-pathologically confirmed peripheral nerve sheath tumours involving the posterior tibial nerve and presenting with clinical features of TTS. Clinical presentation, examination findings, magnetic resonance imaging (MRI), operative findings, histopathology, and postoperative outcomes were reviewed.

Results Four patients were identified, comprising two patients with schwannoma and two with neurofibroma. All patients presented with foot and/or ankle pain, paraesthesia, and a positive Tinel's sign over the tarsal tunnel. MRI demonstrated a focal lesion within the tarsal tunnel in all four patients. All patients underwent surgical tumour excision with tarsal tunnel decompression and nerve-preserving dissection. Histopathological examination confirmed two schwannomas and two neurofibromas. The schwannoma specimens demonstrated Antoni A and Antoni B areas, while the neurofibroma specimens demonstrated loosely scattered spindle cells. Complete resolution of presenting symptoms was documented in all four patients during the available postoperative follow-up, with preserved nerve function and no documented postoperative complications.

Conclusion Peripheral nerve sheath tumours should be considered in the differential diagnosis of TTS, particularly when a focal lesion is identified on imaging. MRI can help identify and anatomically localize structural causes of TTS. Surgical excision combined with adequate decompression and careful preservation of neural structures can provide favourable symptomatic outcomes.

Keywords: tarsal tunnel syndrome; posterior tibial nerve; schwannoma; neurofibroma; peripheral nerve sheath tumour; nerve compression; foot and ankle

How to cite this article: Dr. Darshansingh Rajput, Dr Apoorva Reddy B V, Schwannoma and Neurofibroma of the Posterior Tibial Nerve Presenting as Tarsal Tunnel Syndrome: A Case Series, International Journal of Drug Delivery Technology, 2026;16(90s):904-907. DOI: 10.25258/ijddt.16.90s.89

Source of support: Nil.

Conflict of interest: None

INTRODUCTION

Tarsal tunnel syndrome is an entrapment neuropathy of the tibial nerve within the tarsal tunnel at the ankle. Diagnosis can be challenging because symptoms may overlap with other peripheral nerve and musculoskeletal disorders, and electrodiagnostic testing is not invariably diagnostic. The causes of TTS are diverse and include structural lesions within or around the tunnel.[1,2]

Imaging, particularly magnetic resonance imaging, can help identify structural causes of TTS and define their relationship to the tibial nerve and surrounding anatomy.[3]

Peripheral nerve sheath tumours are uncommon causes of TTS. Schwannomas are benign tumours arising from Schwann cells and are usually well circumscribed, whereas neurofibromas are benign peripheral nerve sheath tumours with distinct histopathological and anatomical characteristics.[4]

Posterior tibial nerve schwannomas presenting as TTS have been described in individual case reports and small series. Nawabi et al reported 25 patients with posterior tibial nerve schwannomas and highlighted the potential for prolonged diagnostic delay; all patients had pain and a Tinel's sign, and MRI confirmed the diagnosis in the cases in which it was performed.[5] Other reports have described individual posterior tibial nerve schwannomas producing TTS symptoms and treated surgically with favourable outcomes.[6–9]

Tladi et al. specifically reported two cases of peripheral nerve tumours presenting as TTS, comprising a schwannoma and a neurofibroma of the posterior tibial nerve.[10] A case report by El Hassani et al described posterior tibial nerve neurofibroma presenting as TTS in a 15-year-old girl.[11] More recently, Verly et al reported three cases of distal-leg posterior tibial nerve schwannomas associated with TTS, while de Ruiter et al. reported a 40-patient series of schwannomas involving the tibial, plantar, or medial calcaneal nerves around the ankle.[12,13]

The present case series describes four patients with posterior tibial nerve peripheral nerve sheath tumours presenting as TTS, comprising two schwannomas and two neurofibromas. The clinical presentation, imaging findings, surgical treatment, histopathology, and postoperative outcomes are presented.

Materials and Methods

Study Design

This retrospective case series included four patients with histopathologically confirmed peripheral nerve sheath tumours involving the posterior tibial nerve and presenting with clinical features of TTS.

Clinical records, radiological investigations, operative documentation, histopathological reports, and postoperative follow-up records were reviewed.

Clinical Assessment

The presenting symptoms and available clinical examination findings were recorded.

All four patients had:

Foot and/or ankle pain

Paraesthesia

Positive Tinel's sign over the tarsal tunnel

Insidious onset of symptoms

Individual electrodiagnostic findings were not available for inclusion in the present analysis.

Radiological Assessment

MRI was performed in all four patients. The lesions were identified within the tarsal tunnel and were described as focal, well-defined, T2-hyperintense lesions.

MRI is useful in the evaluation of TTS because it can identify structural abnormalities and assist in defining their relationship to the tibial nerve and adjacent structures.[3]

Surgical Management

All patients underwent surgical excision of the tumour combined with tarsal tunnel decompression.

The tumour was identified in relation to the posterior tibial nerve and dissected with the objective of preserving functioning neural tissue.

Histopathological Assessment

All excised lesions underwent histopathological examination.

Two lesions were diagnosed as schwannomas and two as neurofibromas.

The schwannoma specimens demonstrated Antoni A and Antoni B areas. The neurofibroma specimens demonstrated loosely scattered spindle cells.

The histological distinction between schwannoma and neurofibroma is well established within the spectrum of peripheral nerve sheath tumors.[4]

Immunohistochemical findings were not available in the case material and are therefore not reported.

Outcome Assessment

Postoperative outcomes were assessed according to symptom resolution, preservation of nerve function, and documented postoperative complications.

Complete resolution of presenting symptoms was documented in all four patients during the available follow-up period.

Results

Four patients were included in the series.

Two patients had schwannoma and two had neurofibroma of the posterior tibial nerve.

All patients presented with foot and/or ankle pain, paraesthesia, and a positive Tinel's sign over the tarsal tunnel. Symptoms had an insidious onset.

MRI demonstrated focal lesions within the tarsal tunnel in all four patients.

All patients underwent tumour excision combined with tarsal tunnel decompression. Surgical dissection was performed with preservation of the involved nerve wherever feasible.

Histopathology confirmed two schwannomas and two neurofibromas. The schwannomas demonstrated Antoni A and Antoni B areas, whereas the neurofibromas demonstrated loosely scattered spindle cells.

Complete resolution of presenting symptoms was documented in all four patients. Nerve function remained preserved, and no postoperative complications were documented in the available follow-up.

Table 1. Clinical characteristics and outcomes

Parameter	Case 1	Case 2	Case 3	Case 4
Age	25 years	31 years	16 years	12 years
Sex	Male	Male	Female	Female
Diagnosis	Schwannoma	Schwannoma	Neurofibroma	Neurofibroma
Foot/ankle pain	Present	Present	Present	Present
Paraesthesia	Present	Present	Present	Present
Tinel's sign	Positive	Positive	Positive	Positive
Onset	Insidious	Insidious	Insidious	Insidious
MRI	Focal T2-hyperintense lesion	Focal T2-hyperintense lesion	Focal T2-hyperintense lesion	Focal T2-hyperintense lesion
Treatment	Excision + decompression	Excision + decompression	Excision + decompression	Excision + decompression
Histopathology	Schwannoma	Schwannoma	Neurofibroma	Neurofibroma
Sympto	Comple	Comple	Comple	Comple

m outcom e	te resoluti on	te resoluti on	te resoluti on	te resoluti on
Nerve function	Preserv ed	Preserv ed	Preserv ed	Preserv ed
Docume nted complic ations	None	None	None	None

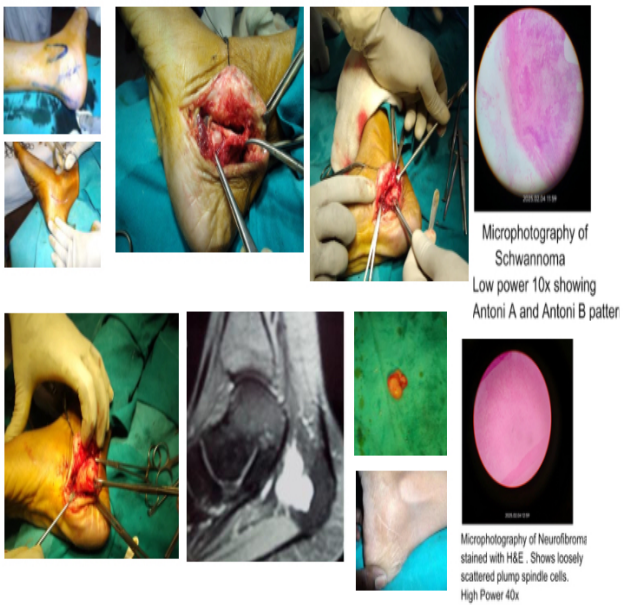

Discussion

Peripheral nerve sheath tumours are uncommon but clinically important structural causes of TTS. Their slow growth and overlapping neuropathic symptoms may result in delayed diagnosis. This has been demonstrated particularly clearly in posterior tibial nerve schwannomas.[5],[6],[10]

In the present series, all four patients presented with pain, paraesthesia, and a positive Tinel's sign over the tarsal tunnel. These findings are compatible with the clinical manifestations described in the literature on TTS and posterior tibial nerve tumours.[1],[2],[5]

Schwannoma

Schwannomas of the posterior tibial nerve are rare but have been repeatedly reported as causes of TTS.

Nawabi et al described 25 patients with posterior tibial nerve schwannomas. All patients reported pain, a Tinel's sign was present in all cases, and MRI confirmed the diagnosis in all cases in which MRI had been performed. The mean delay to diagnosis was 86.5 months, demonstrating the potential for prolonged diagnostic delay. Surgical resection abolished neuropathic pain in their series.[5]

Boya et al. described a posterior tibial nerve neurilemoma within the tarsal tunnel in a 20-year-old patient with posteromedial ankle pain. MRI demonstrated a mass adjacent to the posterior tibial nerve, and surgical excision confirmed a schwannoma histologically.[6]

Milnes et al reported another posterior tibial nerve schwannoma causing TTS, with an eight-year delay in diagnosis.[7] Hallahan et al. described a large posterior tibial nerve schwannoma at the posteromedial ankle; the lesion was marginally excised without motor deficit, although early subjective numbness was reported.[8] Judd et al. described a schwannoma arising from a branch of the posterior tibial nerve in the tarsal tunnel region.[9]

These reports support the importance of considering schwannoma when patients have persistent neuropathic symptoms localized to the distribution of the posterior tibial nerve, particularly when a focal lesion is present.

Neurofibroma

Neurofibroma of the posterior tibial nerve producing TTS appears to be substantially less frequently reported.

Tladi et al. described two peripheral nerve tumours presenting as TTS, including a posterior tibial nerve neurofibroma.[10] El Hassani et al. subsequently described a 15-year-old girl with TTS caused by a posterior tibial nerve neurofibroma, initially diagnosed as plantar fasciitis and S1 radiculopathy.[11]

The presence of two neurofibromas in the present series therefore adds further clinical experience with this uncommon presentation.

The available case information does not establish an underlying neurofibromatosis syndrome in the present patients; consequently, no association with neurofibromatosis is inferred.

Role of MRI

MRI demonstrated the lesions in all four patients in the present series.

MRI is useful in TTS because it can identify causative structural abnormalities and assist with surgical planning.[3] In peripheral nerve tumours, MRI may demonstrate a focal lesion and its relationship to the parent nerve, although definitive tumour classification remains histopathological.

The combination of clinical examination and imaging is therefore particularly useful when symptoms are persistent, atypical, or associated with a palpable or radiological mass.

Surgical Management

The principal objective of surgery in a symptomatic peripheral nerve sheath tumour is removal of the causative lesion while preserving functioning nerve fascicles.

Published case reports of posterior tibial nerve schwannomas have generally described favourable outcomes following tumour excision.[5–9]

Verly et al reported three distal-leg posterior tibial nerve schwannomas associated with TTS. All patients underwent tumour resection and tarsal tunnel decompression. Complete tumour resection was achieved in all three patients, with transient sensory deterioration in one patient and no motor complications. Pain resolved completely in two patients and partially in one at final follow-up.[12]

In the present series, all four patients underwent tumour excision with tarsal tunnel decompression, and complete resolution of presenting symptoms was documented in all four patients with preserved nerve function.

The favourable outcome in the present series is encouraging, although the small sample size and retrospective nature of the study preclude conclusions regarding treatment efficacy beyond these individual cases.

Clinical implications

The findings from this series emphasize that a diagnosis of TTS should not necessarily be regarded as idiopathic when clinical findings suggest a focal lesion. In particular, the combination of persistent neuropathic symptoms, a positive Tinel sign and a focal lesion on MRI should raise suspicion for a peripheral nerve sheath tumour.

Recognition of the lesion before surgery is important because the operative strategy differs from that used for nonspecific decompression alone. Identification of the tumour and its relationship to the tibial nerve allows appropriate planning for decompression and careful tumour excision with preservation of functioning neural structures

Limitations

This study has several limitations.

The sample size is small, consisting of only four patients.

The study is retrospective and descriptive.

Standardized outcome measures such as validated pain scores, functional scores, and electrodiagnostic parameters were not available for all patients.

Immunohistochemical studies was not done.

Conclusion

Posterior tibial nerve schwannomas and neurofibromas are uncommon causes of tarsal tunnel syndrome but should be considered in the differential diagnosis of patients with persistent neuropathic symptoms, particularly when a focal lesion is identified.

In this four-patient series, two patients had schwannoma and two had neurofibroma. All patients presented with pain, paraesthesia, and a positive Tinel's sign. MRI demonstrated focal lesions within the tarsal tunnel, and histopathology confirmed the diagnosis.

Surgical excision combined with tarsal tunnel decompression resulted in complete resolution of presenting symptoms in all four patients, with preserved nerve function and no documented postoperative complications.

Recognition of a peripheral nerve sheath tumour as the underlying cause of TTS permits targeted surgical management and may prevent prolonged diagnostic delay.

References

1. Haq II, Banerjee AA, Arshad Z, Iqbal AM, Bhatia M. The management of tarsal tunnel syndrome: a scoping review. *J Clin Orthop Trauma*. 2024;54:102489. doi:10.1016/j.jcot.2024.102489.
2. Sha I. Tarsal Tunnel Syndrome—A Comprehensive Review. *Iowa Orthop J*. 2024;44(2):32-36. PMID:39811161.
3. Khodatars D, Gupta A, Welck M, Saifuddin A. An update on imaging of tarsal tunnel syndrome. *Skeletal Radiol*. 2022;51(11):2075-2095. doi:10.1007/s00256-022-04072-y. PMID:35562562.
4. Magro G, Broggi G, Angelico G, Puzzo L, Vecchio GM, Virzì V, et al. Practical approach to histological diagnosis of peripheral nerve sheath tumors: an update. *Diagnostics (Basel)*.2022;12(6):1463. doi:10.3390/diagnostics12061463. PMID:35741273.
5. Nawabi DH, Sinisi M. Schwannoma of the posterior tibial nerve: the problem of delay in diagnosis. *J Bone Joint Surg Br*. 2007;89(6):814-816. doi:10.1302/0301-620X.89B6.19077. PMID:17613510.
6. Boya H, Ozcan O, Oztekin HH. Tarsal tunnel syndrome associated with a neurilemoma in posterior tibial nerve: a case report. *Foot (Edinb)*. 2008;18(3):174-177. doi:10.1016/j.foot.2008.05.006.PMID:20307434.
7. Milnes HL, Pavier JC. Schwannoma of the tibial nerve sheath as a cause of tarsal tunnel syndrome—a case study. *Foot (Edinb)*. 2012;22(3):243-246. doi:10.1016/j.foot.2012.03.005. PMID:22560193.
8. Hallahan K, Vinokur J, Demski S, Faulkner-Jones B, Giurini J. Tarsal tunnel syndrome secondary to schwannoma of the posterior tibial nerve. *J Foot Ankle Surg*. 2014;53(1):79-82. doi:10.1053/j.jfas.2012.12.020. PMID:23954095.
9. Judd T, Jones T, Thornberry L. Schwannoma of the posterior tibial nerve: case study. *J Am Podiatr Med Assoc*. 2014;104(5):539-543. doi:10.7547/0003-0538-104.5.539. PMID:25275747.
10. Tladi MJ, Saragas NP, Ferrao PN, Strydom A. Schwannoma and neurofibroma of the posterior tibial nerve presenting as tarsal tunnel syndrome: review of the literature with two case reports. *Foot (Edinb)*. 2017;32:22-26. doi:10.1016/j.foot.2017.03.005. PMID:28624667.
11. El Hassani A, Douma H, Barchah O, Elkasseh M, Boumaiz A, Belkyal S, et al. An unusual cause of tarsal tunnel syndrome in a 15-year-old girl: about a case. *Pan Afr Med J*. 2022;42:86. doi:10.11604/pamj.2022.42.86.35186. PMID:36034033.
12. Verly G, Acioly MA. Distal leg posterior tibial nerve schwannomas combined with tarsal tunnel syndrome: a case series and literature review. *Cureus*. 2025;17(2):e79356. doi:10.7759/cureus.79356. PMID:40125172.

13. de Ruiter GCW, Hayford KM, Vissers TFH, Spinner RJ. Surgical treatment of schwannomas around the tarsal tunnel: a case series of 40 patients and systematic review of the literature. *J Neurosurg*. 2026. doi:10.3171/2026.1.JNS252605. PMID:42398116.