RESEARCH PAPER

Tenosynovitis of Forearm and Hand - A Case Series

[1]Dr. Darshansingh. U. Rajput M.S, M. Ch,[2*]Dr. Anusha Nagendra Bhat M.B.B.S, M.S and [3]Dr. Rajesh S. Powar M.S, M. Ch

[1]Professor & Head, Department of Plastic & Reconstructive Surgery J. N. Medical College, KAHER, Belagavi – 590010 Karnataka, India
[2]Senior Resident, Department of Plastic & Reconstructive Surgery J. N. Medical College, KAHER, Belagavi -590010 Karnataka, India
[3]Professor & Principal, Department of Plastic & Reconstructive Surgery J. N. Medical College, KAHER, Belagavi – 590010 Karnataka, India
[1]docrajput@gmail.com, [2]anushabhat2@gmail.com and [3]drrajeshpowar@gmail.com
***Corresponding Author:** docrajput@gmail.com*

Received: 14th June, 2026; Revised: 20th July 2026; Accepted: 20th August, 2026; Available Online: 05th September 2026

ABSTRACT
Tubercular tenosynovitis is a rare presentation of musculoskeletal tuberculosis. Its indolent course and non-specific symptoms often delay diagnosis.

The main objective is to comprehensively evaluate the clinical presentation, diagnostic methods, treatment protocols, and patient outcomes in five cases of tubercular tenosynovitis providing a detailed analysis of each aspect. This retrospective case series included five patients who presented with chronic tenosynovitis between 2020 and 2024. Each patient underwent MRI, laboratory investigations, and tissue sampling. Diagnosis was confirmed through histopathology, CBNAAT, or culture.

All patients presented with chronic swelling (3–12 months). MRI showed synovial hypertrophy and rice bodies in most cases. Histopathology confirmed granulomatous inflammation in all. All patients required synovectomy, and were managed with ATT. All patients recovered completely with no recurrence at follow-up. Tubercular tenosynovitis should be considered in cases of persistent tenosynovitis that do not respond to conventional treatments, particularly in patients from TB - endemic regions or with known risk factors . Combined medical and surgical management ensures excellent outcomes.

Keywords: Tuberculosis, Tenosynovitis, Rice bodies, Synovectomy.

How to cite this article: Rajput DU, Bhat AN, Powar RS, Tenosynovitis of Forearm and Hand - A Case Series Int J Drug Deliv Technol. 2026;16(90s): 918-922; DOI: 10.25258/ijddt.16.90s.91
Source of support: Nil.
Conflict of interest: None

INTRODUCTION

Tuberculosis remains a major global public health issue, particularly in endemic countries like India. Extra pulmonary TB accounts for only 20% of all TB cases, with musculoskeletal TB occurring in about 2-5% [1]. Tubercular tenosynovitis, a rare subtype that involves the tendon sheaths of the wrist, hand, and foot[2].

The disease progresses slowly, and patients often remain asymptomatic for months. In early stages, it is commonly misdiagnosed as rheumatoid arthritis, De Quervain's disease, ganglion, or pyogenic infection[3]. Early suspicion and timely management are essential to prevent complications such as tendon rupture, joint destruction, and functional disability[4].

This series presents five cases, selected to highlight the diverse clinical presentations and the critical role of imaging and histopathology in diagnosing tubercular tenosynovitis, there by contributing to the understanding of this rare condition.

AIM AND OBJECTIVES

1. To document the clinical presentation of tubercular tenosynovitis.
2. To evaluate radiological, laboratory, and pathological findings.
3. To assess outcomes following ATT and surgical synovectomy.
4. To increase awareness of early diagnostic markers.

MATERIALS AND METHODS

This retrospective observational case series of 5 confirmed cases was conducted at the plastic and reconstructive surgery department of Jawaharlal Nehru medical college KAHER Belagavi between January 2020 and December 2024. All the patients had Clinical swelling >3 weeks, MRI/USG features of tenosynovitis and

**Author for Correspondence: docrajput@gmail.com*

Confirmatory histopathology or microbiology. All the patients underwent surgical exploration + synovectomy. Tissue samples were sent for histopathology, CBNAAT, AFB staining and culture. Category based anti-tubercular therapy was given for 9-12 months. Patients were followed up regularly at 1, 3, 6, 9, and 12 months.

Case 1:
A 57-year-old male presented with swelling on the volar aspect of the left forearm, accompanied by tingling sensation in the thumb, index, and middle fingers of the left hand for the past year. The swelling was associated with pain and stiffness of the wrist. The patient had no history of diabetes mellitus, TB, or other known comorbidities.

On examination, there was swelling on the volar aspect of the left distal third of the forearm, oval in shape, immobile, nontender, noncompressible, and nonfluctuant. The skin over the swelling was pinchable. His complete blood picture was within normal limits. Magnetic resonance imaging (MRI) of the wrist showed a well defined, peripherally enhancing T2 hypo-intense cystic area, measuring 4.4 (AP) x 6.2 (ML) x 10.5 (CC) cms with internal synovial thickening and nodularity around the distal half of flexor digitorum superficialis with diffusely enhancing synovial thickening extending along the tendons of the flexor compartment.

The patient underwent exploration and excision biopsy of the tenosynovium. Intraoperatively, there was a spindle-shaped thickened synovial sheath completely engulfing the FDS tendons. The thickened synovium was excised. Excised tissue was sent to histopathology, and microbiological investigations such as Gram stain, aerobic bacterial culture and sensitivity, Ziehl–Neelsen acid-fast staining and CBNAAT. Histopathology revealed epithelioid granuloma with multinucleate giant cells, synovial tissue with hyalinization, and fibrosis suggestive of granulomatous tenosynovitis. Likely, Koch's etiology was opined. CBNAAT was positive.

The patient was started on antitubercular therapy (ATT) based on weight and followed up regularly. symptoms subsided immediately after surgery and there was no recurrence of swelling or carpal tunnel symptoms at the last follow-up (2 years till date). Pain and stiffness in the wrist had significantly subsided.

All patients underwent thorough surgical exploration + synovectomy. A Category based anti tubercular therapy was given for 9-12 months tailored to each patient's response and recovery progress. Patients were followed up regularly at 1, 3, 6, 9 and 12 months and 2 years. Hand function was measured using Garland and Werley score. Flexion, ulnar and radian deviation, pronation and supination , grip strength were assessed. Results were good to excellent after 1 year follow up.

DISCUSSION

Tuberculosis is endemic in India . Extra pulmonary TB accounts for only 20% of all cases with musculoskeletal TB occurring in about 2-5% [1]. Upper limb involvement is rare for musculoskeletal TB, most commonly affecting flexor side and ulnar border. Risk factors include male gender, dominant hand involvement, hand overuse, low socioeconomic status , malnutrition and immunosuppression. Our patients exhibited these risk factors.

Tubercular involvement of tendons was first described by Acrel in the 18th century[5] , providing historical foundation for understanding the evolution of diagnostic and treatment approaches for this condition. Kanavel identified three pathological stages of tubercular tenosynovitis: hygromatous, serofibrinous (rice body formation) and caseous[6].

Rice bodies are materials with an amorphous nucleus and a fibrin layer found floating in the synovial space and bursa, initially seen in rheumatoid arthritis, are common in tuberculous tenosynovitis due to synovial irritation[7].

Classic presentations include:
1. The most common presentation—painless swelling around the carpal tunnel, often involving the flexor sheath of the little finger extending to the ulnar bursa, frequently showing rice bodies, which was seen in 3 of our patients

2. Sausage digit: typically affects a single index, middle, or ring finger, seen in 2 of our patients.

3. Carpal tunnel syndrome: Presents as typical carpal tunnel symptoms with swelling in the volar wrist or distal forearm, seen in 1 of our patients[8].

The condition is rare and may be misdiagnosed due to overlapping clinical features with other diseases. It typically affects middle-aged individuals with chronic swelling and slow progression, leading to delayed diagnosis.

Diagnostic tests like CBC, ESR, and CRP may be normal or elevated but are not specific for tuberculous tenosynovitis. Chest X-rays are often normal; thus, a normal chest radiograph does not exclude the diagnosis[9]. Ultrasonography helps assess synovial thickening, effusion, pus, and lesion spread. MRI is more sensitive and specific than ultrasound. Histopathology is the diagnostic gold standard, showing epithelioid granulomas, Langhans giant cells, and caseous necrosis[10].

Standard treatment involves a four-drug anti-tuberculosis regimen (isoniazid, rifampicin, pyrazinamide, ethambutol) for 2 months, followed by isoniazid and rifampicin for 4 months. Patients generally respond well to treatment with low recurrence rates, indicating favorable outcomes.

LIMITATIONS

- Small sample size
- Single-centre study
- No long-term functional scoring used

CONCLUSION

Tubercular tenosynovitis must be considered in chronic, slowly progressive tendon sheath swelling, especially in TB-endemic regions. Early MRI imaging and tissue diagnosis enable prompt treatment. ATT is highly effective, and synovectomy is beneficial in selected cases.

Patient's consent
Written informed consent was obtained from the patients for publication of this case report and accompanying images

Declaration of generative AI
During the preparation of this work, the authors used ChatGPT (OpenAI) to assist with phrasing, organization, grammar refinement. After using this tool, the authors reviewed, edited, and verified all content as needed and take full responsibility for the integrity and accuracy of the manuscript.

Funding statement
This research did not receive any specific grant from funding agencies in the public, commercial, or not-for-profit sectors.

Declarations of interest
None.

Acknowledgements
None.

REFERENCES

1. Baidoo PK, Baddoo D, Ocloo A, Agbley D, Lartey S, Baddoo NA. Tuberculous tenosynovitis of the flexor tendons of the wrist: a case report. BMC Research Notes. 2018 Apr 10;11(1):238.
2. Kotwal PP, Khan SA. Tuberculosis of the hand: clinical presentation and functional outcome in 32 patients. The Journal of Bone & Joint Surgery British Volume. 2009 Aug 1;91(8):1054-7.
3. Pimm LH, Waugh W. Tuberculous tenosynovitis. The Journal of Bone & Joint Surgery British Volume. 1957 Feb 1;39(1):91-101.
4. Bickel WH, Kimbrough RF, Dahlin DC. Tuberculous tenosynovitis. Journal of the American Medical Association. 1953 Jan 3;151(1):31-5.
5. Chavan S, Sable SS, Tekade S, Punia P. Tuberculous tenosynovitis presenting as ganglion of wrist. Case Reports in Surgery. 2012;2012(1):143921.
6. Kanavel AB. Tuberculous tenosynovitis of the hand: a report of fourteen cases of tuberculous tenosynovitis. Surg Gynecol Obstet. 1923;37:635-47.
7. Chung WY, Song JS, Oh HE, Park HJ. A case of idiopathic massive rice bodies in the knee joint without rheumatoid arthritis or tuberculosis and a literature review. Journal of Rheumatic Diseases. 2016 Oct 31;23(5):316-20.
8. Al-Qattan MM, Al-Namla A, Al-Thunayan A, Al-Omawi M. Tuberculosis of the hand. The Journal of hand surgery. 2011 Aug 1;36(8):1413-21.
9. Hogan JI, Hurtado RM, Nelson SB. Mycobacterial musculoskeletal infections. Infectious Disease Clinics. 2017 Jun 1;31(2):369-82.
10. Suwannaphisit S, Ranong NN. Tuberculous tenosynovitis of the Flexor Tendons of the hand and wrist: A case report and mini-review. Annals of Medicine and Surgery. 2020 Sep 1;57:249-52.

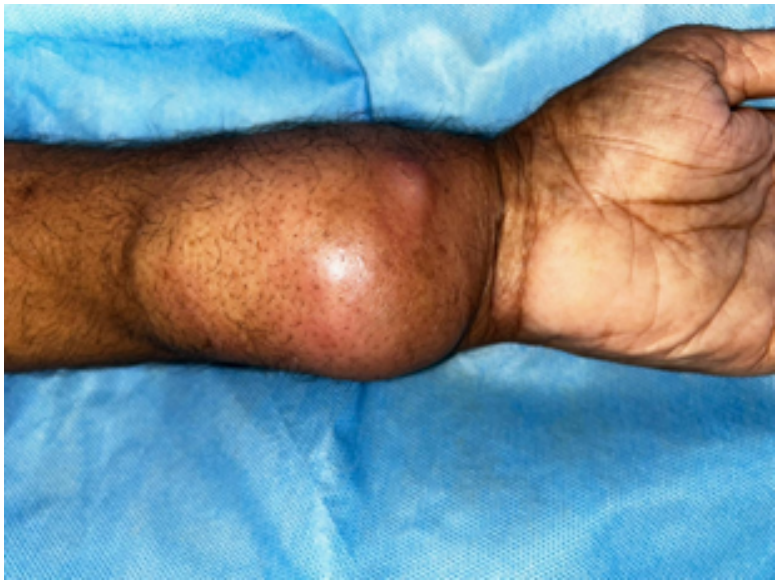

Fig. 1. Case 1 - showing swelling around volar surface of the left forearm

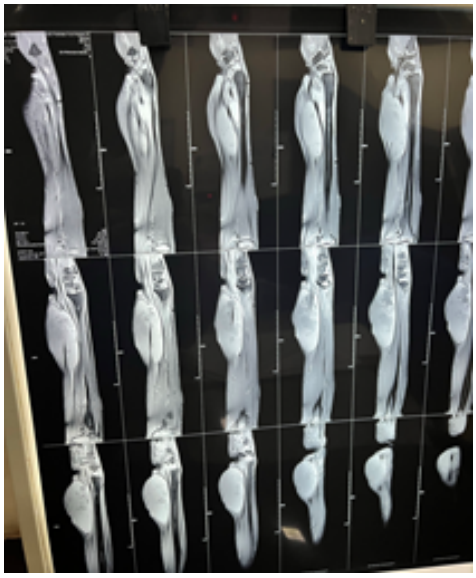

Fig .2 . Case 1 - MRI film



Fig. 3 . Case 1 - intra-operative findings showing yellowish soft tissue mass with melon bodies

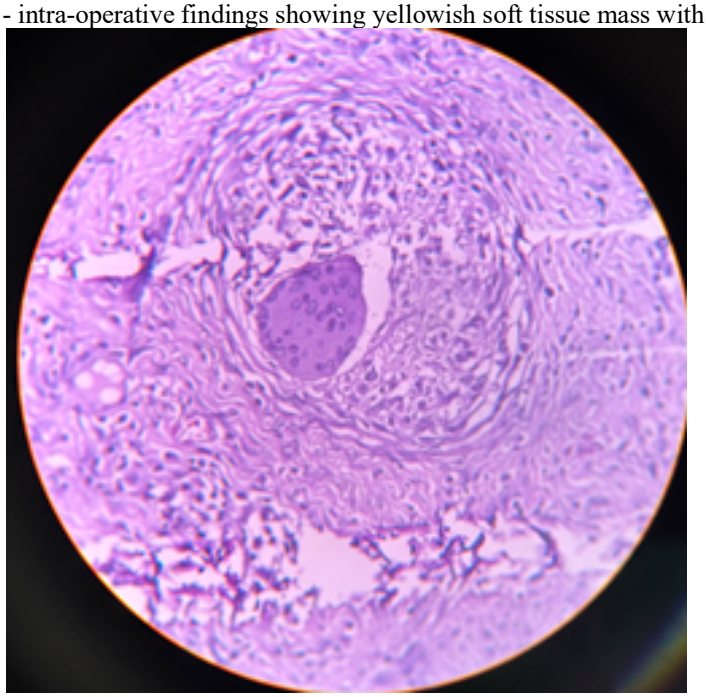

Fig .4. Case 1 - histopathology showing granulomatous changes

Table 1 : case series consisting of 5 patients

Case	Age/Sex	Occupation	Findings	Operative Findings	Histopathology	Cbnaat
1	57/M	Farmer	swelling left forearm + carpel tunnel syndrome	Yellowish soft tissue mass + melon bodies	Tubercular synovitis	Positive
2	70/M	Farmer	Swelling left forearm + pain	Fibrosed synovial sheath + melon bodies	Granulomatous synovitis , S/O tuberculosis	Positive
3	55/M	Buisnessman	Swelling left middle finger	Fibrosed synovial sheath + melon bodies	Granulomatous lesion	Positive
4	38/F	Housewife	Swelling right palm	Inflamed synovial sheath	Chronic inflammation with granuloma	Negative
5	19/M	Student	Swelling + pain right index finger	Inflamed synovial sheath	Chronic granulomatous synovitis	Positive