

Study of the Histopathological Spectrum of CNS Lesions and Their Radiological Correlation in a Tertiary Hospital in South India

Sunil Kumar Katari¹, Harinath Devineni², S. Suneetha³, Sreedhar⁴, Praveena G⁵, Khadeeja T⁶, P.V. Kiran Kumar⁷, P.V. Ramana Babu⁸, T. Dhanamjaya Rao⁹

¹Assistant Professor, Department of Pathology, K.M.C. Kurnool

²Associate Professor, Department of Radiology, K.M.C. Kurnool

³Associate Professor, Department of Pathology, K.M.C. Kurnool

⁴Assistant Professor, Department of Pathology, K.M.C. Kurnool

⁵Assistant Professor, Department of S.P.M., K.M.C. Kurnool

⁶Post Graduate, Department of Pathology, K.M.C. Kurnool

⁷Associate Professor, Department of Pathology, K.M.C. Kurnool

⁸Professor, Department of Pathology, K.M.C. Kurnool

⁹Professor and Head, Department of Pathology, K.M.C. Kurnool

Received: 25-11-2023 / Revised: 23-12-2023 / Accepted: 26-01-2024

Corresponding Author: Dr. Sunil Kumar Katari

Conflict of interest: Nil

Abstract:

Introduction: Lesions of the central nervous system (CNS) can take a serious clinical course, even when they are inflammatory or benign neoplasms. Radiology is the only means of non-invasive assessment prior to a surgical diagnosis. In recent times, advanced radiological techniques have been available for diagnosis and precise localization for a stereotactic biopsy. The radiological impression of any CNS lesion, however, requires confirmation by histological examination of a biopsy. Hence, histopathology remains the gold standard for diagnosis.

Aims and Objectives: To study the histopathological spectrum of the CNS lesions in our health care unit, as well as to compare the histopathological diagnosis with the radiological diagnosis and observe the correlation between them.

Materials and Methods: This retrospective, comparative study included 364 cases of CNS lesions from January 2020 to July 2023. Their clinical history and radiological findings were noted. The histopathological diagnosis was correlated with the radiological diagnosis using Cohen's kappa, with the former being the gold standard.

Results: Out of 364 cases considered for study, 210 males were affected compared to 154 females. The non-neoplastic lesions were 177, out of which males were 97 and females were 80. The most commonly found nonneoplastic lesions were inflammatory lesions. The Neoplastic Benign Lesions were 116, out of which males were 54 and females were 62. The most commonly found benign lesions were noninvasive meningotheial meningiomas. The neoplastic malignant lesions were 71, out of which males were 34 and females were 37. The most common malignant lesion was glioblastoma. The overall correlation between the radiological and histopathological diagnoses was 96%.

Using Cohen's kappa, a value of 0.87 was obtained when the collective data was compared, implying a "near perfect" agreement between the two modalities of diagnosis.

Conclusion: Our study showed that lesions of the central nervous system have a varying age- and sex-wise spectrum. There was a near-perfect agreement between the radiological and histopathological diagnoses, suggesting the latest radiological advancements in technology are nearing accuracy in spite of being noninvasive. This makes them a highly recommendable modality for provisionally diagnosing CNS lesions. However, histopathology is the yardstick against which all the emerging techniques must be measured.

Keywords: Lesions of CNS, Space occupying lesions, brain tumors, multimodal imaging, histopathological-radiological correlation.

This is an Open Access article that uses a funding model which does not charge readers or their institutions for access and distributed under the terms of the Creative Commons Attribution License (<http://creativecommons.org/licenses/by/4.0>) and the Budapest Open Access Initiative (<http://www.budapestopenaccessinitiative.org/read>), which permit unrestricted use, distribution, and reproduction in any medium, provided original work is properly credited.

Introduction

Lesions of the CNS are an important cause of neurological morbidity [1]. They usually take up a

serious clinical course even if they are inflammatory lesions or benign neoplasms [2].

Their potentially life-threatening behaviour is mainly due to their growth in a confined constrained space as well as their proximity to vital structures. [3] The compactness of the cranial cavity and rigidity of the surrounding skull bones, makes it impossible for a pre-operative assessment by clinical examination confining radiology the only means of assessment prior to a surgical diagnosis. [4] Increasingly advanced and sophisticated radiological techniques such as Computed – tomography (CT) scan, Magnetic resonance imaging (MRI), MRI with contrast, Magnetic resonance spectroscopy (MRS), Diffusion weighted imaging (DWI), Perfusion – weighted imaging (PWI) is very much available in the recent times. [5] These imaging techniques determine whether a lesion is either solid or cystic, it’s vascularity and the presence or absence of necrosis. Based on these a probable diagnosis, behaviour and prognosis of the lesion can be made out. These Radiological techniques guide us to plan a proper surgery and to get a stereo-tactic biopsy from the precise localization of the lesion. [6,7] The radiological impression of a CNS lesion always requires confirmation by histological examination of a tissue biopsy making it the gold standard for diagnosis. [8,7]

Radiological examination is also supportive for an accurate histological diagnosis. Hence the importance of coordination between neurosurgeon, radiologist and pathologist must be overemphasised. [4]

Materials and Methods

This retrospective, comparative study included three hundred and sixty four (364) consecutive cases of the CNS biopsies diagnosed in the department of Pathology, Kurnool Medical College, Kurnool. India. The duration of the study was from 1st January 2020 to July 2023. These cases were referred from the department of Neurosurgery, Government General Hospital, Kurnool. India. Relevant demographic data such as age, gender along with their clinical history and radiological findings were recorded in study proforma.

While every effort was made to obtain the pre-operative radiological findings like CT scan and MRI scan, in a few cases it was not retrieved and were excluded from the comparative study. All the specimens were totally processed, sections were stained with Haematoxylin and Eosin initially. Some cases were also stained with Periodic Acid Schiff (PAS) and Ziehl Neelsen (ZN) stains wherever necessary. At times IHC was used for confirmation. The histopathological diagnosis was correlated with radiological diagnosis using Cohen’s kappa. The former served as the gold standard against which the latter was assessed [18]. The Cohen’s Kappa is an index that measures inter-rater agreement for categorical or qualitative variables when two different observers or methods are employed. The value of K ranges between 0 and +1, a value of kappa equal to +1 implies perfect agreement between the two raters, while that of 0 implies No agreement or disagreement. [9] Only those specimens with proper radiological data were subjected to this analysis.

Cohen’s Kappa	Interpretation
0	No Agreement
0.10 – 0.20	Slight Agreement
0.21 – 0.40	Fair Agreement
0.41 – 0.60	Moderate Agreement
0.60 – 0.80	Substantial Agreement
0.81 – 0.99	Near Perfect Agreement
1	Perfect Agreement

Inclusion Criteria: All the CNS Specimens sent from the department of Neurosurgery with relevant radiological data were considered for this comparative study.

Exclusion Criteria: All the CNS Specimens sent from the department of Neurosurgery without

relevant radiological data were considered for the retrospective study but excluded from this comparative study.

Results: The details of age wise and sex wise distribution of all the lesions are represented in table below.

Table 1:

Non-Neoplastic Lesions																	
Age Range	0-10		11-20		21-30		31-40		41-50		51-60		61-70		71-80		Total
Gender	M	F	M	F	M	F	M	F	M	F	M	F	M	F	M	F	
Inflammatory Lesions	6	0	4	5	5	12	13	15	22	22	9	3	6	3	0	0	125
Cystic lesions	2	1	2	1	2	2	1	1	5	3	2	3	3	2	0	1	31
Disc Prolapsed cases	0	0	0	0	0	0	0	0	4	1	6	1	4	4	0	0	20

Subdural Hematoma	0	0	0	0	0	0	0	0	0	0	1	0	0	0	0	1	
Total	8	1	6	6	7	14	14	16	31	26	18	7	13	9	0	1	177
Benign Lesions																	
Meningothelial Meningioma	0	0	0	0	0	0	1	6	4	8	4	5	2	2	0	0	32
Fibrous Meningioma	0	0	0	1	0	3	3	1	4	4	2	0	0	0	0	0	18
Transitional Meningioma	0	0	0	0	0	0	0	0	1	2	2	1	2	0	0	0	8
Psammomatous Meningioma	0	1	0	0	0	0	0	0	0	0	0	2	0	0	0	0	3
Secretary Meningioma	0	0	0	0	0	0	0	0	0	0	1	0	0	0	0	0	1
Microcystic Meningioma	0	0	0	0	0	1	0	0	0	0	0	0	0	0	0	0	1
Papillary Meningioma	0	0	0	0	0	0	0	1	0	0	0	0	0	0	0	0	1
Neurofibroma	0	0	0	0	2	1	2	0	0	0	0	3	0	0	0	0	8
Schwannoma	0	0	0	0	0	2	1	2	5	1	2	3	1	2	0	0	19
Low Grade Astrocytomas	0	0	0	0	0	0	3	1	4	5	5	2	0	0	0	0	20
Oligodendroglioma	0	0	0	0	0	0	0	0	0	0	0	1	0	0	0	0	1
Craniopharyngioma	0	1	1	0	0	0	0	0	0	0	0	0	0	0	0	0	2
Choroid Plexus Papilloma	1	0	0	0	0	0	0	0	0	0	0	0	0	0	0	0	1
Ependymoma	0	0	0	0	0	0	0	0	1	0	0	0	0	0	0	0	1
Total	1	2	1	1	2	7	10	11	19	20	16	7	5	4	0	0	116
Malignant Lesions																	
Malignant Meningioma	0	0	0	0	0	0	0	0	1	0	0	1	1	0	0	0	3
Astrocytoma Grade 3	1	0	1	0	1	0	3	3	0	0	0	2	1	1	0	0	13
Glioblastoma	0	0	0	0	1	0	1	0	2	2	4	6	5	5	1	0	27
Medulloblastoma	4	6	4	4	0	0	0	0	0	0	0	0	0	0	0	0	18
PNET	0	1	2	0	0	0	0	0	0	0	0	0	0	0	0	0	3
METS	0	0	0	0	0	0	0	1	0	2	1	2	0	1	0	0	7
Total	5	7	7	4	2	0	4	4	3	4	5	11	7	7	1	0	71
Grand Total	14	10	14	11	11	21	28	31	53	50	39	35	25	20	1	1	364

Out of 364 cases in our study, maximum number of cases was observed in the 4th decade amounting to 103 cases, while the least number of cases was observed in the 7th decade probably due to the mortality outcome of CNS lesions prior to the 7th decade.

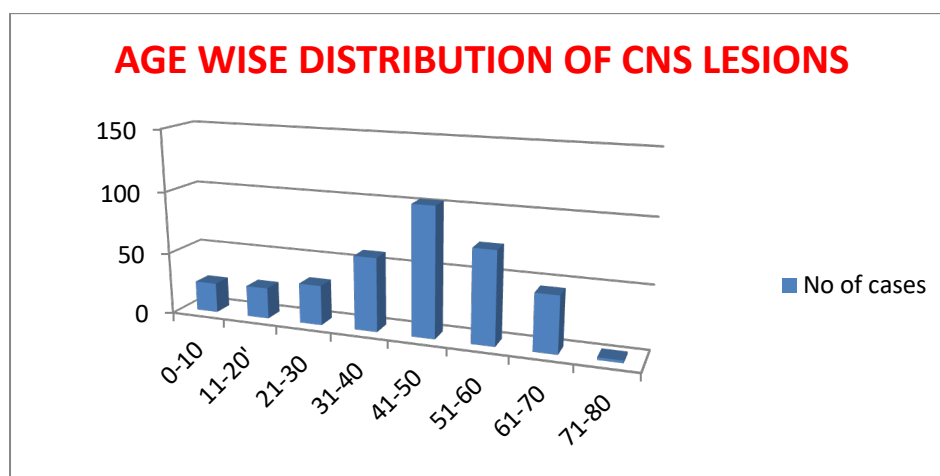


Figure 1: Age Wise Distribution of CNS Lesions

In our study, considering all the 364 CNS lesions, 210 Males were affected against 154 females amounting to 58% in males and 42% in females.

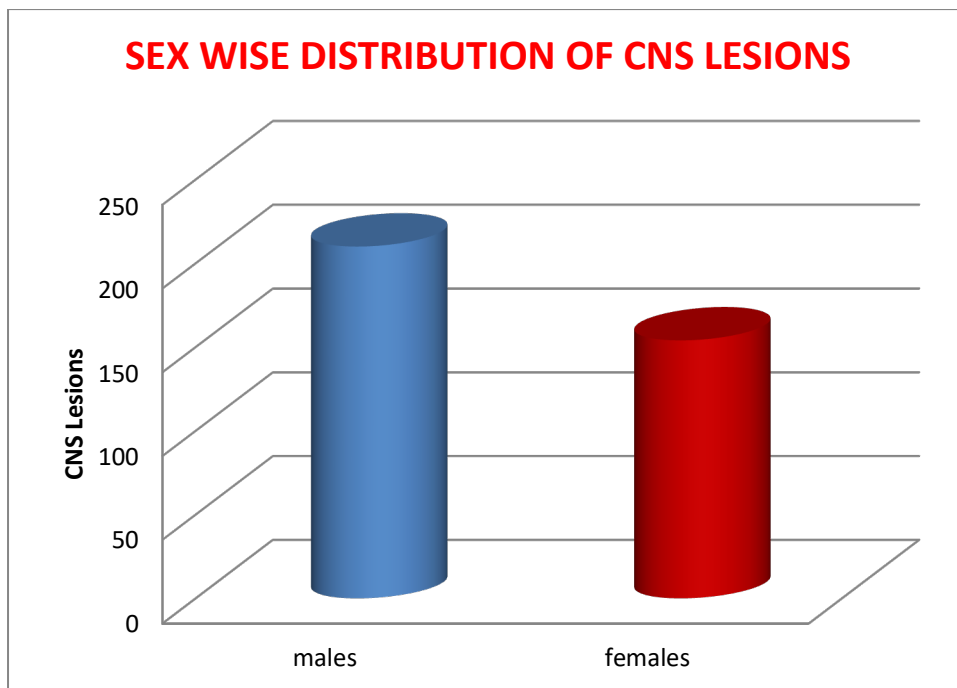


Figure 2: Sex Wise Distribution of CNS Lesions

In our study out of 364 cases 177 were nonneoplastic cases while 116 were benign lesions and 71 were malignant lesions which correlated with all the previous studies.

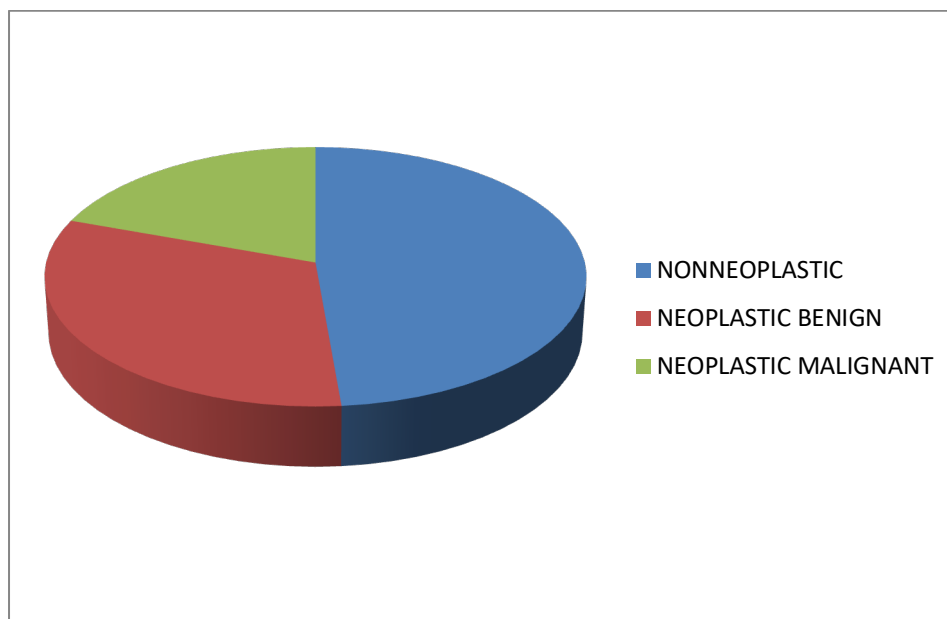


Figure 3:

The total number of non-neoplastic lesions was 177, out of which males were 97 (55%) and females were 80 (45%). The most commonly found non-neoplastic lesions were inflammatory lesions (125; 71%), followed by cystic lesions (31; 18%), disc prolapsed cases (20; 11%), and subdural hematoma (1; very negligible).

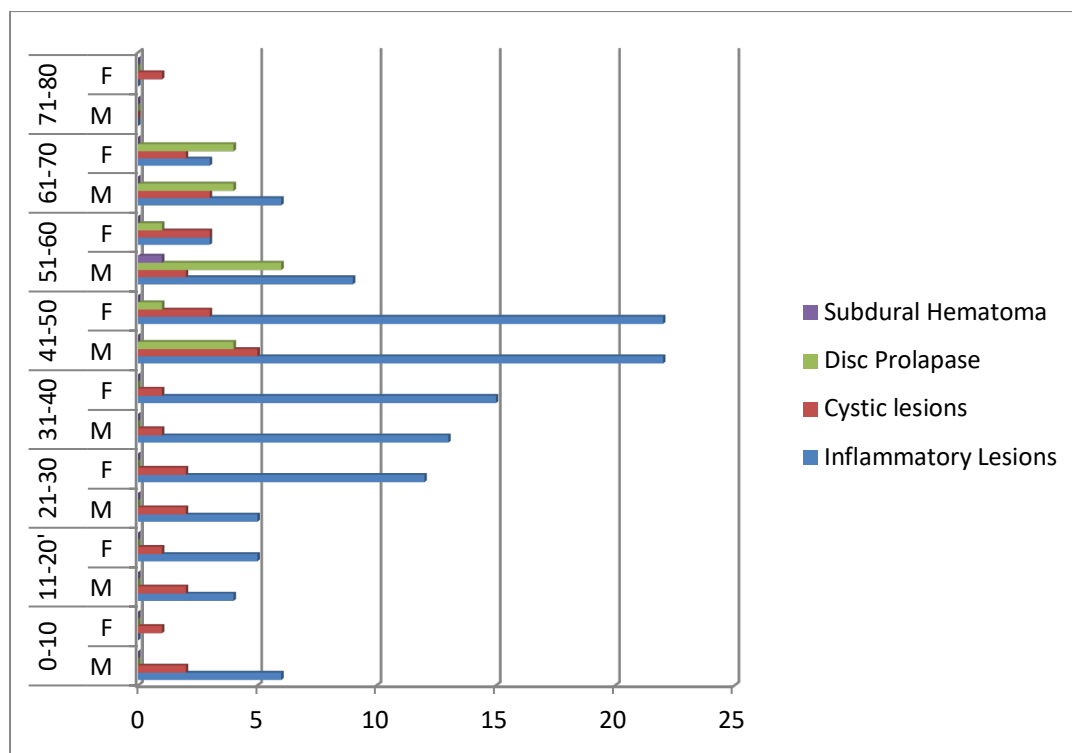


Figure 4:

The neoplastic benign lesions were 116, out of which males were 54 (46%), females were 62 (54%), and females were slightly more affected than males. The most commonly found benign lesions were non-invasive meningothelial meningiomas (32; 28%), followed by low-grade astrocytomas (20; 17%), schwannomas (19; 16%), fibrous meningiomas (18; 15.5%), transitional meningiomas (8; 7%), and neurofibromas (8; 7%). There were negligible cases of other entities.

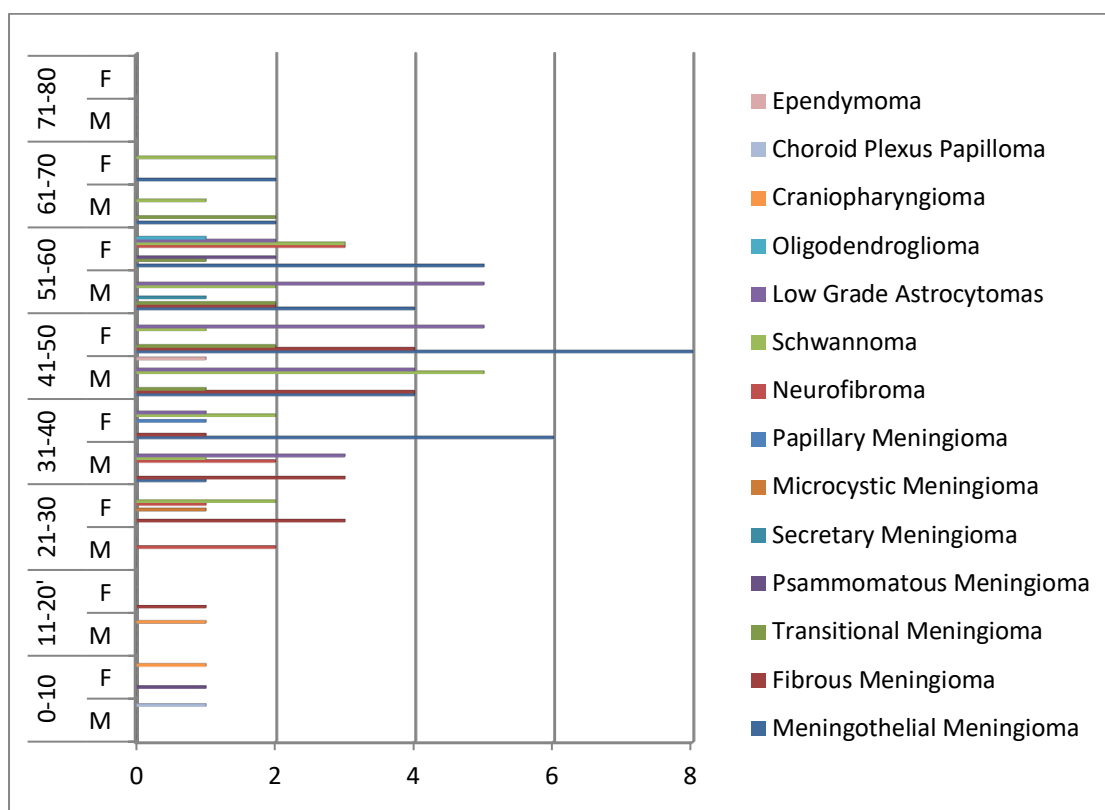


Figure 5:

The Neoplastic Malignant Lesions were 71 out of which Males were 34 (48%) and Females were 37 (52%) which again was a slight increase in female population than males. The commonest malignant lesion was Glioblastoma (27;38%) followed by Medulloblastoma (18;25%), Grade 3 Astrocytomas (13;18%), METS (7;10%), PNET (3;4%) and Malignant Meningioma (3;4%).

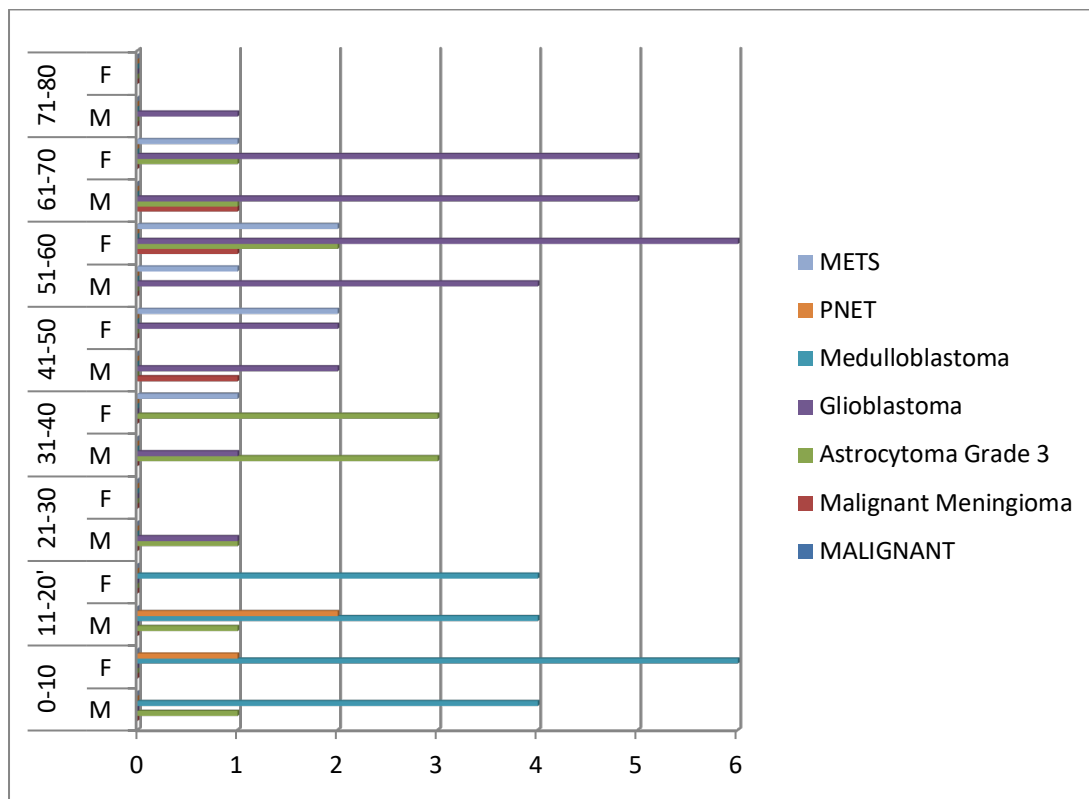


Figure 6:

As we correlated our histopathological results with the provisional diagnoses made by the radiologist, most of the cases showed a concordance of 96% while a few showed discordance. The details of cases showing discordance are shown in the table below. Table showing the details of discordance between the radiological and histopathological diagnoses.

Table 2:

Sl. No.	Final Histopathological Diagnosis along with No. of Cases	No of Cases Radiologically correlated	No of Cases not Correlated Radiologically	% Of Correlation	KAPPA Value	Agreement
1.	Metastasis (7)	5	2	71%	0.831	Near Perfect
2.	Low Grade Astrocytomas (20)	17	3	82%	0.915	Near Perfect
3.	Glioblastomas (27)	26	1	96%	0.980	Near Perfect
4.	Invasive Meningiomas (3)	2	1	67%	0.799	Substantial
5.	Noninvasive Psammomatous Meningiomas (3)	2	1	67%	0.799	Substantial
6.	High Grade Astrocytomas (13)	12	1	92%	0.959	Near Perfect
7.	Medulloblastomas (18)	16	2	88%	0.938	Near Perfect
8.	PNET (3)	2	1	67%	0.799	Substantial
9.	Cystic Lesions (31)	30	1	97%	0.982	Near Perfect

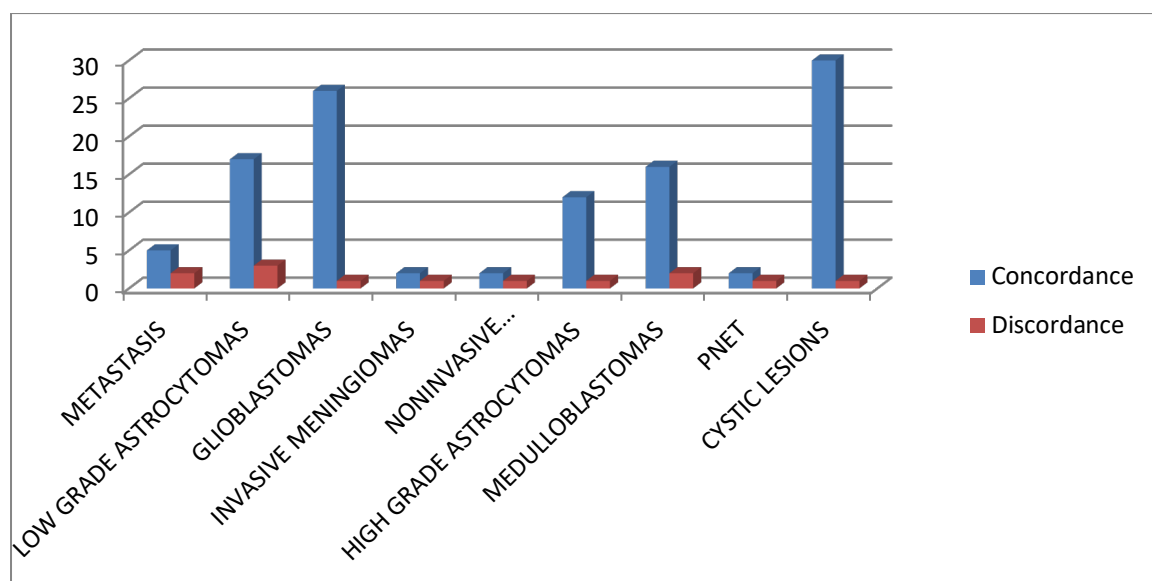


Figure 7:

Discussion

In our study, out of 364 cases considered, 210 males (58%) were affected compared to 154 females (42%). The greatest number of patients was in the fourth decade of age, which was very similar to the results of the study done in 2015 by Dogar T et al. [17]. As observed in all other studies, the non-neoplastic lesions were more compared to the neoplastic benign and malignant lesions, which were respectively in the second and third positions.

There was almost an absolute correlation among the diagnoses made for the nonneoplastic lesions except for one cystic lesion (97% correlation) while the discordance was relatively more against the diagnoses made among the neoplastic lesions with non-invasive psammomatous meningiomas, PNET and invasive meningiomas showing 67% of concordance, yet their kappa value was 0.799 which showed substantial agreement between the radiological and histopathological diagnoses among them.

The overall correlation between the radiological and histopathological diagnoses was 96%. Using Cohen's kappa an overall kappa value of 0.87 was obtained when the collective data was compared, implying a "Near Perfect" agreement between the two modalities of diagnosis. Similar Near Perfect agreement was found when all the radiological diagnoses that differed from the histopathological diagnoses were compared. Our study of correlation between the radiological and histopathological diagnoses differed from the study done in 2015 by Dogar T et al. [17] where the kappa value was 0.3 which was a complete disagreement between the radiological and the histopathological diagnoses. But our study correlated with the studies made by Ishita Pant et al. [19] in 2015, Srinivasas Rao S et

al. [20] in 2018 and Andi Ihwan et al. [18] in 2022. So, with the increasing advancements in radiological equipments especially MRI and the efficiency of the Radiologists can definitely bring out a Near Perfect agreement between the radiology and histopathology [19,20].

Conclusion

Our study showed that lesions of the central nervous system have a varying spectrum of age-wise and sex-wise distribution and their accurate diagnosis is essential for their proper management.

The Near Perfect agreement between the radiological and histopathological diagnoses suggest that the latest radiological advancements in technology are near to accuracy in spite of being noninvasive which makes them a highly recommendable modality for provisionally diagnosing CNS lesions.

The neurosurgeon, along with the radiologist and the pathologist are essential for the perfect diagnosis, management and follow-up of these cases. However, an extensive review of the prevailing literature reveals that histopathology remains the yardstick against which all emerging techniques must be measured.

References

1. M Tesfay, Y Hawaz, G Assefa, M Abebe. Radiological Features and Postoperative Histopathologic Diagnosis of Intracranial Masses at Tikur Anbessa Specialized Hospital and MCM Hospital. East and Central African Journal of Surgery. 2013; 18 (1): 95-106.
2. Vinay Kumar, Abul K. Abbas, Jon C.Aster. Robbins and Cotran Pathologic Basis of Disease. 10th ed. Philadelphia, PA: Saunders / Elsevier; 2020.

3. Rozina Jaffar, Tanya Dogar, Asmaa Qureshy, Navid Qureshi. Central Nervous System Tumours-A Study of Frequency and Morphology. *JFJMC*, 2011; 05 (02): 116-118.
4. Maysa Al-Hussaini. Histology of primary brain tumors. *INTECH*, 2013: 10: 145-80.
5. Ahmed, Ishtiaq & Rafique, Muhammad & Hussain, Munawar & Akhtar, Waqar & Ahmed, M.N. & Sajjad, Zafar & Ali, S.Z. (2010). MRI characterization and histopathological correlation of primary intra-axial brain glioma. *Journal of the Liaquat University of Medical and Health Sciences*. 2010;9: 64-69.
6. Omuro AM, Leite CC, Mokhtari K, Delattre JY. Pitfalls in the diagnosis of brain tumours. *Lancet Neurol*. 2006 Nov; 5(11):937-48.
7. Abul-Kasim, K., Thurnher, M., Puchner, S., & Sundgren, P. (2013). Multimodal magnetic resonance imaging increases the overall diagnostic accuracy in brain tumours: Correlation with histopathology. *South African Journal of Radiology*, 17(1), 4-10.
8. Alam MS, Sajjad Z, Hafeez S, Akhter W. Magnetic resonance spectroscopy in focal brain lesions. *J Pak Med Assoc*. 2011 Jun;61(6):540-3.
9. Jean Carletta. 1996. Assessing Agreement on Classification Tasks: The Kappa Statistic. *Computational Linguistics*, 22(2):249–254.
10. Z. Mahmoud, Mustafa. Intra Cranial Space Occupying Lesions In Saudi Patients Using Computed Tomography. *Asian Journal of Medical Radiological Research*. 2013;1: 25-28.
11. Chen L, Zou X, Wang Y, Mao Y, Zhou L. Central nervous system tumors: a single center pathology review of 34,140 cases over 60 years. *BMC Clin Pathol*. 2013 May 2; 13(1):14.
12. Petrovic NS, Grujicic D, Artiko VM, Sobic-Saranovic DP, Gajic MM, Jaksic E, Grajic MM, Antonovic OJ, Petrovic MN, Obradovic VB. Investigation of blood perfusion and metabolic activity of brain tumours in adults by using ^{99m}Tc-methoxyisobutylisonitrile. *Nucl Med Commun*. 2010 Nov;31(11):962-73.
13. Wasay M, Moolani MK, Zaheer J, Kheleani BA, Smego RA, Sarwari RA. Prognostic indicators in patients with intracranial tuberculoma: a review of 102 cases. *J Pak Med Assoc*. 2004 Feb; 54(2):83-7. Erratum in: *J Pak Med Assoc*. 2004 Jul; 54(7):401. Smego, AR [corrected to Smego, RA].
14. Sh. Birang, M. Sanei Taheri, Y. Kholghi, V. Nahvi. Tuberculous meningoencephalitis: Intracranial tumoral presentation. *Iran. J. Radiol*. 2005; 3: 29-33.
15. Rosai J, Akerman L. Rosai and Akerman's surgical pathology, volume2. 11th ed. University of Chicago: Mosby; 2017.
16. Edwin Boldrey. The Pathology of Brain Tumors and Its Relationship to Roentgenologic Diagnosis. *Radiology*. 1943; 41:2, 107-116
17. Dogar T., Imran A.A., Hasan M., Jaffar R., Bajwa R. And Qureshi I.D. Space Occupying Lesions of Central Nervous System: A Radiological and Histopathological Correlation. *Biomedica*. Jan.-Mar., 2015;31(1): 15-20.
18. Ihwan A, Rafika R, Cangara MH, Sjukur KJ, Faruk M. Correlation between Radiological Images and Histopathological Type of Meningioma: A Cohort Study. *Ethiop J Health Sci*. 2022 May; 32(3):597-604.
19. Pant I, Chaturvedi S, Jha DK, Kumari R, Parteki S. Central nervous system tumors: Radiologic pathologic correlation and diagnostic approach. *J Neurosci Rural Pract*. 2015 Apr-Jun; 6(2):191-7.
20. Srinivasarao S. Gummadidala, B. Jyothi. Study determining correlation between histopathological diagnosis and MRI findings of posterior fossa tumors. *International Journal of Contemporary Medicine Surgery and Radiology*. 2018; 3(2): B15-B19.