

Case Report

Ventricular Tachycardia in Dengue Fever

Mohammed M.Z^{1*}, Venugopal.K², Kadappa Jaligidad³, Bharathraj M.Y⁴, Anudeep Reddy⁵

Department of General Medicine, Vijayanagara Institute of Medical Sciences, Bellary, Karnataka, India.

Available Online: 1st March, 2015

ABSTRACT

Dengue fever is an endemic vector borne viral infection in many parts of tropical countries. Dengue myocarditis is an uncommon complication of dengue fever that rarely complicates into ventricular tachycardia. We report a case of 24 year old male presented to emergency department with history of sudden onset of chest pain, with prior history of fever with myalgia, joints pain since 5 days. On examination, patient was in shock, ECG revealed ventricular tachycardia [VT]. Post DC shock with 200 joules, VT reverted and ECG showed sinus rhythm. Further investigation supported that patient was suffering from dengue myocarditis.

Keywords: *Dengue fever, Myocarditis, Ventricular tachycardia*

INTRODUCTION

Dengue virus (DENV) infection is caused by single-stranded, positive-sense Ribonucleic acid (RNA) viruses in the family of Flaviviridae. Dengue is a worldwide condition, spread throughout the tropical and subtropical zones. This virus is transmitted by mosquito vectors, primarily *Aedes aegypti*. DENV infections cause a broad spectrum of illnesses from self-limited fever to severe hemorrhagic manifestations and increased vascular permeability. Cardiac manifestations of dengue are rarely associated with severe dengue fever. Cardiac conduction disorders such as atrioventricular blocks, sinus node dysfunction, and ectopic ventricular beats have been reported during episodes of Dengue Hemorrhagic Fever (DHF). Ventricular tachycardia in dengue fever is not reported in any of literatures available till now. We are reporting a case in which the patient with dengue fever presented as having ventricular tachycardia possibly triggered by myocarditis.

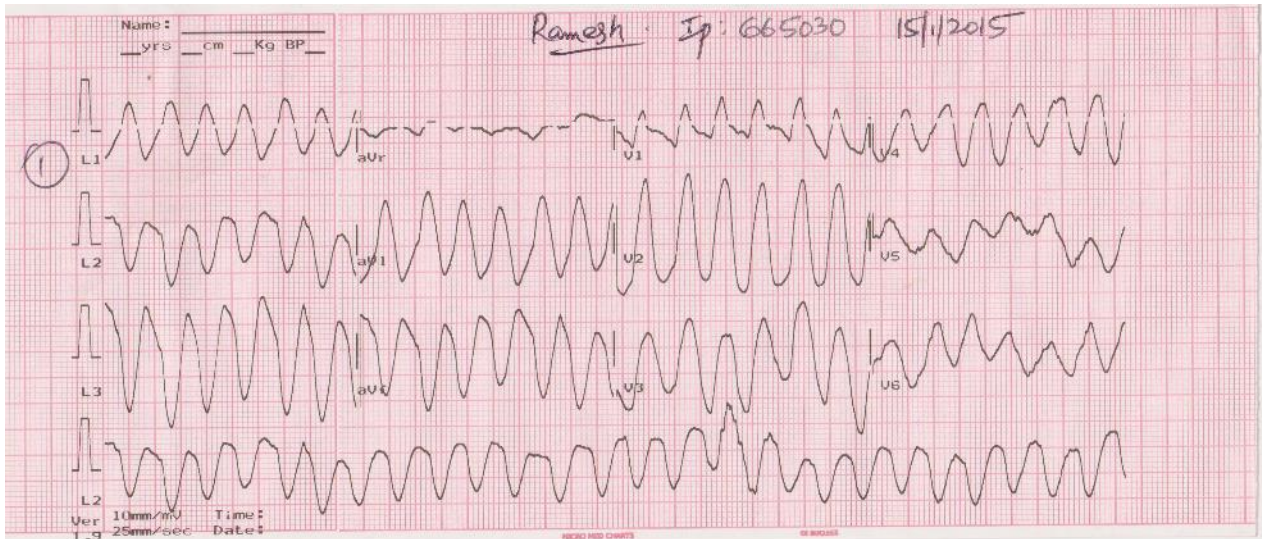
CASE REPORT

A 24-year-old gentleman presented with chest pain of 18 hours duration before hospital admission. The pain was associated with vomiting, palpitations and respiratory distress. He had a history of fever, myalgia and joint pain since five days. He also had generalized swelling of the body with non-pruritic body rash, which started two days before admission. He did not have any history of bleeding, cough, or altered sensorium. He did not have any significant past history of a cardiac problem or cardiac interventions. A general physical examination revealed temperature of 101F, erythematous confluent maculopapular body rash, facial puffiness, bipedal edema, heart rate of 250 beats/min, and BP was not recordable. His oxygen saturation on room air was 80%. The cardiac examination revealed tachycardia. He was drowsy, arousable with painful stimuli. Other system examinations

did not reveal any significant findings. A twelve lead ECG showed broad complex tachycardia suggestive of ventricular tachycardia. Since BP was not recordable, 100 J followed by 200 J of DC shock was given 3 minutes apart. After DC shock, his BP was 100/70 mmHg. ECG showed sinus rhythm. Bedside echocardiography showed anteroseptal area hypokinesia with global left ventricular (LV) dysfunction and an ejection fraction of 55%. Patient was started on injection amiodarone 150mg IV bolus, followed by maintenance infusion. The blood parameters showed total count of 3300cells/cumm, platelet count of 44,000cells/cumm, haemoglobin of 8.8 grams/dL and packed cell volume of 35%. The liver function and renal function tests were within normal limits, and the blood clotting profile was also normal. Blood test was positive for dengue IgG and IgM antibodies by enzyme-linked immunosorbent assay (ELISA), confirming a diagnosis of dengue fever. Patient was treated with adequate IV fluids, antipyretics. No other complications encountered. Patient improved symptomatically was discharged on sixth day after admission.

DISCUSSION

Myocardial involvement in dengue may result either from direct DENV invasion of the cardiac muscles or a cytokine-mediated immunological response, or both.¹ Myocardial dysfunction has been reported to be more severe in patients with dengue shock syndrome (DSS) when compared to those with dengue fever (DF) or non-shock Dengue Hemorrhagic Fever (DHF).² Cardiac arrhythmia such as atrioventricular block and sinus node dysfunction, as well as, reversible myocarditis has been reported in patients with DF; most of these are self-limiting.³ Approximately, 16% of the patients with DF have ejection fractions of less than 50%, and 70% of the patients with DHF or DSS have diffuse ventricular hypokinesia.² Till now only 3 cases of dengue fever with



Graph 1: ECG of the patient at the time of admission showing wide complex regular tachycardia, suggestive of ventricular tachycardia.

myocardial infarction have been reported. The first one reported by Lee et al,⁴ was a 25-year-old male, who presented with acute pulmonary edema and cardiogenic shock. He had ECG features suggestive of anterior wall MI, and died. Another case reported by Lee IK et al,⁵ was a 65-year-old female who presented with DHF. She had significant ST-segment depression in the chest leads V3-V6, but survived. 3rd case was reported by S Patra et al, was a 22 year old female presented with acute onset of chest pain, diagnosed to have anterior wall MI, further investigations confirmed to have dengue myocarditis.⁶ However we are reporting a rare cardiac complication of dengue fever with possible myocarditis causing ventricular tachycardia.

CONCLUSION

Dengue fever can present with a various cardiac complications. Ventricular tachycardia is a rare presentation but being one among them. Ventricular tachycardia could be triggered by dengue myocarditis. If patient comes with fever and positive dengue serology along with signs of shock, must be closely observed for cardiac rhythm abnormalities especially ventricular tachycardia and it should be considered as a possible differential diagnosis of dengue shock syndrome.

REFERENCES

1. Salgado DM, Eltit JM, Mansfield K, et al. Heart and skeletal muscle are targets of dengue virus infection. *Pediatr Infect Dis J.* 2010;29:238e242
2. Kabra SK, Juneja R, Madhulika, et al. Myocardial dysfunction in children with dengue haemorrhagic fever. *Natl Med J India.* 1998;11:59e61.
3. Khongphatthallayothin A, Chotivitayatarakorn P, Somchit S, Mitprasart A, Sakolsattayadorn S, Thisyakorn C. Morbidity type I second degree AV block during recovery from dengue hemorrhagic fever. *Southeast Asian J Trop Med Public Health.* 2000;31:642e645
4. Lee CH, Teo C, Low AF. Fulminant dengue myocarditis masquerading as acute myocardial infarction. *Int J Cardiol.* 2009;136:e69e71
5. Lee IK, Lee WH, Liu JW, Yang KD. Acute myocarditis in dengue hemorrhagic fever: a case report review cardiac complications dengue-affected patients. *Int J Infect Dis.* 2010;14:e919e922.
6. Soumya Patra, Gaurav Bhardwaj, Jayadevappa Suranagi Manohar, Kikkeri Hemannasetty Srinivasa, Jayashree Kharge, Cholenahally N. Manjunath. Acute myocardial infarction being the presentation of dengue myocarditis. *Journal of Cardiovascular Disease Research.* 2013;159-161