

## Hepatoprotective Activity of *Elytraria acaulis* Plant Extracts in Albino Rats

G. Venkat Raji Reddy\*, R. Vijay Kumar, M. Krishna Reddy

*Reproductive physiology unit, Department of zoology, Kakatiya university, warangal – 506009, Telangana state.*

Available Online: 22<sup>nd</sup> November, 2014

### ABSTRACT

Development in the science is helping the people to have the knowledge of unknown things. In that attempt, finding the plants as the best therapeutic option for the health problems and making them familiar to the people. The present experiment was conducted for 7 days to evaluate the hepatoprotective activity of plant *Elytraria acaulis* in CCl<sub>4</sub> (1ml/kg) treated rats. The extracts were prepared by the *Elytraria acaulis* whole plant extracts in ethanol and aqueous solvents through maceration technique. The 6 groups were maintained as control, CCl<sub>4</sub> induced, CCl<sub>4</sub>+ Liver tonic, CCl<sub>4</sub>+*Elytraria acaulis* extracts (ethanol 200mg/kg and aqueous 200mg/kg). On the 8<sup>th</sup> day blood was collected for the study of serum enzymes like SGOT (Serum Glutamate Oxaloacetic Transaminase), SGPT (Serum Glutamate Phosphate Transaminase) and bilirubin and then the separated liver is processed for the histological studies. The decreased levels of SGOT, SGPT and total bilirubin in the treated rats were an indication of the hepatoprotective activity of extracts of *Elytraria acaulis*. The histological changes are also evidence for hepatoprotective activity of extracts. All the values are significant at p<0.05.

### INTRODUCTION

Though the Science is enormously developed certain diseases and syndromes are unable to be tolerated by the human being because of their dominance against human being. Some of the diseases like cancer, HIV, malaria etc. are still in the mind of Scientists to which they are unable to find out solution. Though, the development is enormous in various fields the poor unable to get the treatment facility. That's why the people preferring the local doctors. Sometimes the treatment of those practitioners may workout or not. But ultimately, the poor only suffer with the results. The ancient practitioners for medicine depending on the plants can solve the various diseases, which are uncovering by the researchers to the people. Among them there are several plants that have the capacity to combat against the disorders in the liver.

Liver is vital organ, which is maintaining of metabolic reactions in the human body. But unnecessary food habits, consuming of impure drinks may bring problems in functioning the liver. Consuming more number of drugs also cause the liver damage<sup>5</sup> intake of alcohols, junk food etc are also questioning the functional ability of the liver by damaging the liver architecture. Damage of liver can be assessed by the elevated levels of serum enzymes like SGOT, SGPT and bilirubin<sup>7</sup>. Though the huge utilities of allopathic drugs are available they are not fulfilling the solution. But the medicinally valued plants are capable to target these types of problems. In that attempt many plants are proved that they possess the hepatoprotective activity<sup>3</sup>. Plants having the capability of fighting against free radicals generated in the body leads to protection of vital organs like liver.

The present interest is to find out the free radical scavenging activity and liver protection activity of whole plant extracts of *Elytraria acaulis* against CCl<sub>4</sub> induced hepatic damage.

### MATERIAL AND METHODS

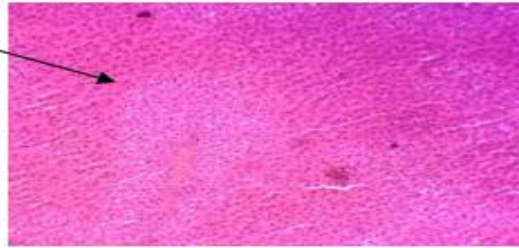
**Plant material:** The whole plant of *Elytraria acaulis* were brought from the forest area of the Gudur Village, Warangal district, Telangana State. The plants materials are generally practiced by the village tribal people for various ailments. (*Elytraria acaulis* is for asthma, migraine, snake bite, mammary tumor etc). The *Elytraria acaulis* plant is already proved its anti hyperglycemic activity. The collected plants were authenticated, given voucher number and preserved in the laboratory.

**Hydroalcoholic Extract:** The whole plant were dried under shade and the powder was prepared from extracts. The powder (50 gr) was kept in the hydroalcoholic (250 ml) solvent (70% of ethanol, 30% of distilled water) and allowed for 24 hrs with the random shaking. Then the filtrate-I was collected and the marc again allowed in 250 ml of hydroalcoholic solvent for 6 hrs and collected the filtrate-II. Then the filtrates (I&II) were performed distillation to get extracts and stored in refrigerator prior to treatment.

**Aqueous Extract:** The whole plant were dried under shade and the powder was prepared from extracts. The powder (50 gr) was kept in the aqueous (250 ml) extracts and allowed for 24 hrs with the random shaking. Then the filtrate-I was collected and the marc again allowed in 250 ml of aqueous extracts for 6 hrs and collected the filtrate-II. Then the filtrates (I&II) were performed distillation to get extracts and stored in refrigerator prior to treatment.

Histological sections of liver

Damaged hepatocytes

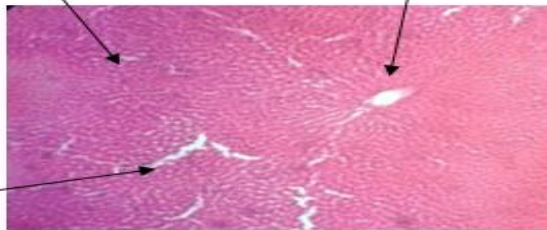


Liver section shows the histology with damaged hepatocytes

Fig. 1: liver cross section (ccl<sub>4</sub> induced rat)

Regenerated liver cells

Central vein

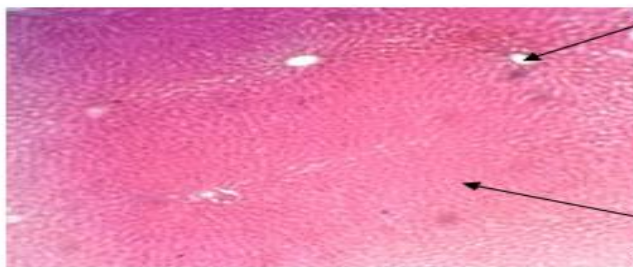

Sinusoids

Liver section shows the histology with rearranged sinusoids and hepatocytes.

Fig. 2: liver cross section (ccl<sub>4</sub> + liver tonic)

Central vein

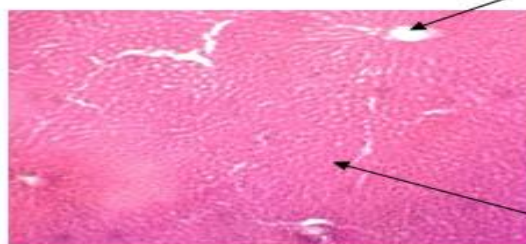


Reformed liver cells

Liver section shows the histology with rearranged sinusoids and hepatocytes.

Fig.3: Liver Cross Section (Ccl<sub>4</sub> + Eaae)

Central vein



Rearranged liver cells

Liver section shows the histology with rearranged sinusoids, hepatocytes and central vein.

Fig.4: Liver Cross Section (Ccl<sub>4</sub> + Eaae)

Animal models: Albino rats (Wistar strain) weighing 150 to 200gr were brought from Mahaveer Enterprizers, Hyderabad. The rats were housed and acclimatized to standard laboratory conditions. The animals were fed with standard diet (Hypro feed for animals, Pune) and water provided at ad libitum.

Toxic study of the extracts:

Hydroalcoholic Extract: To study the toxicology of hydroalcoholic whole plant extracts of *Elytraria acaulis*, the doses (150,200,250,300 mg/ kg) were administered to the rats (5 groups – 8 animals in each group) and put under observation for 72 hrs<sup>6</sup>. There was no toxic effect observed to the rats and the 200 mg / kg were selected for the treatment.

Aqueous Extract: To study the toxicology of aqueous extract whole plant extracts of *Elytraria acaulis*, the doses (150,200,250,300 mg/ kg) were administered to the rats (5 groups – 8 animals in each group) and put under observation for 72 hrs<sup>6</sup>. There was no toxic effect observed to the rats and the 200 mg / kg were selected for the treatment.

Experimental Design: The animals were divided into 5 groups of 8 in each

Group-1 treated with dist. water for 7 days (Control).

Group-2 CCl<sub>4</sub> (Carbon tetra chloride) was given intra peritonally (1ml/ kg) with 1:1 dilution of coconut oil on the 5<sup>th</sup> day<sup>3</sup>.

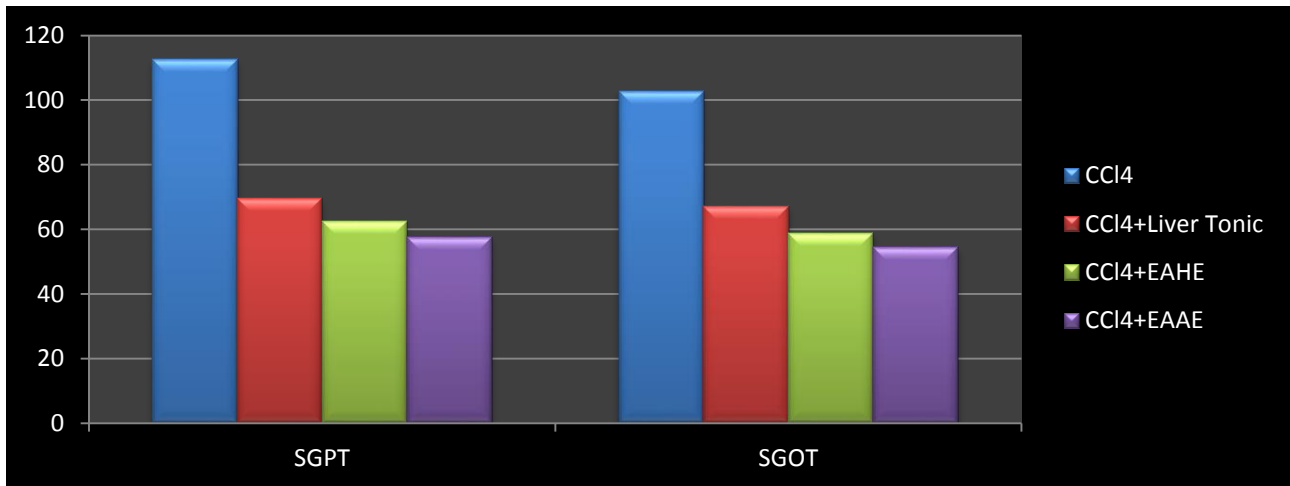
Group-3 Administered with liver tonic (5ml/kg) daily for 7 days and on 5<sup>th</sup> day the CCl<sub>4</sub> is induced through i.p. (1 ml / kg).

Group - 4, 5 were treated with *Elytraria acaulis*'s hydro alcoholic whole plant extract-EAHE, aqueous extract-EAAE (200mg/kg, 200 mg/kg) for 7 days, CCl<sub>4</sub> is administered on the 5day<sup>3</sup>.

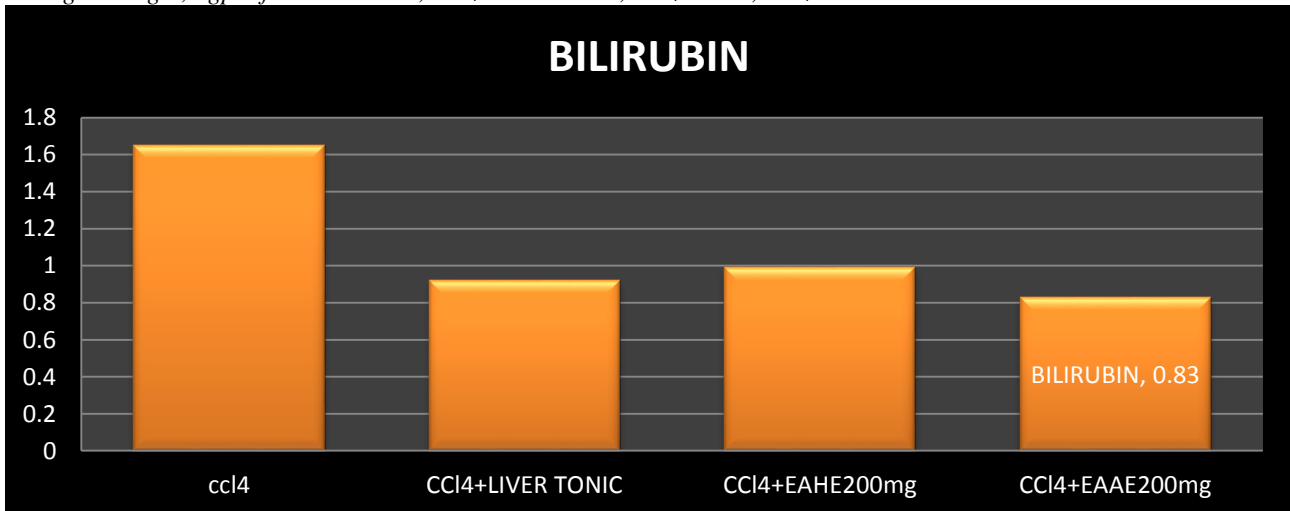
On the 8<sup>th</sup> day, all rats were sacrificed and the blood collected, centrifuged and the collected serum samples were studied for SGOT, SGPT and bilirubin (through commercially available kits) tests for the study of the toxic effect of CCl<sub>4</sub> and also the therapeutic effect of the plant extracts. The livers were fixed in the fixative (Bouin's fluid) for the histological study. The results were analyzed by one way ANOVA and Dunnet multiple comparison test with the significant level at p<0.05.

### RESULTS

The results were observed that the serum parameters like SGPT values were increased in the CCl<sub>4</sub> induced rats (112.60±4.51). SGOT, bilirubin values were also indicating the damage of the liver in the CCl<sub>4</sub> induced rats



Changes In Sgot, Sgpt of Ccl4 Induced, Ccl4+Liver Tonic, Ccl4+Eahe, Ccl4+Eaae Treated Rats



Changes In Bilirubin of Ccl4 Induced, Ccl4+Liver Tonic, Ccl4+Eahe, Ccl4+Eaae Treated Rats

Table 1: Hepatoprotective Activity of *Elytraria acaulis* in CCl<sub>4</sub> induced Hepatotoxicity of Albino rats

GROUPS	SGPT ( IU/L)	SGOT (IU/L)	BILURUBIN (mg/dL)
1.CONTROL	52.73±0.73	42.66 ± 0.55	0.64±0.08
2.CCl <sub>4</sub>	112.60±4.51	102.88±1.79	1.65±0.15
3.CCl <sub>4</sub> + Liver Tonic	69.54±1.63	66.99±0.86	0.92±0.14
4.CCl <sub>4</sub> + EAHE 200mg	62.68±2.98 <sup>a</sup>	58.88±1.01 <sup>a</sup>	0.99±0.09 <sup>c</sup>
5.CCl <sub>4</sub> + EAAE 200mg	57.68±2.47 <sup>a</sup>	54.48±1.06 <sup>b</sup>	0.83±0.06 <sup>c</sup>

All values are expressed in mean ± SD; n=8, a= p <0.01 compare to CCl<sub>4</sub> induced group, b= p <0.01 compare to CCl<sub>4</sub>+ liver tonic treated group, c= not significant (p >0.05) compare to CCl<sub>4</sub>+ liver tonic treated group, EAHE- *Elytraria acaulis* hydro alcoholic extract, EAAE- *Elytraria acaulis* aqueous extract.

(102.88±1.79), (1.65±0.15) respectively. The values of SGOT (66.99±0.86), SGPT (69.54±1.63) and bilirubin (0.92±0.14) were noted in the group CCl<sub>4</sub> + Liver tonic. The decreased levels of SGPT, SGOT and bilirubin levels were seen in the CCl<sub>4</sub>+ EAHE 200 mg/kg (62.68±2.98, 58.88±1.01, 0.99±0.09), 200mg/kg (57.68±2.47, 54.48±1.06, 0.83±0.06) respectively.

## DISCUSSION

CCl<sub>4</sub> damages the liver by its metabolite CCl<sub>3</sub>· free radical, with which the damage of cellular membranes occur through the lipid peroxidation<sup>1</sup>. The serum parameters like Serum Glutamate Oxaloacetic Transaminase (SGOT) or Aspartate Transaminase (AST), Serum Glutamate Phosphate Transaminase (SGPT) or Alaline transaminase (ALT), including the bilirubin content also elevated because of their release into the blood in the CCl<sub>4</sub> induced hepatotoxic rats<sup>4</sup> (Table-1). Whereas, the EAHE, EAAE treated rats' serum parameters revealed the significant decrease in the SGOT (66.99±0.86), SGPT (69.54±1.63) and bilirubin (0.92±0.14) levels compare to the CCl<sub>4</sub> induced rats (Table-1). These enzymatic values were also decreased in the liver tonic treated rats. The hepatoprotection of the drug depends on the reduced effects of toxic levels of the CCl<sub>4</sub> in the damaged liver<sup>12</sup>. The results that decreased levels of SGOT, SGPT and bilirubin in the EAHE, EAAE treated rats against CCl<sub>4</sub> were observed similar to the results of the hepatoprotective activity of poly herbal drug against CCl<sub>4</sub> damaged liver<sup>14</sup>.<sup>9</sup> The histological sections are also revealed that the hepatocellular damage in the CCl<sub>4</sub> induced hepatotoxic group (group- 2) (figure-1). The EAHE + CCl<sub>4</sub>, EAAE + CCl<sub>4</sub> (200mg/kg, 200mg/kg) i.e., group-4, group-5 were showed the rearrangement of damaged cells. The histology is more observed in the group – 5 (figure 3, 4). The histology can be easily comparable with the liver tonic+ CCl<sub>4</sub> group rats.

The results that observed were supporting the protective activity of the liver though they were damaged by the CCl<sub>4</sub>. The plant extract of *Elytraria acaulis* are shown more protectiveness. Though the results are supporting the hepatoprotective activity further study is needed to confirm the activity.

## ACKNOWLEDGEMENT

One of the author R.Vijay Kumar, grateful to the Department of Science and Technology, New Delhi for awarding INSPIRE Research fellowship.

## REFERENCES

1. Brattin WJ, Glend FA Jr, Recknagel RO. Pathological mechanism in carbon tetrachloride hepatotoxicity. *Journal of Free Radical Boil Med* 1985; 1: 27-28.
2. Chaudhari BP, Chaware VJ, Joshi YR, Biyani KR. Hepatoprotective activity of hydroalcoholic extract of *Momordica charantia* Linn. leaves against Carbon tetra chloride induced hepatopathy in rats. *International J of Chem Tech Research* 2009; 2: 355-358.
3. Chowdhary GD, Kamboj P, Singh I, Kaila. AN. Herbs as liver savers – A review. *Indian J. of Natural Products and Resources* 2010; 14: 397-408.
4. Durga Prasan Nayak SC, Dinda PK, Swain B, Kar VJ, Patro NM. Hepatoprotective activity against CCl<sub>4</sub>-induced hepatotoxicity in rats of *Chenopodium album* aerial parts. *Journal of Phytotherapy and Pharmacology* 2012; 2: 33-41.
5. Jeong HG, You HJ, Park SJ, Moon A, Chung YC, Kang SK, Chun HK. Hepatoprotective effects of 18-glycerrheinic acid on carbon tetra chloride induced Liver injury: Inhibition of cytochrome P450 2E1 expression. *Pharmacological Res* 2002; 46: 221-227.
6. Kavitha. BT, Shruthi SD, Padmalatha Rai S, Ramachandra. YL. Phytochemical analysis and hepatoprotective properties of *Tinospora cordifolia* against carbon tetrachloride-induced hepatic damage in rats. *Journal of Basic and Clinical Pharmacy* 2011; 2(3):139-142
7. Mascolo N, Sharma R, Jain SC, Capasso F. Ethnopharmacology of *Calotropis Procera* Flowers. *Journal of Ethnopharmacol.* 1998; 22(2): 211-21.
8. Prabhat Kumar das, Prasanna Panda, Somya Ranjan Pani, Ranjan Sethi. Hepatoprotective activity of Plant *Argemone mexicana* (Linn) against CCl<sub>4</sub> induced hepatotoxicity in rats. *International J of Pharmaceutical Research and Development* 2009; 8:1-20.
9. Rajesh Kumar, Sushil Kumar, Arjun Patra, Jayalakshmi.S. Hepatoprotective activity of aerial parts of *Plumbago zeylanica* linn, against CCl<sub>4</sub> induced hepatotoxicity in rats, *International J of pharmacy, Pharmaceutical Sciences* 2009; 1(1):171-175.
10. Ruby K, Koshy, Raj Kapoor Band, Mohammad Azamthulla. Anti Hyperglycemic Activity of *Elytraria acaulis* Lind. On Streptozotocin- Induced Diabetic Rats. *Med Aromat plants* 2012; 1: 103-107.
11. Satheesh Kumar B, Sathyanarayana J, Krishna Reddy M and Prasad MSK. Evaluation of hepatoprotective

- activity of aqueous extract from leaves of *Solanum americanum*. International J. of Plant Animal and Environmental Sciences 2011; 1(2):150-154.
12. Siddhatha Singh, Archana Mehta and Pradeep Mehta. Hepatoprotective activity of *Cajanus cajan* against CCl<sub>4</sub> induced liver damage. International J. of Pharmacy and Pharmaceutical Sciences 2011; 3(2):146-147.
  13. Venkatesalu V, Gopalan N, Pillai CR, Singh V, Chandrasekaran M, Senthilkumar A, Chandramouli N. In vitro anti-plasmodial activity of some traditionally used medicinal plants against *Plasmodium falciparum*. Parasitol Res 2012, 111(1): 497-501.
  14. Vilas A, Arsul RO, Ganjiwale PG, Yeole. Phytochemical and pharmacological standardization of polyherbal tablets for hepatoprotective activity against carbon tetrachloride induced hepatotoxicity. International J of Pharmaceutical Sciences and Drug Research 2010; 2(4): 265-268.
  15. Zahara K, Malik MA, Mughal MS, Arshad M, Sohail MI. Hepatoprotective role of extracts of *Momordica charantia*.L. in Acetaminophan – induced toxicity in rabbits. The Journal of Animal and Plant Sciences 2012; 22(2):273-277.