

Effect of Euphorbia Prostrata on the Wound Healing in Excisional Wound Model in Rats

T R Patil*, R P Limaye

Department of Pharmacology, Bharati Vidyapeeth Deemed University Medical College & Hospital, Sangli – 416 414.

Received: 23rd July, 17; Revised 3rd Sept, 17, Accepted: 16th Sept, 17; Available Online: 25th Sept, 17

ABSTRACT

Background-Euphorbia prostrata possesses many actions one of which is wound healing. Skin wound healing is a significant health care problem which clinician faces still. Hence this study was planned to evaluate effect of euphorbia prostrata on skin wound healing. Material and methods-This study was conducted among randomly selected wistar rats (n=6 per group). Group A and Group B had Cream and 1% euphorbia prostrate cream applied topically on the excisional wound respectively. Wound healing and epithelisation was assessed on Days 4,8,12,16,20. Results: Group A showed an average wound size of 348±13.0 on day 4, 278±10.5 on day 8, 119±9.8 on day 12, 86±9.2 on day 16 and 100% wound healing was observed day 20 onwards. Group B showed an average wound size of 296±11.0 on day 4, 147±9.5 on day 8 and complete wound healing was observed day 12 onwards in the test group. Conclusion: Euphorbia prostrata holds promise as effective drug therapy for wound healing.

Keywords: Euphorbia Prostrata, wound healing, epithelisation

INTRODUCTION

Wound creates an anatomical discontinuation in the tissues leading to disturbed functions which might result in to pathological complications if not treated adequately in time¹. Healing of wound results in to restoration of physical and functional integrity as a result of complex processes at the site of wound. The healing of wound undergoes stages like haemostasis,² inflammation,³⁻⁵ proliferation and remodeling⁵.

With proper and meticulous treatment the wound heals uneventfully, the failure of which might result in to impaired wound healing and complications arising out of its chronicity. Still the treatment of wound is not very satisfactory and poses many challenges for the clinicians. This invites the trial and introduction of newer agents in this field.

Euphorbia prostrata has been tried very successfully for the treatment of haemorrhoids either with local application or by per oral therapy⁶. The studies are lacking in the field of skin wound healing with this drug, regarding its wound healing property. Hence this study was undertaken to confirm the skin wound healing potential of this agent.

Euphorbia prostrata is perennial herb belonging to family euphorbeaceae, found abundantly in India and Africa. Since long it has been recommended for gastro intestinal disorder like diarrhoea⁷, asthma and allergy⁸, diabetes mellitus^{9,10} haemorrhoides^{11,12} It contains flavonoids, phenolic compounds and tannins^{13,14} which possess anti inflammatory, anti oxidant, analgesic, anti histaminic, haemostatic and wound healing property¹⁵⁻¹⁹.

Material and methods-

This study was carried out in the department of pharmacology and central animal house Bharati vidyapeeth deemed university medical college and hospital sangli after getting approval from institutional animal ethical committee.[IAEC]

Study was conducted in two groups of wistar rats, selected randomly each consisting of 6 animals and every rat weighing between 200-250gms. Two groups of six rats were selected one as control group A-only cream base and second group B for test drug euphorbia prostrata cream to be applied locally. Each animal was housed separately in an individual cage. Light and dark cycle was maintained. They had free access to standard pellet diet and water ad libitum except 12 hours prior to the creation of wound and until rat regained full consciousness after the wound creation. Experiments were carried out between 9.00 to 16.00 hours.

Back of rats were shaved and on the next day surgical intervention was carried out under general anaesthesia with Thiopental sodium in the dose of 25mgms/kg body weight. 500mm² full thickness circular skin was excised with scalpel blade over the nape of neck. Control animals were treated with local application of cream base and test animals received local application of 1% Euphorbia prostrata cream. Drug and cream application was carried out from the next day of wounding and was continued till the epithelisation with no raw area left behind. Wound area was traced on polythene paper and was measured with the help of planimeter.

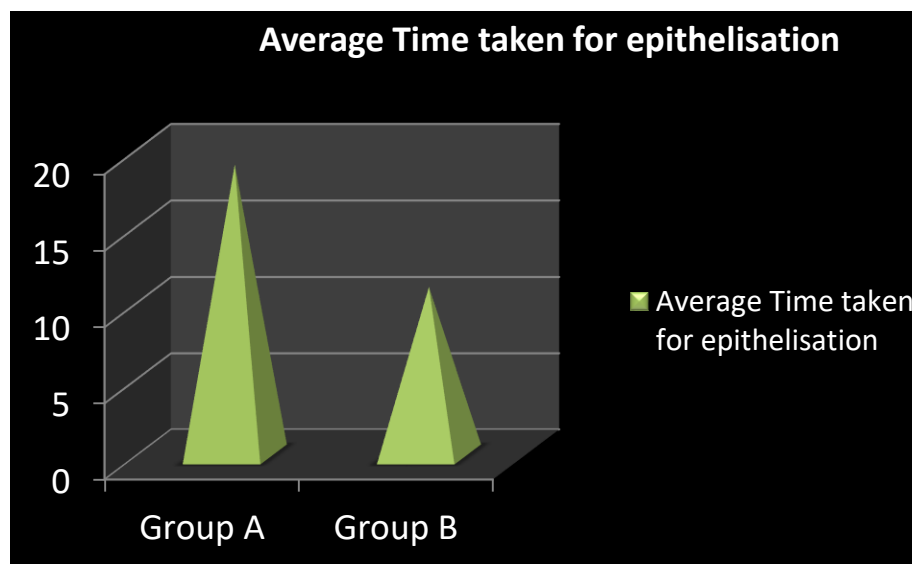
Two parameters studied were wound size measurement and period of epithelisation. Size of wound was measured

Table 1: Comparison of average wound measurement between the control and test group.

Groups	Wound area mm ²			
	Day 4	Day 8	Day 12	Day 16
Group A (control group)	348±13.0	278±10.5	119±9.8	86±9.2
Group B (test group)	296±11.0	147±9.5	Complete wound healing (0.0±0.0)	-
P value	< 0.001*	<0.002*	<0.003*	< 002*

* p value <0.05 is considered significant

Independent t test



Graph 1: Average time taken for epithelisation of wound.

from day 4th and then on day 8th, 12th and 16th and if necessary there after.

Period of epithelisation was observed in days.

Statistical analysis was carried out by independent t test to compare the wound healing i.e average wound measurements and average time of epithelisation between the control and test group. Probability of $p < 0.05$ was considered to be significant. All the analysis was conducted using SPSS ver 13.0.

RESULTS

Group A showed an average wound size of 348±13.0 on day 4, 278±10.5 on day 8, 119±9.8 on day 12, 86±9.2 on day 16 and 100% wound healing was observed day 20 onwards. Group B showed an average wound size of 296±11.0 on day 4, 147±9.5 on day 8 and complete wound healing was observed day 12 onwards in the test group. Independent t test results showed a statistically significant difference in the average wound measurements between both the groups at day 4, 8, 12, 16. (table 1). The average time taken for epithelisation of the wound was found to be on average of 19 ± 1.0 for group A and 11 ± 1.0 for group B. Independent t test shows a significant difference between the average time taken for epithelisation of the wound between group A and Group B. ($p = 0.01$) (Graph 1)

DISCUSSION

In our study group B of rats treated with euphorbia prostrata cream locally on wound had accelerated wound healing as compared to control group A of animals. The

possible mechanisms for this wound healing property are based on constituents of euphorbia prostrata and on spectrum of their actions. Euphorbia prostrata is approved by the drugs controller general of India [DCGI] and it also patented in US and European countries regulated markets for the treatment of haemorrhoids and colonic diseases²⁰. It contains flavonoids, phenolic compounds and tannins as active principles. They have been found to have various properties as follows.

Flavonoids contain constituents like apigenin, apigenin-7-glucosides, luteolin and luteolin-7-glucosides. Constituents of phenolic compounds are gallic acid and ellagic acid. Flavonoids have anti inflammatory, anti oxidant, analgesic, anti allergic, anti oedema and wound healing actions. Phenolic compounds possess anti oxidant, anti inflammatory, hemostatic and anti allergic actions. Tannins bear astringent, hemostatic and wound healing properties¹⁵.

Anti inflammatory actions of flavonoids like apigenin and luteolin and phenolic compound ellagic acid is exhibited through inhibition of activation of inducible nitric acid synthase [iNOS] and of cyclooxygenase 2 [COX-2] in macrophages. TNF alpha stimulated up regulation of ICAM-1 and VCAM-1 and E selectin mRNA was found to be reduced by apigenin^{12,21-22}. Luteolin inhibits pro inflammatory cytokine production and nuclear kappa B mediated gene expression along with increase in anti-inflammatory cytokine-IL 10 expression^{23,16}.

IL-1 beta mediated expression of adhesion molecule is inhibited by ellagic acid²⁴. Thus they inhibit the activation, migration and adhesion of leucocytes and production of

various inflammatory mediators and cytokines. Oral administration of euphorbia prostrata was found to reduce carragennan and also histamine induced oedema¹⁷.

Antioxidant activity of ellagic acid and luteolin is through the inhibition of lipid peroxidation and generation of free radicals. They also increase enzyme glutathione reductase and reduced glutathione resulting in to increased free radical scavenging and reduction in free radical species. Levels of other antioxidant enzymes like catalase and superoxide dismutase are also increased^{25,26}.

Astringent action of tannins precipitate the surface proteins and they also have hemostatic activity which contribute to their wound healing property¹⁶. Tannic acid was reported to have antimicrobial action which is associated with ester linkage between gallic acid and other sugars or alcohol groups²⁷. Aqueous extract of euphorbia prostrata has been found to have potential activity against salmoniasis including typhoid fever²⁸. Similarly in vitro antimicrobial activity of euphorbia prostrata was proved against s.typhi, s.paratyphi A, s.paratyphi B and s.typhi murinum²⁹.

Hemostatic activity of ellagic acid is by activation of factor XII-Hageman factor and enhancement of intrinsic blood coagulation^{30,31}.

Flavonoids and tannins exert analgesic activity through inhibition of phospholipase A-2 and COX-2 and reduced prostaglandin synthesis³².

Release of histamine is suppressed by phenolic compounds like gallic acid and ellagic acid. Flavonoids also inhibit lipooxygenase-A-2 and leucotrienes which are the important mediators of allergic phenomenon. They also reduce the production of IgE by inhibiting IL-4,IL-13 and CD 40^{33,34}.

Euphorbia prostrata improves venous tone and lymphatic drainage, protects capillary bed microcirculation and reduces their permeability and exudation from capillaries.^{12³⁰}

Thus all these above mentioned actions of euphorbia prostrata contribute for wound healing. Though euphorbia prostrata is used locally for the treatment of haemorrhoids it holds a good potential to be used for skin wound healing. Toxicological studies done with aqueous extract of euphorbia prostrate proved it to practically safe as LD₅₀ values for extract were 23.2gms/kg for female and 26.4gms for male mice²⁹. Hence safety of its is confirmed. Thus euphorbia prostrata holds promises as effective and safe drug therapy for wound healing.

REFERENCES

- Clark RA. Basis of cutaneous wound repair. J dermatol. Surg. Oncol 1993;19:693-706.
- Degreef H. how to heal a wound fast. Dermatol Clin. 1998; 16: 365-75.
- Hunt TK. The physiology of wound healing. Ann Emerg Med. 1998; 17: 1265-73.
- Guo S, Dipetro LA. Factors affecting wound healing. J Dent Res 2010; 89: 219-29.
- Witte MB, Barbul A. general principles of wound healing. Surg. Clin North Am 1997; 77: 509-28.
- Gupta PJ. The efficacy of Euphorbia prostrata in early grades of symptomatic hemorrhoids – a pilot study. European Review for Medical and Pharmacological Sciences 2011;15:199-203.
- Rene K, Hortense GK, Pascal W, Alexis MNJ, Vidal PE, Archange FTM. Activity of aqueous ethanol extract of Euphorbia prostrata Ait on Shigella dysenteriae type 1-induced diarrhea in rats. Indian J Pharmacol 2007;39(5):240-44.
- Sharma GD, Tripathi SN. Experimental evaluation of dugdhika (Euphorbia prostrata W.Ait.) for the treatment of 'tamaka svasa' (bronchial asthma). Ancient Sci Life 1984;3(3):143-50.
- Akhtar MS, Khan QM, Khaliq T. Effects of Euphorbia prostrata and Fumaria parviflora in normoglycaemic and alloxan-treated hyperglycaemic rabbits. Planta Med 1984;50:138-42.
- Alarcon-Aguilara FJ, Roman-Ramos R, Perezgutierrez S, Aguilar-Contreras A, Contreras-Weber Cc, Flores-Saenz JI. Study of the anti-hyperglycemic effect of plants used as antidiabetics. J Ethnopharmacol 1998; 61: 101-110.
- Bakhshi GD, Langade DG, Desai VS. Prospective, Open Label Study of Euphorbia Prostrata Extract 100 mg in the Treatment of Bleeding Haemorrhoids. Bombay Hospital J 2008; 50(4):577-83.
- Singla AK, Pathak K. Topical antiinflammatory effects of Euphorbia prostrata on carrageenan-induced footpad oedema in mice. J Ethnopharmacol 1990; 29: 291-294.
- The Ayurvedic Pharmacopoeia of India, Government of India, Ministry of Health and Family Welfare, New Delhi, Vol. 5(1), 28.
- The Wealth of India, Raw Materials. Council of Scientific and Industrial Research, New Delhi;Vol. 1,346-47.
- Chen L, Chen R, Wei K. Constituents of tannins from Euphorbia prostrata Ait. Zhongguo Zhong Yao Za Zhi 1992; 17: 225-226, 255-256.
- Rizk AM, Hammouda FM, El-Nasr MM, El-Missiry MM. Constituents of Egyptian Euphorbiaceae. Part 6: phytochemical investigation of Euphorbia geniculata Jacq. and E. prostrata Ait. Pharmazie 1978; 33: 540-541.
- Mackay D. Hemorrhoids and varicose veins: a review of treatment options. Altern Med Rev 2001; 6: 126-140.
- Sumboonnanonda K, Lertsithichai P. Clinical study of the Ginko biloba-Troxerutin-Heptaminol Hce in the treatment of acute hemorrhoidal attacks. J Med Assoc Thai 2004; 87: 137-42.
- La Torre F, Nicolai AP. Clinical use of micronized purified flavonoid fraction for treatment of symptoms after hemorrhoidectomy: results of a randomized, controlled, clinical trial. Dis Colon Rectum 2004; 47: 704-10.
- Porwal A, Khobragade K, Jagtian S. Euphorbia Prostrata - A Clinically Proven Drug in Hemorrhoids – Multiple Pharmacological Actions Targeting Pathological Processes. Int J Med Health Sci. April 2015, 4: 269-273.

21. Singla AK, Pathak K. Anti-inflammatory studies on *Euphorbia Prostrata*. *J Ethnopharmacol* 1989; 27(1-2): 55-61.
22. Lee JH, Zhou HY, Cho SY. Anti-inflammatory mechanisms of Apigenin: inhibition of cyclooxygenase-2 expression, adhesion of monocytes to human umbilical vein endothelial cells, and expression of cellular adhesion molecules. *Arch Pharm Res* 2007; 30(10): 1318-27.
23. Ziyang L, Yongmei Z, Nan Z. Evaluation of the anti-inflammatory activity of luteolin in experimental animal models. *Plant Med* 2007; 73(3): 221-2.
24. Yu YM, Wang ZH, Liu CH. Ellagic Acid inhibits IL-1 beta-induced cell adhesion molecule expression in human umbilical vein endothelial cells. *Br J Nutr* 2007; 97(4): 692-8.
25. Majid S, Khanduja KL, Gandhi RK. Influence of ellagic acid on antioxidant defence system and lipid peroxidation in mice. *Biochem Pharmacol* 1991; 42(7): 1441-5.
26. Leung H, Kuo CL, Yang WH, Lin CH, Lee HZ. Antioxidant enzyme activity involvement in luteolin induces human lung squamous carcinoma CH27 cell apoptosis. *Eur J Pharmacol* 2006; 534: 12-8.
27. Lyseng-Williamson KA, Perry CM. Micronised purified flavonoid fraction: a review of its use in chronic venous insufficiency, venous ulcers and haemorrhoids. *Drugs* 2003; 63: 71-100.
28. Tala D. In vivo anti salmonella activity of aqueous extract of *euphorbia prostrata aiton* and its toxicological evaluation. *Asian Pac J of Trop Biomed* 2015; 5: 310-318.
29. Kengni F, Tala D.S. In vitro antimicrobial activity of *harugnana madagascensis* and *euphorbia prostrata* extract against some pathogenic salmonella species. *Int.J.Biol.Chem.Sci* 2013; 7[3]: 1103-1116.
30. Sanchez C, Chinn B. Hemorrhoids. *Clinics in Colon and Rectal Surgery* 2011; 24: 5-13.
31. Girolami A, Clifton EE. Hypercoagulable state induced in humans by the intravenous administration of purified ellagic acid. *Thromb Diath Haemorrh* 1967; 17(1-2): 165-7.
32. MacKay D. Hemorrhoids and varicose veins: a review of treatment options. *Altern Med Rev* 2001; 6: 126-40.
33. Kim SH, Jun CD, Suk K. Gallic acid inhibits histamine release and pro-inflammatory cytokine production in mast cells. *Toxicol Sci* 2006; 91(1): 123-31.
34. Kawai M, Hirano T, Higa S, Arimitsu J, Maruta M, Kuwahara Y, et al. Flavonoids and related Compounds as Anti-Allergic Substances. *AllergolInt* 2007; 56: 113-23.