

The Toxicity of Castor Beans and its Treatment with Doxycycline in Local Rabbits

Nael Mohammed Sarheed¹, Osamah Faisal Kokaz¹, Doaa Abd Alabas Muhammed Ridh³

^{1,2}Medicine College / AL-Muthanna Uni.

³Science College / University of Al-Qadisiyah/Iraq

Received: 06th July, 19; Revised: 04th August, 19, Accepted: 08th September, 19; Available Online: 25th September, 2019

ABSTRACT

The plant of castor is widely spread in the Iraqi land and characterized by containing ricin toxin, which has a severe effect, and because the seeds of this plant scattered in the agricultural soil and rivers water, which increases the exposure of humans and animals to these beans.

Objective: This experiment was designed to study the effect of high concentration of castor bean powder in some physiological and biochemical parameters and changes in some tissues of the body, as well as trying to use doxycycline to reduce the effects of ingestion of these seeds.

Materials and Methods: In the experiment, 24 local rabbits were raised and fed in the Animal House, Faculty of Medicine/ Al-Muthanna University, then divided into four groups and treated for three weeks (21 days), Control group: treated with normal saline solution (0.9) orally throughout the experiment, G1: was treated orally with a concentration of 25 mg/kg of castor bean powder daily during the experiment, G2: orally treated 25 mg/kg of castor bean and 25 mg/kg of doxycycline, G3: orally treated 25 mg/kg of castor powder with 50 mg/kg of doxycycline daily throughout the trial period.

Results: The results of the experiment showed significant changes ($P < 0.05$) in all physiological and biochemical blood tests when compared with the control group. There was a significant decrease in PCV, Hb, RBC, T.protein, and body weights while demonstrated a substantial increase in white blood cell (WBC), Urea, Creatinine, ALT, AST, and ALP, with distortions in liver and kidney of animals that treated with Castor beans.

In contrast, the treatment with doxycycline and castor beans showed significant improvement reflected by normal proportions in physiological tests and biochemical tests with improvement in the tissues when compared to the control group.

Conclusions: It can be concluded from this study that castor bean has high toxic and pathogenic effects that may be dangerous to the life of the organism. Therefore, it is advisable to be cautious of these pills and avoid exposure to them, also recommended to take high concentrations of doxycycline treatment when infected with castor bean poisoning.

Keywords: Blood parameters, Castor, Doxycycline, Histology sections, Rabbits.

International Journal of Pharmaceutical Quality Assurance (2019); DOI: 10.25258/ijpqa.10.3.14

How to cite this article: Sarheed, N.M., Kokaz, O.F. and Muhammed Ridh, D.A.A. (2019). The toxicity of Castor beans and its treatment with Doxycycline in local rabbits. International Journal of Pharmaceutical Quality Assurance 10(3): 12-21

Source of support: Nil

Conflict of interest: None

INTRODUCTION

The plant of castor (*Ricinus communis*) is a plant from the family of Euphorbia, which consists of leaves with five cloves and seeds containing the world-famous oil called castor oil, where the seed contains about 40-50% of its weight oil, which is non-toxic.^{1,2} Castor seeds also contain a substance called ricin, which is highly toxic, dissolves in water and is not soluble in oil, and is considered the deadliest on earth. The ingestion of one fruit is enough to kill an adult in a few minutes.^{3,4} This substance has been considered as a deadly poison by the Center for Disease Control and Prevention (CDC) and has been described as carcinogenic or lethal.^{2,5} Where the death of many cattle when taken for a few seeds of castor as a source of food during the experiment of one of the researchers who

faced challenges related to changes in the tissue and damage to some members of the body in animals after the presence of a proportion of proteins in these seeds up to (38–42%), which later found that the content of ricin in each grain reached (9.3 mg/g) and had a clear effect on the cells of the mammalian.^{1,6} Also mentioned⁷ the presence of high toxicity of castor bean during an experiment on mice for several plants showed their toxicity by digestion, and said.² Exposure to the castor plant during digestion is more dangerous than inhalation or injection, and digestion of approximately five beads may be lethal dose with the observation that some of this amount is analyzed by the effect of gastric acid.⁸ In addition, many researchers found that ricin toxin is one of the deadly toxins used in biological weapons. It has been used in wars after being extracted from

*Author for Correspondence: Nael.serheed@mu.edu.iq

castor beans and documented as a deadly toxin by means of digestion and inhalation.⁹⁻¹¹

The ricin toxin is found in two units, a series that inhibit the protein synthesis, and B series, which are linked to the Galactose ligand on the cell membrane surface of animal cell,^{11,12} this type of toxin enters the intestinal region in a chewing or crushing manner leading to serious toxicity symptoms, especially in the gastrointestinal tract (GIT),¹³ the method of exposure to castor bean has a significant role in the effect of toxin, inhalation of a small amount of ricin toxin leads to severe respiratory damage or death, which LD50 described in an experiment on mice 3-10 mg/kg when inhaled or injected, and 30 Mg/kg when chewing or digestion of plant castor seeds.¹⁴ This substance has also shown other symptoms in animals because of its deposition on the leaves of plants used for nutrition such as nausea, diarrhea, vomiting, abdominal pain, inflammation, bleeding in the GIT area, blood decomposition and low sugar,^{2,15} ribonucleic acid (RNA) is analyzed in a base environment leading to the death of the animal cell,⁸ in addition to bardy cardia, sinus, irregular heartbeat, arrhythmic pulmonary edoma and severe respiratory distress.¹⁶ As a medical procedure, plasma was substituted for infected children, which resulted in the disappearance of symptoms and regularity of organs,⁸ also noticed¹⁵ the presence of an area called sarcin ricin loop (SRL), which is very important for the work of the ribosome by facilitating the correlation and activating the transmission of GT Pases that regulate protein synthesis.

According to some sources, the use of tetracycline treatments may reduce and weaken the toxic effect of ricin in the castor plant and prevent infection in many organs, such as liver and lung.⁷ Other studies indicate that no effective treatment of the toxic effects of ricin in castor beans has been achieved.^{11,15} This study was conducted to investigate the pathological changes resulting from exposure to castor bean to increase the knowledge and health awareness of the plant's risk, as well as to test the use of doxycycline to treat or mitigate the pathogenic effects.

MATERIALS AND METHODS

Experiment Design

The experiment was conducted at the Animal House of the Faculty of Medicine at Al-Muthanna University. Twenty-four local male rabbits, weighting (1000-1600g), were used at ages not exceeding one year and three months. They were placed in iron cages and subjected to similar conditions of water, food, and temperature. After that the animals were left for a week for adaptive to the experiment conditions, the concentrations of castor bean (*Ricinus communis*) and doxycycline were prepared through a series of dilution according to the required concentrations. The animals were then treated orally for three weeks, randomly divided into four main groups (each group 6 animals), as follows: Control group was treated normal saline (0.9%) daily throughout the experiment period. The first treatment group (G1): The animals were orally treated with

25 mg of castor bean powder per kilogram of body weight per day throughout the experiment. The second treatment group (G2), treated 25 mg of castor powder and 25 mg of doxycycline orally per kilogram of body weight per day throughout the experiment. The third treatment group (G3), the animals were treated with a concentration of 25 mg of castor bean powder and 50 mg of doxycycline was given orally per kilogram of body weight per day throughout the trial period.

Physiological and Biochemical tests

The packed cell volume (PCV) and hemoglobin (Hb) was measured according to 17, the number of red blood cells (RBCs) and the number of WBCs were measured.¹⁸ The level of the biochemical parameters in this study was also measured in several ways, level of urea and creatinine in the blood of treated animals measured by¹⁹ while liver function (ALP, AST, ALT) was measured according to,²⁰ and the total protein level (T. protein) was measured in the blood of experimental animals in a method.²¹

Histological Study

The histological sections of the studied organs in treated animals (liver, kidney, and lung) was performed according to method.²²

Statistical analysis

Used the Statistical Package for the Social Sciences (SPSS) program and the probability level 0.05 in the statistical analysis, then t-test to find the significant differences between the treated and control groups.²³

RESULTS AND DISSECTION

Physiological tests

The results showed a significant decrease in the most physiological parameters of experimental animals treated with castor bean. Where considerable decrease was observed ($p < 0.05$) in PCV (Figure 1) and Hemoglobin (Figure 2) for the first group, also appeared significant decrease for the number of PBCs (Figure 3) for the animals treated with castor beans when compared to the control group. After treatment with Doxycycline addition to castor beans on doses (25, 50 mg/

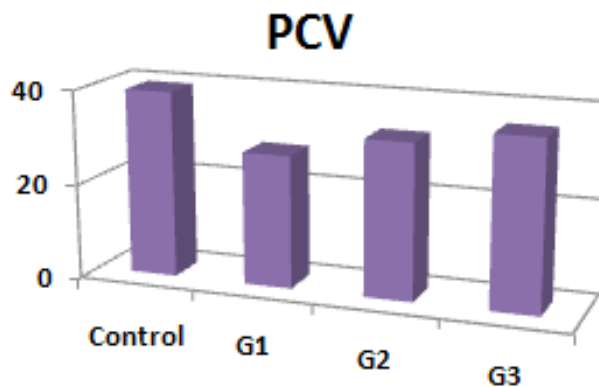


Figure 1: The changes in PCV test

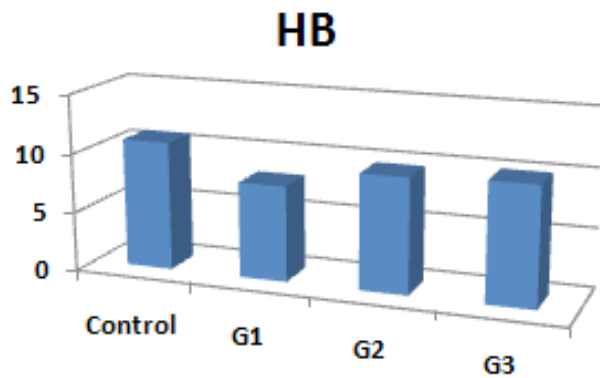


Figure 2: The changes in Hb test

kg), there were no significant differences in PCV, Hb, and RBCs when compared to the control group. According to some sources, the treatment of castor bean leads to the decomposition of blood cells in general, which leads to a decrease in red blood cells count and hemoglobin after days of treatment by agglutination and hemolysis^{24,25} and this decrease may be due to an imbalance in the amount of blood plasma that results from treatment with Castor plant, which results disruption in the work of blood cells and different in natural proportions,²⁶ also these changes may be due to the effect of ricin on the liver, bone marrow and the production of erythropoietin from the kidney²⁷ which is the most acceptable reason, this was confirmed by¹⁶ the emergence of a decline in the proportions of physiological parameters, especially red blood cells due to histological changes after exposure to castor bean while the improvement in physiological parameters after treatment with doxycycline may be due to its role as an against to the action of ricin by reducing its toxicity, which reduces tissue and physiological changes within hours of use.⁷

The results also showed a significant increase ($p < 0.05$) in the number of WBCs (Figure 4) for animals treated with castor bean for the first group when compared statistically to the control group, while a slight decrease in the number of white cells was observed after treatment with doxycycline and castor beans in the second group, which did not reach the normal proportions as in the third group when treated with a higher concentration of Doxycycline when comparing the two groups

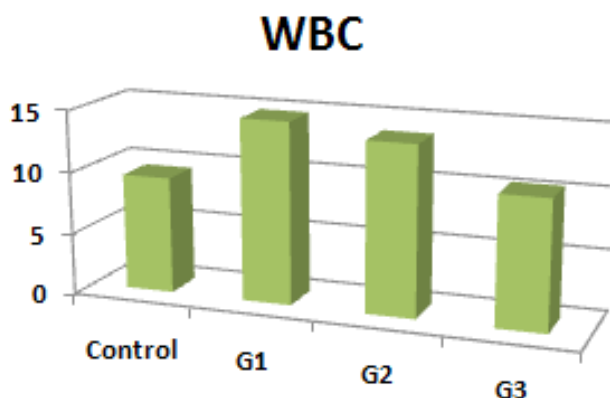


Figure 4: The changes in WBC test

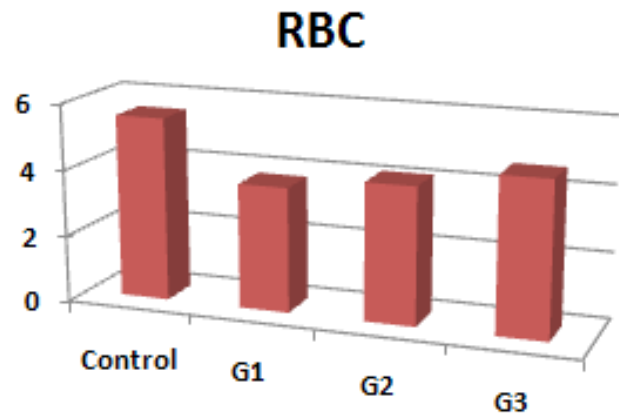


Figure 3: The changes in RBC test

with control group. The increase in the counting of white blood cells in the first group may be due to the occurrence of high inflammation after treatment with castor beans, which result from the occurrence of pathological changes in many organs, including liver and kidney,⁹ which emerged clearly in this study. As for the decrease in white blood cells of the second and third groups may result from the role of doxycycline in the treatment of inflammation and damage in the tissue by its role as an anti-inflammatory.²⁸

Biochemical tests

During the statistical analysis of the results in Biochemical tests was observed that the majority of the tests were observed increased after treatment with castor bean, where the results of liver function enzymes ALT, AST (Figure 5) and ALP (Figure 6) showed significant increase ($p < 0.05$) in the first group when treated with 25 mg/kg of castor beans, there was also a significant increase in these enzymes for the second group treated with doxycycline with a concentration of 25 mg/kg, while no significant difference of these enzymes was shown in the treatment with a higher concentration of doxycycline in the third group when compared with the control group. The researchers reported a rise in liver enzymes when exposed to

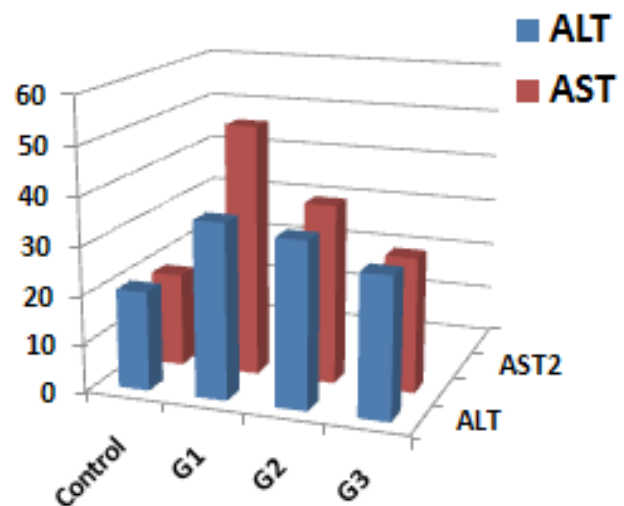


Figure 5: Changes in ALT and AST tests

castor seeds,²⁹⁻³⁰ noting¹⁴ that the proportions of ALT, AST continue to rise when eating five or more beans, which may be due to the effect on the composition of certain tissues Including liver and slow to the work of heart muscle, It was also found² that the ingestion of castor beans for some adults who ate six of them with a concentration of 25 mg had a significantly higher ALP. These changes may result from apoptosis, which is due to the phosphor-calcium imbalance, the release of cytokines, and the oxidative state of the liver.²⁵ The second and third groups showed a decrease in hepatic enzymes, which may result from the action of doxycycline on the improvement of disease symptoms by maintaining adenine acid in RNA structure, which results in continuous protein synthesis by ribosomes and continuous metabolic processes across the membrane in the liver Maintaining the living cell.¹¹

As for kidney function tests, the results showed a significant increase ($p < 0.05$) in the amount of blood urea (Figure 7) and the level of creatinine (Figure 8) after treatment with castor beans in the first group, while there were no significant changes in these tests when treated with castor and doxycycline together for the second and third groups when statistically compared to the control group. Note the researcher² increased

the proportion of the functional parameters of the kidney increasingly after swallowing of castor beans to some people reviewed the hospital, which led to the increase in quantity of these substances in the urine also, It was later observed that the ricin-B binds to the galactose receptors in the renal cell membrane, leading to cell damage and death, thus disrupting the primary functions of the kidney¹² also said³¹ that the treated with castor beans is working to increase the tests of kidney functions, because of the erosion in the tissue or due to lack of urine output.³² As for the treatment of doxy-cyclen in other groups, it has a protective role for the effect of castor bean, which may be due to the prevention of High vascular permeability by vascular endothelium cadherin on epithelial cells,³³ in addition to enhancing the oxidative stress parameters and the vascular permeability of the glomerulus.^{34,35}

The data also showed a significant decrease ($p < 0.05$) in the total protein (T. protein) (Figure 9) and animal weights

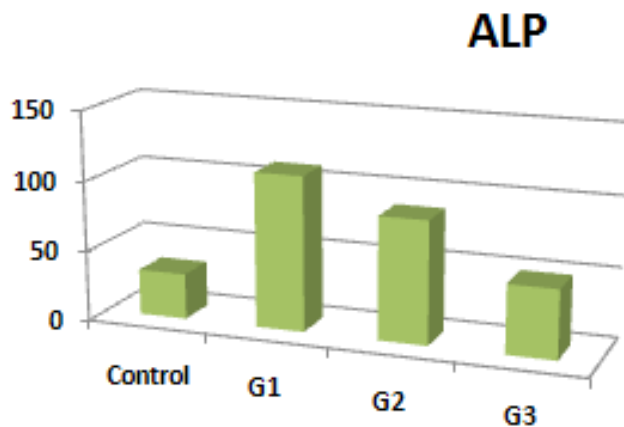


Figure 6: The changes in ALP test

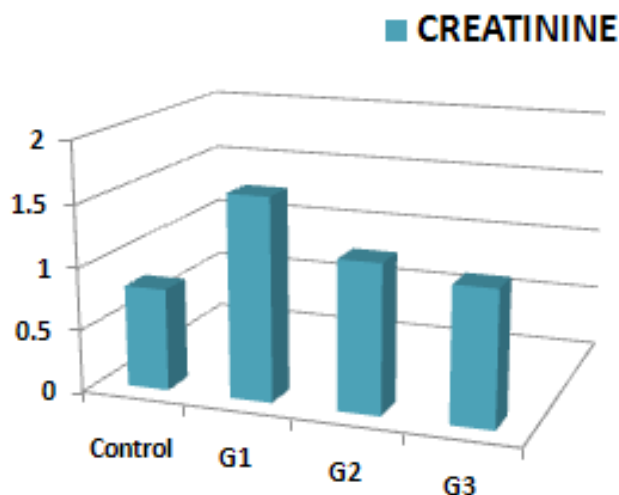


Figure 8: The changes in creatinine test

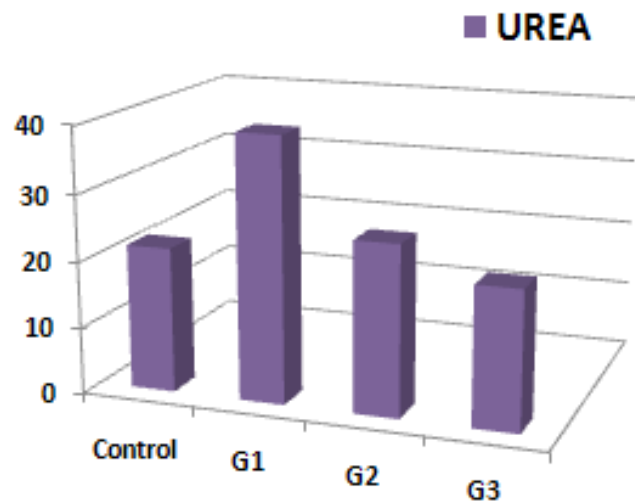


Figure 7: The changes in B. Urea test

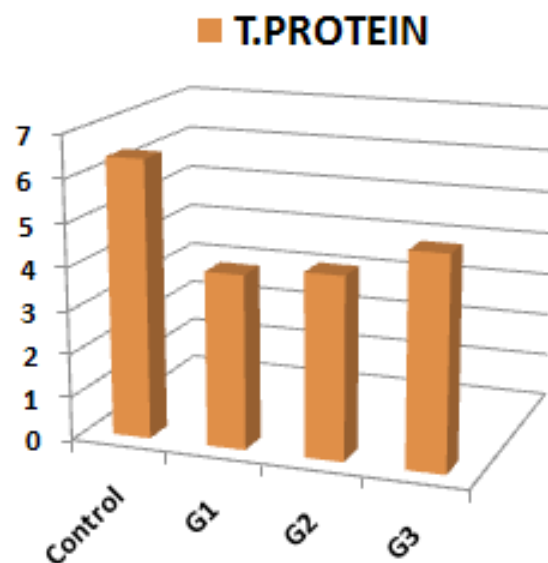


Figure 9: Changes in T.proteine test

(Figure 10) treated with 25 mg/kg of castor beans in the first group. In the second group, there was a slight increase in these tests, were not reach the normal rates when treated with doxycycline and castor beans, While the high concentration of doxycycline in the third group showed a high improvement in the total protein and the weights of treated animal bodies, there was no significant difference as for the control group. The change in total protein by castor bean is due to irregular blood plasma, which causes a decrease in the protein content inside and outside the cell,²⁶ this deficiency may also be due to the transfer of a quantity of ricin toxin to the Golgi apparatus then to the endoplasmic reticulum and then interact with the ribosome to remove adenine acid from the ribosomal Ribonucleic acid (rRNA) structure, which causes a decrease in the function of the protein synthesis,^{6,12,14} it is also possible that the cause of the reduction of protein is the damage in liver that appeared in the current study, which results in imbalance in the metabolism of proteins.³⁶ In addition, Akande, T.O. et al., 2016 and Abdulazim, S. et al., 1998 confirmed a decrease in weights of pregnant rabbit bodies treated with castor beans during 5-9 days, and the cause of the decrease in weight may be due to the damage and bleeding in the GIT and low blood sugar levels, which in turn reduces nutrients absorption and decreases the process of protein synthesis^{9,24} as can be attributed the weight changes to poor eating, loss of appetite, and severe symptoms due to ingestion of castor beans such as severe diarrhea and vomiting, which leads to the loss a large amount of body fluids.^{14,37} While the treatment with doxycycline has an important role in maintaining the composition of ribosomes and RNA strand by protecting adenine acid from damage and sustaining metabolic processes, which it was a great importance in improving total protein in the blood and maintaining body weights in animals treated with castor bean.^{11,38,39}

The results were consistent with what was mentioned⁴⁰ about the role of small concentrations of doxycycline and is not enough alone to treat the poisoning of castor beans because it works on inflammation, but the effect is less on the protein, which is strongly affected by the poison, that is one of the main causes of real damage in tissues, but here use high

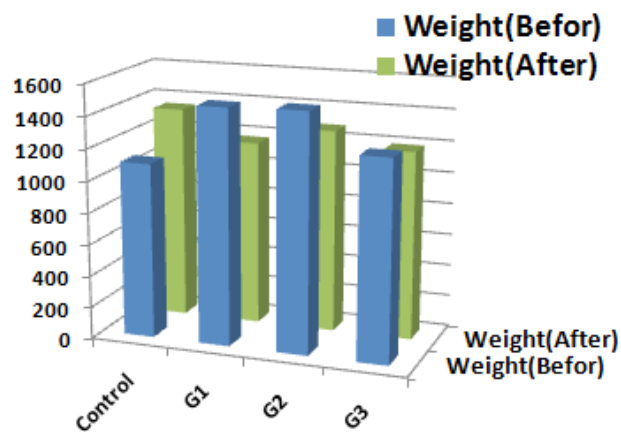


Figure 10: Changes in the weights

concentrations of doxycycline found effective and good for treating this type of poisoning in the current study.

Histological study

Liver

The examination of the tissue sections in the control group showed that the liver consists of hexagonal structures separated by the interlobular septum, each lobule has a central vein, regulate the hepatocytes around him with radial shape. In platelets separated by Hepatic Sinusoids, among these lobules, is the portal vein (Image 1). The histological sections of the liver in the first treatment group of castor beans (G1) showed significant damage to the hepatic distribution of hepatic cells around the central vein area, which showed expansion and dissection of the endothelium, and appearance of red blood corpuscles in hematopoietic areas is confined between hepatic sinusoids, with necrosis of diffuse hepatic cells and release of certain nuclei of the decomposing cells and the appearance of inflammation (Image 2). Some researchers pointed to the effect of ricin toxin on the histological structure of animal livers by influencing the ribosomes in liver cells leading to

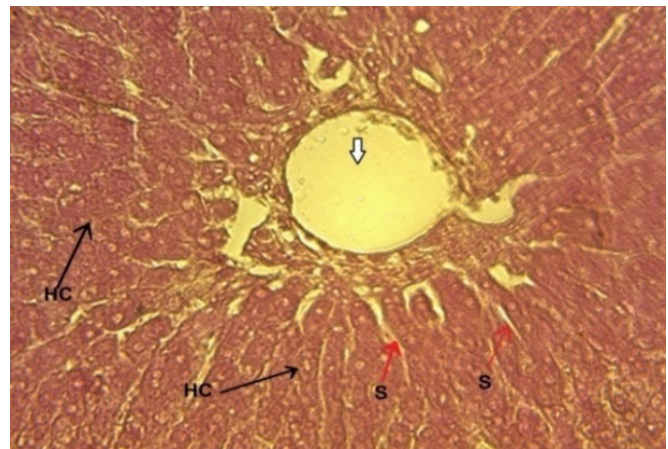


Image 1: Cross-section of Liver in control group, Central vein (White arrow), Hepatocytes (HC), of Sinusoids (S), (H&E40X).

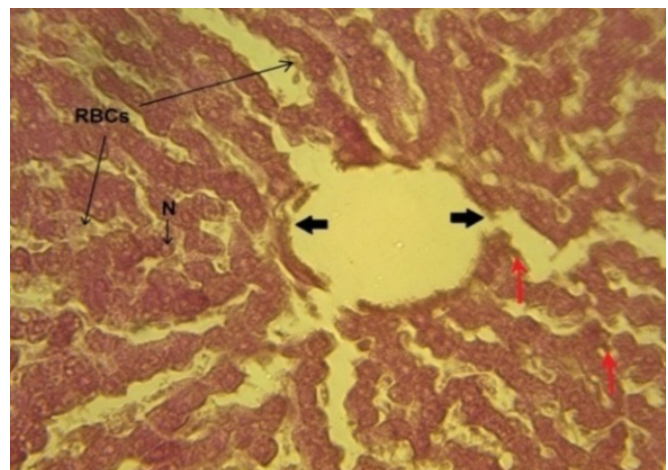


Image 2: Cross section of Liver in G1, Expansion vein & alienation of endothelium (Black arrow), Red blood cells (RBC), Necrosis (N), (H&E40X).

tissue necrosis^{41,42} where the accumulation of ricin in the liver and spleen and absorbed by the lymphatic vessels and blood after two hours of eating orally causing damage to the composition of the tissue and shows its toxic effect after that in all cells of the body^{43,44} addition to this binding of the ricin after digestion of the castor beans with the Mannose surface receptors on the kupffer cells in lining the walls of the hepatic sinusoids causes disseminated intravascular coagulation and hepatocellular necrosis,^{14,45} also mentioned⁹ the dehydration of the body tissues, especially the liver after exposure to castor seeds, which leads to the death of cells and the incidence of inflammation in nearby tissues, including GIT, and that cell death due to ricin may result from damage to the proteins and lipids of the cell membrane because of the free radicals generated by ricin toxin, which leads to Apoptosis in the cells of endothelium, epithelium, lymphoid and myeloid cells with several organs and organelles in the body.^{14,29,46}

While the use of doxycycline with castor beans in the second treatment group (G2) improved slightly by reducing the expansion of the central vein in which some inflammation and a simple death in hepatocytes, with maintaining some arrangement of radial cells around the central vein, With some erythrocyte hemorrhage being observed in sinusoids (Image 3). While the histological structure of the liver in the animals of the third group, in which use a higher concentration of doxycycline was a good improvement and a structure closer to the non-treated control group, Where observed the preservation of the radial shape was fully of hepatocytes around the central vein, disappearance of hemorrhagic cells in the sinusoids areas, scarcity of inflammation and absence of cell death (Image 4). Noted⁸ that the use of 3-azido-3 doxycycline therapy reduces the effectiveness of ricin toxin A by regulating pro-inflammatory cytokines as an antiinflammation, antioxidant, inhibitor for Matrix-metalloproteinase and reduced of hyper vascular permeability, Thus playing a role in curbing the action of free radicals.^{47,48}

Kidney

The microscopic tissue sections of the control group showed

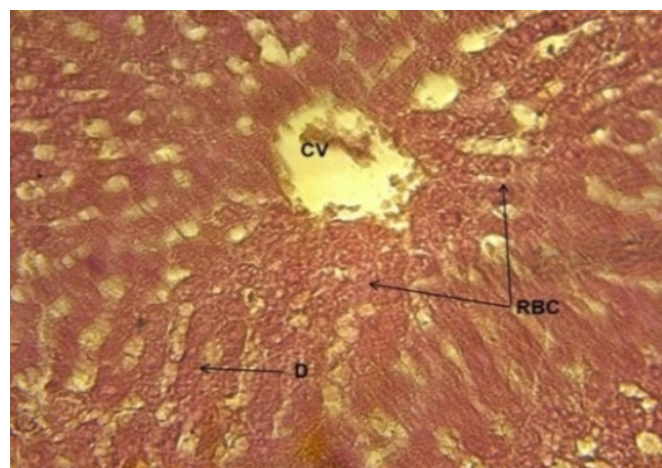


Image 3: Cross section of Liver in G2, Cell death (D), Inflammation in a central vein (CV), RBC in Sinusoids (RBC), (H&E40X).

two layers in the structure of the kidney. The inner layer consisting only of convoluted tubules called the medulla, the outer layer containing the Proximal convoluted tubules, Distal convoluted tubules, and glomerulus, Which is surrounded by a Bowman capsule called as the cortex (Image 5). While the tissue sections of the first group showed significant changes in the structure of the kidney after the animals were treated with castor powder. A large conglomeration was observed in the basic structure of the glomerulus, the expansion and dissolution of the internal tissue in the Buman capsule, Distal and Proximal convoluted tubules, breakdown of their cells, addition to the appearance of inflammation and spread of dead cells (Image 6). The kidney is one of the most important organs that is directly affected by toxins because of the filtration of blood⁴⁹ where the onset of cellular death within 48 hours followed by the breakdown of the components of the cell within six days, especially the ribosomes, which leads later to kidney failure,^{6,43} in addition to that ricin causes the oxidative stress of several cells, which confuses several mechanics inside the cell, leading to apoptosis, it also binds to the glycoprotein on the cell surface, causing damage to the membrane structure and RNA infection, producer of cell death,¹⁴ as well as high

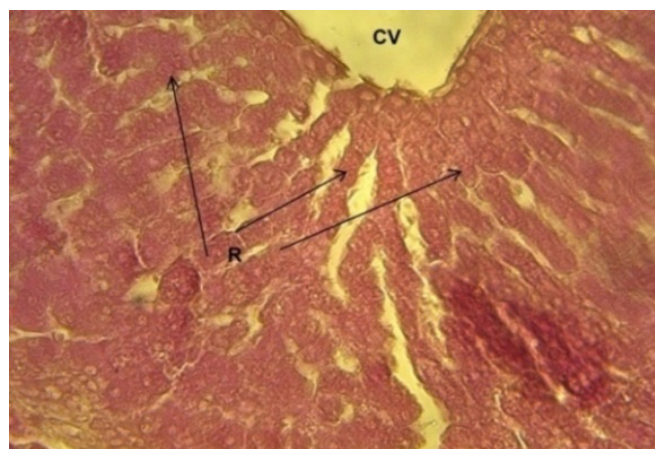


Image 4: Cross-section of Liver in G3, Radial regulation (R), Normal central vein (CV), (H&E40X)

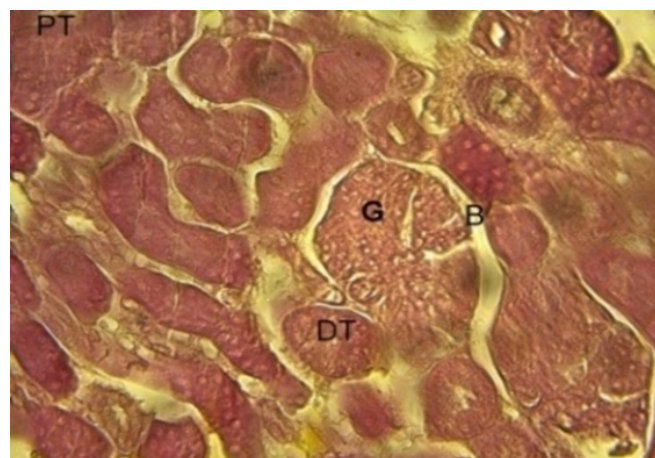


Image 5: Cross-section of Kidney (Cortex) in control Group, Glomerulus (G), Bowman capsule (B), Distal Tubule (DT), Proximal tubule (PT), (H&E40X).

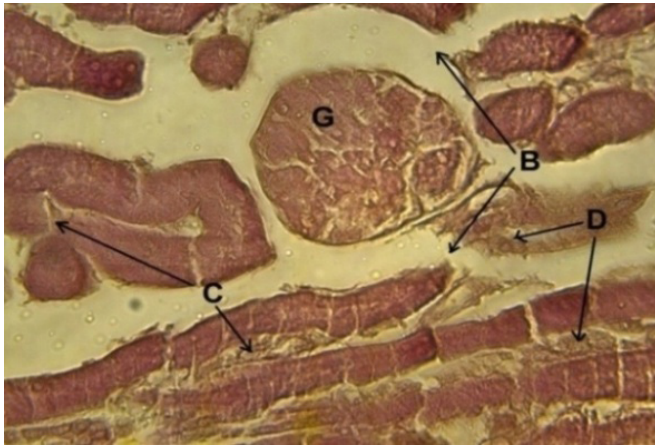


Image 6: Cross-section of Kidney (Cortex) in G1, Glomerulus conglomerate (G), Dissolution of Bowman capsule (B), Damage of tubules (C), Dead cells (D).

damage resulting from toxicity, which causes Nephritis and kidney necrosis, which ends with renal insufficiency then renal failure.^{30,46}

In the second group, the tissue sections were less affected after treatment with a concentration of 25 mg/kg of doxycycline, although there were satisfactory changes, the conglomerate appeared in the glomerular structure less than in the first group, The dissociation was still present for the lining of the Bowman capsule, As well as cellular necrosis of some tissue (Image 7). While the treatment with a higher concentration of doxycycline (50 mg/kg) and castor powder showed significant improvement in kidney tissue. In the tissue sections of the third group of animals, it was observed that the general structure of kidney tissue was maintained through the clear and distinct regulation of the glomerulus, slight change in lining of Bowman capsule and the integrity of the inner lining of the tubules, as well as the disappearance of many areas of inflammation and death in the cell lines to be closer to the normal model of animals control group, although there are some changes (Image 8). The researcher⁴² reported

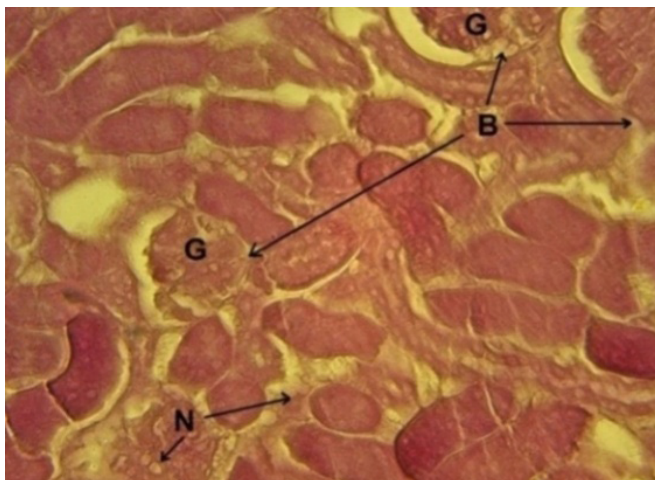


Image 7: Cross-section of Kidney (Cortex) in G2, A little conglomerate (G), Decomposition less of Bowman capsule (B), Necrosis (N), (H&E40X).

that the treatment with doxycycline has positive effects in the structure of kidneys that exposure to poisoning after a period of treatment, Which improves tissue composition by maintaining the work of ribosomes, RNA strands and gene expression confirmed by real-time (PCR), and⁵⁰ has indicated that the treatment with doxycycline may help to prevent or remove some oxidative cases in the body such as oxidation of renal cells.

Lung

In the histology of lung to the animals not treated with castor bean powder, the air exchange zone consists of terminal bronchioles and some respiratory bronchioles containing Alveoli which spreading among the blood vessels. These bronchioles lead to the alveolar ducts, that leading to the alveolar sacs (Figure 9). While in the histological sections of animal lung treated with castor bean in the first group observed damage and destruction in the histological structure, blood cells appeared between the alveolar spaces and the proliferation of inflammatory cells that made the walls of the

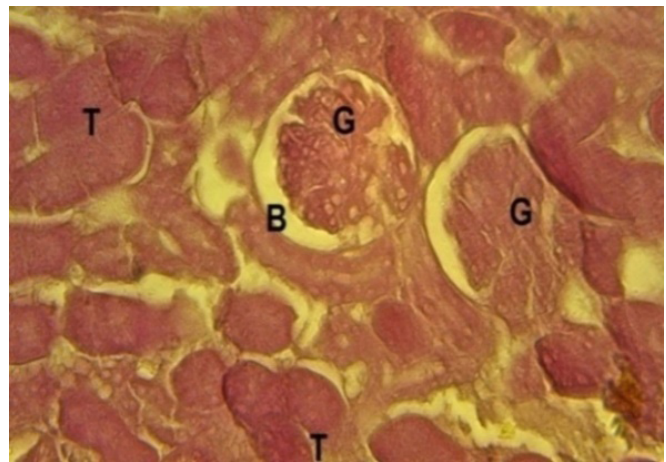


Image 8: Cross-section of Kidney (Cortex) in G3, Normal Glomerulus (G), Normal Bowman capsule (B) Tubules without necrosis or damage (T), (H&E40X).

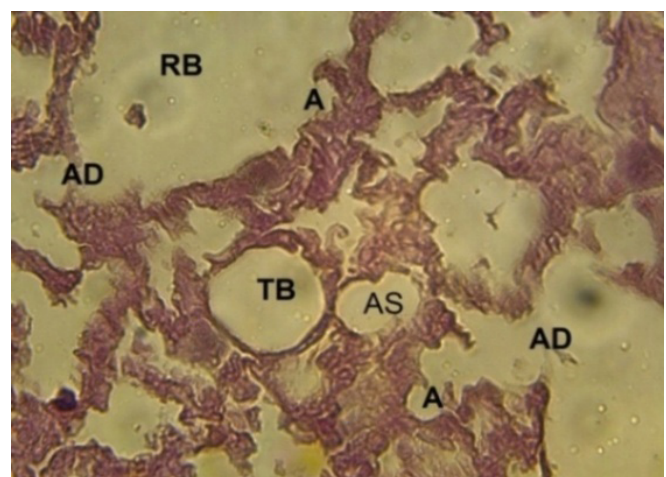


Image 9: Cross-section of the Lung in the control group, Terminal bronchioles (TB) (Res. bronchioles (RB), Alveoli (A) Alveolar ducts (AD), (AS) Alveolar sacs.

anomalies unclear, and show necrosis in the epithelium tissue that lining bronchioles and some respiratory vesicle, as well as crash in the histological structure of the lung (Image 10). Some sources reported that castor bean poisoning leads to pathological effects, and indicated that the effectiveness of ricin toxin causes high inflammation and change in broncho alveolar lavage fluid (BALF) with crash in Alveolar-capillary barrier,⁵¹ there is also a dramatic increase in Neutrophils and macrophage in the lung, which may be the cause of these changes. Other sources have reported pulmonary poisoning due to pulmonary risisosis, Necrotizing pneumonia, bloating of the lymph nodes and the appearance of inflammation, which causes disruption of the tissue structure of the lung and collection of its fluid,^{5,40,43} as well as the toxic plant effect that act on High retention of neutrophils and monocytes in the lung tissue, causing damage to their composition,⁷ with the occurrence of generalized interstitial edema, pulmonary vascular leak, the peripheral respiratory distress syndrome and pulmonary tree extension.^{2,14}

As for the treatment with doxycycline (25 mg/kg) in the second group had a simple effect did not significantly alter the

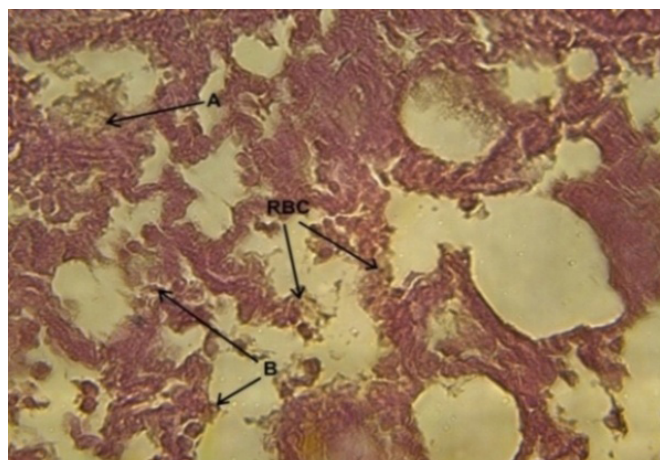


Image 10: Cross-section of the Lung in G1, RBC in alveolar spaces (RBC), Pus cells (A), Necrosis in bronchioles endothelium(B), (H&E40X).

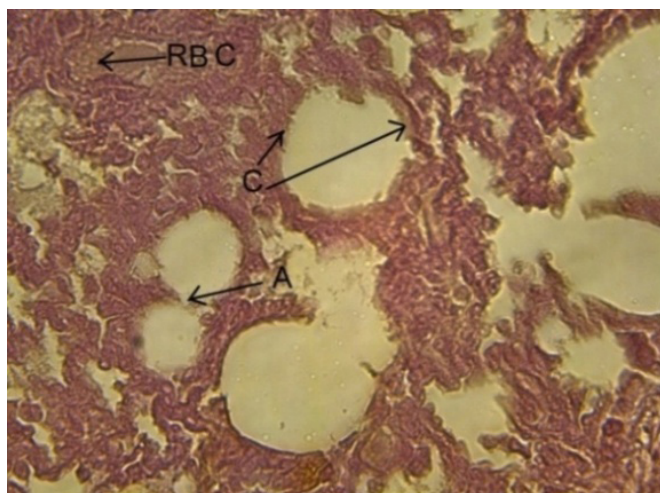


Image 11: Cross-section of the Lung in G2, Crash of Alveoli barriers (A), Inflammation (C), Red blood cell resorption (RBC), (H&E40X).

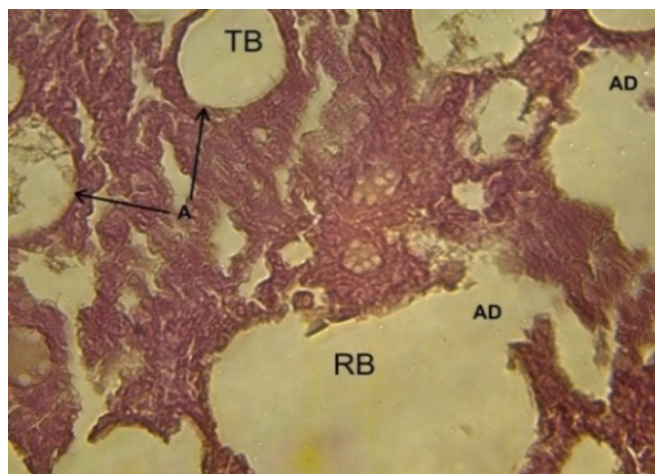


Image 12 : Cross-section of Lung in the G3, Save of alveoli structure(A), an extension of alveolar ducts (AD),Lining intact of bronchioles(TB,RB)(H&E40X).

damage caused by castor beans in the lung structure, where a breakdown of Vesicles barriers was found, whose walls were Expanded and filled with inflammatory cells, was also found resurfacing of red blood cell in the bronchioles (Image 11). In the transverse pulmonary section of the third group, the increased concentration of doxycycline showed significant improvement in the pulmonary tissue, walls of the vesicles saved of their structure and clear alveolar ducts, as well as the disappearance of some damage to the tissue and maintenance the lining of Respiratory bronchioles and terminal bronchioles without dissolution (Image 12) observe⁷ that the treatment of doxycycline can be used to act as an antitoxin by reducing the toxicity of ricin and preventing acute respiratory distress syndrome, which reduces tissue and physiological changes within hours of use, also the doxycycline works to treat inflammation, tissue damage and regulate proinflammatory cytokines by its role as an anti-inflammatory agent, thus showing its role in a good response to the treatment of changes,^{28,35} this is confirmed⁴⁰ by the use of doxycycline for the prevention of pulmonary pneumonia and prolonged cell life during an experiment on mice.

REFERENCES

1. Akande, T.O. et al. (2016). A review of nutritional and toxicological implications of castor bean (*Ricinus communis* L.) meal in animal feeding systems. NCBI ;100 (2):201-10 .PubMed.
2. Elizabeth, I.et al. (2012). Evaluation of Ricinine, a Ricin Biomarker, from a Non Lethal Castor Bean Ingestion.Londen. Oxford academic. Journal of Analytical Toxicology. 36 (9): 660-662.
3. Zhao, Y.Q. et al. (2016). Rapid Detection of Ricin in Serum Based on Cu-Chelated Magnetic Beads Using Mass Spectrometry. The Institute of Basic Medical Sciences, National Center of Biomedical Analysis, Beijing, China. 27 (4):748-51. PubMed.
4. Stern, D. et al. (2016). Simultaneous differentiation and quantification of ricin and agglutinin by an antibody sandwich surface plasmon resonance sensor. Centre for Biological Threats and Special Pathogens, Robert Koch Institute, Berlin, Germany. 15 (78):11-17. PubMed.

5. Ofer, C. et al. (2014). Characterization and Epitope Mapping of the Polyclonal Antibody Repertoire Elicited by Ricin Holotox in Based Vaccination. *Clinical and Vaccine Immunology J.*, Dep. of Biochemistry and Molecular Genetics, Institute for Biological Research, Israel. 21 (11) 1534-1540.
6. Kerrie, L. and Tumer. (2012). The P1/P2 proteins of the human ribosomal stalk are required for ribosome binding and depurination by ricin in human cells. *Department of Plant Biology and Pathology, School of Environmental and Biological Sciences, Rutgers University, New Jersey, USA.* HHS public access. 279 (20): 3925-3936.
7. David, E. (2001). Metalloproteinase Inhibition Prevents Acute Respiratory Distress Syndrome. *Journal of Surgical Research, Elsevier*. 99 (2) 245-252.
8. Grant, W. and Waterer, H.R. (2009). Bioterrorism for the respiratory physician. *School of Medicine and Pharmacology, Uni. of Western Australia. Respirology Journal*, 14 (1):5-11.
9. Martens, M.M. and Labbad, G.M. (2016). Bioterrorism: Ricin Attack and Pregnancy [4M]. *green journal*.
10. Tal, N. et al. (2017). Extended therapeutic window for postexposure treatment of ricin intoxication conferred by the use of high affinity antibodies. *Dep. of Biochemistry and Molecular Genetics, Israel Institute for Biological Research, NessZiona, Israel*. 127 (1):100-105.
11. Tal, N. et al. (2016). Isolation of AntiRicin Protective Antibodies Exhibiting High Affinity from Immunized Non Human Primates .*MDPI Journal. Dep. of Biochemistry and Molecular Genetics, Israel*. 8 (3):64-69.
12. Selvaprakash, K. and Chen, Y.C. (2017). Detection of ricin by using gold nanoclusters functionalized with chicken egg white proteins as sensing probes. *Dep. of Applied Chemistry, National Chiao Tung Uni., Hsinchu 300, Taiwan*. 15:92:410-416. Pubmed.
13. Thornton, S. L. et al. (2014). Castor bean seed ingestions: A statewide poison control system's experience. *Journal of Clinical Toxicology*, 52 (4): 265-268.
14. Tao, Z. et al. (2015). Strong protection against ricin challenge induced by a novel modified ricin Achain protein in mouse model. *State Key Laboratory of Pathogen and Biosecurity; Beijing Institute of Microbiology and Epidemiology; Beijing, China. Human vaccine and immunotherapeutics Journal*, 11 (7): 1779-1787.
15. Hong, I.H. et al. (2011). Fetal death of dogs after the ingestion of a soil conditioner. *Department of Veterinary Pathology, College of Veterinary Medicine, Kyungpook National University, Daegu 702-701, Republic of Korea. Elsevier*, 63 (1-2):113-7. Pubmed.
16. Wang, C.F. et al. (2015). Early plasma exchange for treating ricin toxicity in children after castor bean ingestion. *Dep. of Pediatrics, Fuzhou General Hospital of Nanjing Military Command, PLA, Fuzhou, Fujian, 350025, China*. 30 (3):141-6. Pubmed.
17. Dacie, J. and Lewis, S.M. (1974). *Practical hematology*. Edinburgh. Churchill . Denmark, 6th. Ed.
18. Talib, V. (1996). *A handbook of medical laboratory technology*. WHO. CBS. Publishers and Distributors., 1st ed., p:6-11.
19. AL-Omary ,M.R. (1986). *Scientific Clinical Chemistry*. Technical institutes. First edition. Technico house to Print , Baghdad, Iraq. 7 (76-88).
20. Sporin, A. et al. (1996). Serum glutamic pyrovic transaminase activity. *Nolrung* 18:572.
21. Dacie, J. and Lewis, S.M. (1974). *Practical hematology*. Edinburgh. Churchill . Denmark, 6th. Ed.
22. Luna, L.G. (1978). *Manual of histological staining methods of the armed force institute of pathology*. 3rd ed. MC grow hill book . London .
23. Dawood, K.M. and Ilias, Z.A. (1990). *The statistical Methods to Agriculture Researches*. AL-Musel University .
24. Kathryn, M.D. et al. (1990). Castor bean intoxication. *Departments of Emergency Medicine and Medicine, Uni. of Southern California ,USA. Annals international J.*, 19 (10):1177-1183.
25. Sehgal, P. et al. (2010). Purification characterization and toxicity profile of ricin isoforms from castor beans. *Food and chemical toxicology. an international journal published for the British Industrial Biological Research Association*. 48 (11):3171-6. [PubMed].
26. Abdulazim, S. et al. (1998). The abortifacient effects of castor bean extract and RicinA chain in rabbits. *Contraception an international reproductive Journal*. 58 (3): 193-197.
27. Tore, G. I. (2001). Endosome to Golgi Transport of Ricin Is Independent of Clathrin and of the Rab9 and Rab11 GTPases. *Institute for Cancer Research, The Montebello and Structural Cell Biology Unit, University of Copenhagen, Denmark*. 12 (7):2099-2107
28. Waldemar, P. et al. (1992). Inhibition of enzymatic activity of phospholipases A by minocycline and doxycycline. *Inflammation Research Group, The Wellesley Hospital, University of Toronto, Toronto, Ontario Canada . Biochemical Pharmacology J.*, 44 (6):1165-1170.
29. Seth, H. P. et al. (2017). Design and In Vivo Characterization of Immunoconjugates Targeting HIV gp160. *aResearch Institute for Children, Children's Hospital, New Orleans, Louisiana, USA. Journal of Virology*. 91 (3):1360-16.
30. Rana, M. et al. (2012). *Ricinus communis L. International Journal of PharmTech Research*, 4 (4):1706-11.
31. Olsnes, S. et al. (2001). Ricin. *Toxicon*. 39 (11):1723-8. [PubMed]
32. Crompton, R. (1980) Georgi Markov death in a pellet. *The Medicolegal journal*, 1980;48 (2):51-62. [PubMed]
33. Fainaru, O. et al. (2008) . Doxycycline induces membrane expression of VE cadherin on endothelial cells and prevents vascular hyper permeability *FASEB J.*, 22 : 3728-3735.
34. Singh, N. et al. (2004). Mechanisms of glucocorticoid mediated anti-inflammatory and immunosuppressive action *Paediatr. Perinat. Drug Ther.*, 6 :107-115.
35. Pratt, T.S. (2007). Oropharyngeal aspiration of ricin as a lung challenge model for evaluation of the therapeutic index of antibodies against ricin Achain for postexposure treatment exp. *Lung Res.*, 33 :459-481.
36. AL-Hamzawy, N. M. S. (2014). The effect of uranyl acetate toxicity in the tissues of the heart, Liver, kidney and blood physiological & biochemical Parameters in male rabbit's. *Medicine C./AL-Muthanna Uni. Journal of alqadisiyah for pure science*. 19 (4):7-27.
37. Salhab, A.S. et al. (1997). On the Contraceptive Effect of Castor Beans. *International Journal of Pharmacognosy*, 35 (1): 63-65.
38. Pierce, M. (2011). Development of a quantitative RT-PCR assay to examine the kinetics of ribosome depurination by ribosome inactivating proteins using *Saccharomyces cerevisiae* as a model. *RNA*. 17:201-210. [PubMed].

39. Boguszewska, A. (2002). Subcellular distribution of the acidic ribosomal P-proteins from *Saccharomyces cerevisiae* in various environmental conditions. *Biol Cell*.94:139–146. [PubMed].
40. Yoav, G. et al. (2014). Antibody/doxycycline combined therapy for pulmonary ricinosis: Attenuation of inflammation improves survival of ricin intoxicated mice. *Dep. of Biochemistry and Molecular Genetics, Israel Institute for Biological Research, Israel. Toxicology Reports.Elesvier*,1: 496-504.
41. Audi, J. (2005). Ricin poisoning: a comprehensive review. *JAMA: the journal of the American Medical Association*. 294 (18):2342–51. [PubMed].
42. Harley, S.M. (1982). Beevers H. Ricin inhibition of in vitro protein synthesis by plant ribosomes. *Proc Natl Acad Sci USA*.79:5935–5938. [PubMed].
43. Mohammad, M. et al. (2016). Ricin Toxicity: Clinical and Molecular Aspects. *Pharmacodynamics and Toxicology dep., Faculty of Pharmacy, Mashhad Uni. of Medical Sciences, Mashhad, Iran. Reportes of biochemistry and molecular biology*. 4 (2): 60–65.
44. Balali, M. and Moshiri, M. (2015). Problems of Clinical Diagnosis and Management of a Deliberate Biological Born Disease. *J. Bioterror Biodef*, 6: 1-13.
45. Poli, M.A. et al. (2008). Medical aspects of biological warfare. *Washington D.C.: Borden institute, office of the surgeon general, AMEDD center & school, US army*, 323–35.
46. Vernon, L. T. (2011). The Induction of Apoptosis by Shiga Toxins and Ricin. *The series Current Topics in Microbiology and Immunology. Springer J.*,357:137-178.
47. Akamatsu, H. (1992). Effect of doxycycline on the generation of reactive oxygen species: a possible mechanism of action of acne therapy with doxycycline *Acta. Derm. Venereol.*,72 : 178-179.
48. Fujita, M. et al. (2007) Doxycycline attenuated lung injury by its biological effect apart from its antimicrobial function ,*Pulm. Pharmacol. Ther.*, 20 :669-675.
49. Sarheed, N.M. (2009). Histological and Physiological Study of Effect of Fluoride toxicity and the role of Calcium Chloride in its treatment in the Local Rabbits Males. *master thesis College of Science .University of Alqadisiyah.Iraq*.
50. Li, X.P. et al. (2009). A two-step binding model proposed for the electrostatic interactions of ricin A chain with ribosomes. *Biochemistry*,48:3853–3863. [PubMed].
51. Tamar, S. (2015). Antibody treatment against pulmonary exposure to abrin confers significantly higher levels of protection than treatment against ricin intoxication. *Dep. of Biochemistry and Molecular Genetics, Israel Institute for Biological Research, ,Israel.Elesvier. Toxicology Letters*, 237(2):72-78.