

## Role of Intratubinal Triamcinolone Acetonide in Allergic Rhinitis

R. Sanwaria<sup>1</sup>, Meenakshi<sup>2</sup>, Aareen Sanwaria<sup>3</sup>

<sup>1</sup>Associate Professor, Mahabodhi Medical College, Gaya, Bihar, India

<sup>2</sup>Director, Sanwaria hospital, Chaksu, Rajasthan, India

<sup>3</sup>B. Tech, IIT Bombay, Mumbai, Maharashtra, India

Received: 25-09-2025 / Revised: 23-10-2025 / Accepted: 26-11-2025

Corresponding Author: Dr. R. Sanwaria

Conflict of interest: Nil

### Abstract:

**Objective:** To evaluate the effect of intratubinal Triamcinolone acetonide in AR.

**Patients:** Eighty patients were included and followed for one year. All of them received three consecutive doses of intratubinal TAA at 7 days interval.

**Main Outcome Measure:** Reduction of rTNSS was the main outcome measure.

**Results:** all the categories of AR have significant reduction of rTNSS. In mild and moderate form, we observed near complete resolution of symptoms. In severe and very severe case 50% to 75% reduction in rTNSS was found.

**Conclusion:** Intratubinal TAA have long term results in AR. When used with correct injection techniques it has least serious complications.

**Keywords:** Triamcinolone Acetonide, TAA, rTNSS, Intratubinal, Allergic Rhinitis.

This is an Open Access article that uses a funding model which does not charge readers or their institutions for access and distributed under the terms of the Creative Commons Attribution License (<http://creativecommons.org/licenses/by/4.0>) and the Budapest Open Access Initiative (<http://www.budapestopenaccessinitiative.org/read>), which permit unrestricted use, distribution, and reproduction in any medium, provided original work is properly credited.

### Introduction

AR is an IgE mediated immunological response of nasal mucosae. It affects 40% of general population worldwide without age and sex predilection.

It has strong genetic predisposition; a child has a chance of developing AR 20% or 47% respectively if one or both parents have allergic diathesis. It

affects quality of life, absenteeism from job, sleep disturbances. Intratubinal TAA have higher response in any type of AR with negligible complications.

AR is a multifactorial disease that can be classified according to following flow chart: -

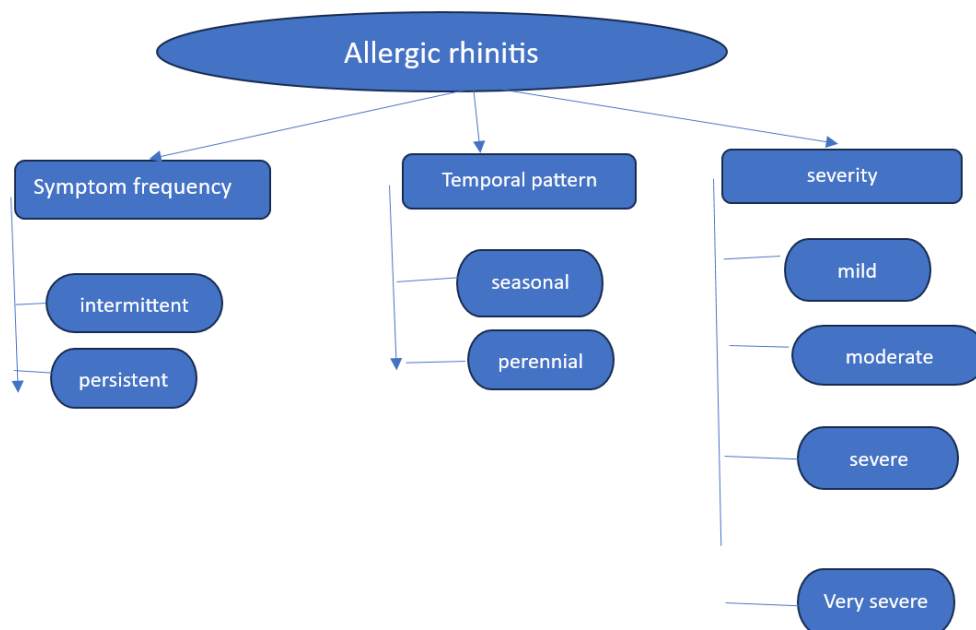


Chart 1: Allergic rhinitis

- Intermittent: sym on < 4 d/wk or < 4 c.wk/yr
- Persistent: sym on > 4 d/wk or > 4 c.wk/yr
- Mild: sym + but not annoying or troublesome
- Moderate: sym frq. Troublesome but not interfering with routine or sleep
- Severe: sym sufficiently troublesome to interfere with routine or sleep
- Very severe: symp severe enough to warrant immediate visit to physician.

On the basis of four cardinal characteristics sneezing, nasal itching, rhinorrhea, nasal congestion/obstruction reflective total nasal symptom score (rTNSS) is calculated. Each symptom included in the rTNSS is scored according to a 5-point scale from 0 to 4. Total rTNSS is the sum of score for each individual symptom and thus range from 0 to maximum 16. Assessment table for classification of AR:

Table 1: rTNSS score

rTNSS score	0	1-4	5-8	9-12	13-16
Class	Absent	Mild	Moderate	Severe	V. Severe

Intranasal corticosteroids are recognized as the most effective treatment modality for relieving AR symptoms.

First reported in 1952 by Wall and Shure, intranasal steroid injections were once a routine office procedure for the treatment of allergic sinonasal diseases.

In 1962 Hager and Heise reported on the first instance of permanent visual loss following an intratubinate hydrocortisone injection. To this day, intranasal steroid injections are not offered by most of otolaryngologists because of this exceedingly rare yet devastating complication. In this article, we begin with our modest personal experience with intranasal steroid injection and review both our technique and outcomes.

#### Material and Method

Between October 2020 to October 2025, 80 intratubinal triamcinolone acetonide injections were performed to the allergic rhinitis patients. The average

age of patients was 63.5 (range 15-73). Male: female ratio was 11:9 (male 44 and female 36). TAA is a synthetic fluorinated corticosteroid that is used for the treatment of AR

#### Exclusion Criteria:

- Patients with coexisting nasal pathology like DNS, polyp, malignancy.
- Patients age less than 15 years and above 75years
- Patients with medical illness like cardiovascular disease
- Patients with any bleeding diathesis
- Patients not willing for follow up

#### Inclusion Criteria:

- Patient of nasal allergic rhinitis having classical symptoms (sneezing, nasal itching, rhinorrhea, nasal congestion)
- Patient age between 15 years and 75 years
- Patients have inferior turbinate hypertrophy
- Patients willing for follow up

Table 2: showing severity and rTNSS score

Severity	No. of cases	rTNSS score
Mild	12	4
Moderate	35	8
Severe	25	11
V. severe	8	15

**Technique:** Patient lying supine, cotton soaked in a mixture xylometazoline, and 4% xylocaine was applied over the anterior aspect of inferior turbinate for 3-5 minute. One cc of 40mg/ml triamcinolone acetonide drawn in an insulin syringe, shaken vigorously and then 0.5cc injected gently without

much pressure in the anterior aspect of inferior turbinate bilaterally for three consecutive weeks.

Cotton pledget then applied for 5 minute to achieve hemostasis. With correct injection technique devastating complication of visual loss can be avoided.

**Table 3: Key points of correct injection technique**

Key points	Rationale
Done on an awake, alert, patient	When awake patient can report visual changes and procedure can be stopped.
Apply a topical vasoconstrictor like xylometazoline	Vasoconstrictor reduces bleeding and decreases of intravascular injection.
The steroid used should be agitated vigorously, should not be allowed to sit for an extended period of time, and should not be mixed with other agents	Steroid that are mixed with other agents or those that are allowed to sit for longer duration have been shown to have increased particle formation and harbor a theoretic increased risk of complications.
A 25-gauge needle or smaller should be used to make a gentle, submucosal injection	This decreases the chances of entering and injecting into a vessel. Deep and forceful injection are not advised.
Safe anatomic targets include the head of the inferior turbinate	This target is most studied and is easily performed in direct visualization.

**Observation and Results**

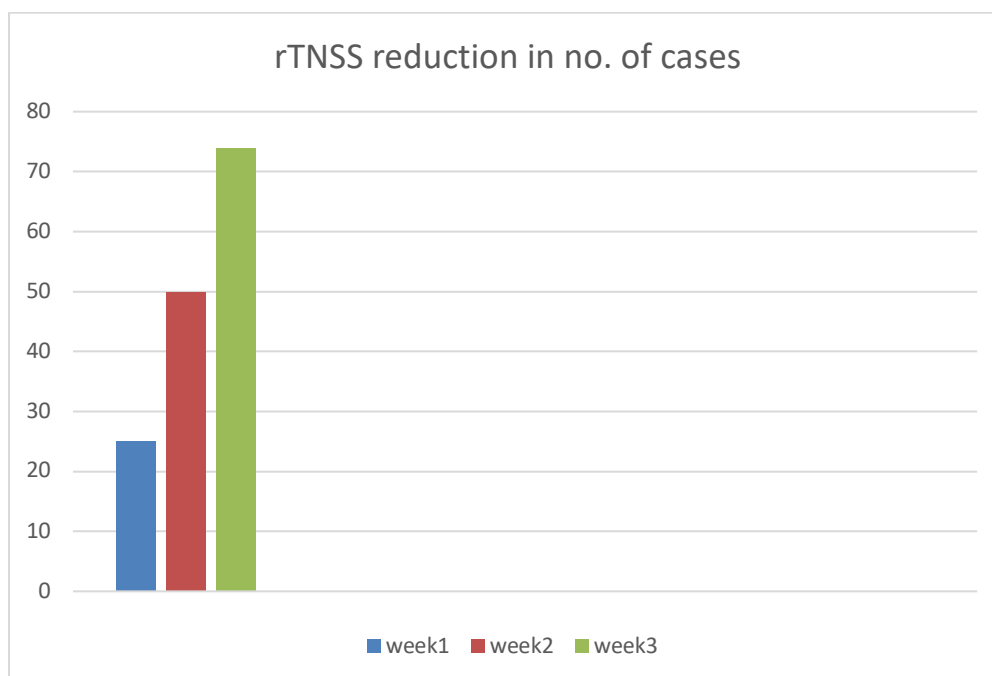
In our study 80 patients were included.

All the patients have significant improvement in rTNSS score. We observed marked reduction in rTNSS from 31.2% in first week to 92.5% in third

week of treatment. Individual symptom score for sneezing, nasal itching, rhinorrhea and nasal congestion progressively declined over time. TAA showed continuous and consistent improvement in total rTNSS score and for individual symptoms through the 3 weeks treatment period.

**Table 4: Showing reduction in rTNSS and individual symptom score**

Symptom	Week 1	Week 2	Week 3
rTNSS	25/80, 31.2%	50/80, 62.5%	74/80, 92.5%
Sneezing	56/80, 70%	60/80, 75%	76/80, 95%
Itching	42/80, 52.5%	65/80, 81.2%	78/80, 97.5%
Rhinorrhea	40/80, 50%	70/80, 87.5%	77/80, 96.2%
Obstruction	30/80, 37.5%	60/80, 75%	68/80, 85%



**Figure 1: rTNSS reduction in no. of cases**

**Discussion**

We have not observed any kind of visual complication in our study, only one case developed bronchospasm, and it was relieved by simple measure of nebulization with budesonide. According to

some published series the risk of visual complication from intratubinal injection is 0.003% which is exceedingly low. The theory behind visual losses associated with intratubinal steroid injection is embolism of steroid particles into the retinal and

choroidal arteries resulting in occlusion, vasospasm, and ischemic injury. This is thought to come about via retrograde flow through the ethmoidal arteries.

Potential complication of endoscopic sinus surgeries are far more diverse and include CSF leak, pneumocephalus, permanent diplopia, and blindness. The overall rate of these highly morbid complications has been estimated at roughly 1% for experienced surgeons, with more minor complications occurring at much higher rate. If endoscopic sinus surgeries have been deemed to carry acceptable risk, it would only seem appropriate that intranasal steroid, with far lesser rate of serious complications, would be accepted as well. In many instances, intranasal steroid injections are done with the intent of avoiding sinus surgery and the higher relative risk therein.

### Conclusion

Correctly performed intratubinal injection carry a risk of visual complication of roughly 0.003%. we have not observed any kind of visual complication.

Intratubinal TAA demonstrated to be an effective treatment for adults with allergic rhinitis that continuously and consistently improved nasal symptom as well as quality of life measure and as well as tolerated over the 3 weeks of treatment.

### References

1. Hager G., Heise G. A severe complication with permanent practical blindness of one eye following intranasal injection. HNO. 1962; 10: 328.
2. Mabry RL Intranasal corticosteroid injection: indications, technique, complications. Otolaryngol head neck surg. 1979; 87:207-211.
3. Simmons MW. Intranasal injection of corticosteroid. Calif Med. 196; 155-158.
4. Myers D. Experiences in the treatment of allergic nasal polyp by intranasal polyp injection of prednisolone. Laryngoscope. 1958; 58:1-17.
5. Johns KJ, Chandra SR, visual loss following intranasal corticosteroid injection. JAMA. 1989; 261:2413.