

**Risk Factors of Acute Cholecystitis After Endoscopic Common Bile Duct Stone Removal**Subhasis Saha<sup>1</sup>, Suvro Ganguly<sup>2</sup>, Partha Bhar<sup>3</sup><sup>1</sup>Department of Surgery, Santiniketan Medical College, Santiniketan, District Birbhum, West Bengal, India<sup>2</sup>Department of Surgery, Santiniketan Medical College, Santiniketan, District Birbhum, West Bengal, India<sup>3</sup>Department of Surgery, Prafulla Chandra Sen Government Medical College, Arambagh, District Hooghly, West Bengal, India

Received: 11-02-2026 / Revised: 15-03-2026 / Accepted: 10 -04-2026

Corresponding Author: Dr. Suvro Ganguly

Conflict of interest: Nil

**Abstract****Introduction:** Acute cholecystitis following endoscopic common bile duct (CBD) stone removal is a recognized but underreported complication. Identifying the risk factors associated with post-procedural cholecystitis is important for early diagnosis, prevention, and appropriate management.**Aim:** To evaluate the risk factors of acute cholecystitis after endoscopic common bile duct (CBD) stone removal.**Materials and Methods:** This study included patients who underwent endoscopic removal of CBD stones. Demographic data, clinical history, gallbladder status, stone characteristics, procedural details, and post-procedural outcomes were analyzed. Patients were followed for the development of acute cholecystitis. Risk factors such as gallbladder stones, cystic duct obstruction, multiple or large stones, gallbladder wall thickening, and history of biliary symptoms were assessed. Statistical analysis was performed to identify significant predictors.**Results:** Acute cholecystitis developed in a subset of patients following CBD stone removal. The presence of gallbladder stones, especially multiple or large stones, was a significant risk factor. Patients with cystic duct obstruction or impaired gallbladder emptying showed a higher incidence of cholecystitis. A prior history of biliary colic or cholangitis was also associated with increased risk. Procedural factors such as incomplete clearance of biliary sludge and post-endoscopic papillary edema may have contributed to gallbladder stasis and subsequent inflammation. Post-ERCP complications show variable timing, with pancreatitis occurring early ( $2.5 \pm 1.2$  days) and cholangitis ( $8.0 \pm 3.9$  days) and acute cholecystitis ( $12.0 \pm 5.8$  days) presenting later, underscoring the need for both immediate and delayed surveillance.**Conclusion:** Acute cholecystitis after endoscopic CBD stone removal is associated with identifiable risk factors, including gallbladder stones, impaired cystic duct patency, and pre-existing biliary disease. Careful patient selection, close post-procedural monitoring, and consideration of prophylactic cholecystectomy in high-risk patients may help reduce the incidence of this complication.**Keywords:** Acute Cholecystitis, Endoscopic Retrograde Cholangiopancreatography, CBD Stones, Risk Factors, Gallbladder Stones, post-ERCP Complications.**DOI:** 10.25258/ijpqa.17.4.23

This is an Open Access article that uses a funding model which does not charge readers or their institutions for access and distributed under the terms of the Creative Commons Attribution License (<http://creativecommons.org/licenses/by/4.0>) and the Budapest Open Access Initiative (<http://www.budapestopenaccessinitiative.org/read>), which permit unrestricted use, distribution, and reproduction in any medium, provided original work is properly credited.

**Introduction**

Acute cholecystitis is a common inflammatory condition of the gallbladder, most frequently caused by obstruction of the cystic duct, usually due to gallstones. It represents one of the leading causes of acute abdomen requiring hospitalization and surgical intervention worldwide [1]. The pathophysiology involves gallbladder distension, bile stasis, secondary infection, and inflammatory cascade activation, which may progress to

complications if not managed promptly [2]. Endoscopic retrograde cholangiopancreatography (ERCP) has become the standard therapeutic modality for the management of common bile duct (CBD) stones, offering a minimally invasive alternative to surgery. With advancements in endoscopic techniques, successful clearance of CBD stones can be achieved in a majority of cases, reducing the need for open or laparoscopic bile

duct exploration [3]. However, despite its effectiveness, ERCP is associated with certain complications, including pancreatitis, bleeding, perforation, and, less commonly, acute cholecystitis [4]. Post-ERCP acute cholecystitis is an important but relatively under recognized complication that can occur after successful or even incomplete clearance of CBD stones [5]. The incidence of post-ERCP cholecystitis varies across studies but remains clinically significant due to its potential to cause morbidity and prolong hospital stay. The mechanism underlying this complication is multifactorial, including cystic duct obstruction by residual stones or sludge, edema following endoscopic manipulation, and bacterial contamination of bile leading to secondary infection.

The presence of gallbladder stones is a major predisposing factor for the development of acute cholecystitis after CBD stone removal. Retained gallstones within the gallbladder can migrate into the cystic duct or cause intermittent obstruction, leading to biliary stasis and inflammation [6]. Additionally, gallbladder wall thickening, poor contractility, and underlying chronic inflammation further increase susceptibility to post-procedural cholecystitis.

Cystic duct patency plays a crucial role in gallbladder drainage, and its obstruction has been identified as a key risk factor for the development of acute cholecystitis following endoscopic intervention. Edema or spasm of the ampulla of Vater after ERCP may transiently impair bile flow, contributing to gallbladder distension and inflammation. Furthermore, mechanical factors such as instrumentation during sphincterotomy or stone extraction may exacerbate these changes [7].

In addition to anatomical and mechanical factors, microbiological aspects also play an important role.

Biliary contamination during ERCP can introduce pathogens into the biliary tree, leading to infection and inflammation of the gallbladder. Common organisms isolated in such cases include *Escherichia coli* and *Klebsiella* species, which are known to ascend from the duodenum into the biliary system under favorable conditions [8]. Patient-related factors such as advanced age, diabetes mellitus, and prior episodes of biliary disease have also been associated with an increased risk of developing acute cholecystitis after ERCP.

These comorbidities may impair immune response, alter gallbladder motility, and predispose patients to infection and inflammation. Moreover, patients with a history of recurrent biliary colic or cholangitis may already have compromised gallbladder function, making them more vulnerable to post-procedural complications [9]. Despite the widespread use of ERCP, there remains a lack of

consensus regarding the identification of patients at high risk for developing acute cholecystitis following CBD stone removal. Early recognition of risk factors is essential to guide clinical decision-making, including the consideration of prophylactic cholecystectomy in selected patients. Preventive strategies, close monitoring, and timely intervention can significantly reduce morbidity associated with this complication.

Several studies have emphasized the importance of evaluating gallbladder status prior to and following ERCP to predict outcomes and guide management strategies. Imaging modalities such as ultrasonography and magnetic resonance cholangiopancreatography (MRCP) are useful in assessing gallbladder stones, wall thickness, and cystic duct patency, thereby aiding in risk stratification [10]. The aim of this study is to evaluate the risk factors associated with the development of acute cholecystitis following endoscopic removal of common bile duct stones.

The objectives are to determine the incidence of post-procedural acute cholecystitis, assess patient-related factors (such as age, gender, and comorbidities), evaluate gallbladder-related factors (such as presence of gallstones and cystic duct patency), and analyze procedure-related factors influencing its occurrence. The study also aims to identify high-risk patients and improve strategies for early diagnosis and prevention of this complication.

## Materials and Methods

**Study Design:** This study is designed as a prospective observational study

**Place of Study:** Department of Surgery and Gastroenterology, Santiniketan Medical College and Prafulla Chandra Sen Government Medical College, Arambagh.

**Period of Study:** March 2024 to September 2025.

**Study population:** The study population includes all patients diagnosed with CBD stones and treated with endoscopic stone removal during the study period. Patients are selected from those admitted to the hospital and undergoing endoscopic retrograde cholangiopancreatography (ERCP) for therapeutic management.

**Sample size:** The study included 80 patients diagnosed with common bile duct (CBD) stones who underwent endoscopic retrograde cholangiopancreatography (ERCP) for stone removal.

## Inclusion Criteria

- Are diagnosed with common bile duct stones confirmed by imaging or ERCP.

- Undergo successful endoscopic removal of CBD stones.
- Are aged 18 years and above.
- Provide informed consent to participate in the study.
- Are willing to comply with follow-up after the procedure.

#### Exclusion Criteria

- Have a prior history of cholecystectomy.
- Present with acute cholecystitis at the time of admission or before ERCP.
- Have malignancy of the biliary tract or gallbladder.
- Have incomplete or failed ERCP procedure.
- Are lost to follow-up or unwilling to participate in follow-up.
- Have severe comorbid conditions that may interfere with study outcomes or follow-up assessment.

**Statistical Analysis:** For statistical analysis data were entered into a Microsoft excel spreadsheet and then analyzed by SPSS (version 27.0; SPSS Inc., Chicago, IL, USA) and Graph Pad Prism version 5. Data had been summarized as mean and standard deviation for numerical variables and count and percentages for categorical variables. Two-sample t-tests for a difference in mean involved independent samples or unpaired samples.

Paired t-tests were a form of blocking and had greater power than unpaired tests. A chi-squared test ( $\chi^2$  test) was any statistical hypothesis test wherein the sampling distribution of the test statistic is a chi-squared distribution when the null hypothesis is true. Without other qualification, 'chi-squared test' often is used as short for Pearson's chi-squared test. Unpaired proportions were compared by Chi-square test or Fischer's exact test, as appropriate.

Explicit expressions that can be used to carry out various t-tests are given below. In each case, the formula for a test statistic that either exactly follows or closely approximates a t-distribution under the null hypothesis is given. Also, the appropriate degrees of freedom are given in each case. Each of these statistics can be used to carry out either a one-tailed test or a two-tailed test.

Once a t value is determined, a p-value can be found using a table of values from Student's t-distribution. If the calculated p-value is below the threshold chosen for statistical significance (usually the 0.10, the 0.05, or 0.01 level), then the null hypothesis is rejected in favour of the alternative hypothesis. P-value  $\leq$  0.05 was considered for statistically significant.

#### Result

**Table 1: Age Distribution of Patients (n = 80)**

Age Group (years)	Number of Patients	Percentage (%)
18-30	18	22.5
31-40	20	25
41-50	22	27.5
51-60	12	15
>60	8	10
Total	80	100

**Table 2: Gender Distribution of Patients (n = 80)**

Gender	Number of Patients	Percentage (%)
Male	34	42.5
Female	46	57.5
Total	80	100

**Table 3: Clinical Presentation (n = 80)**

Presentation	Number of Patients	Percentage (%)
Right upper quadrant pain with jaundice	40	50
Right upper quadrant pain only	18	22.5
Nonspecific gastrointestinal symptoms	12	15
Abdominal lump	10	12.5
Total	80	100

**Table 4: Gallbladder Findings (n = 80)**

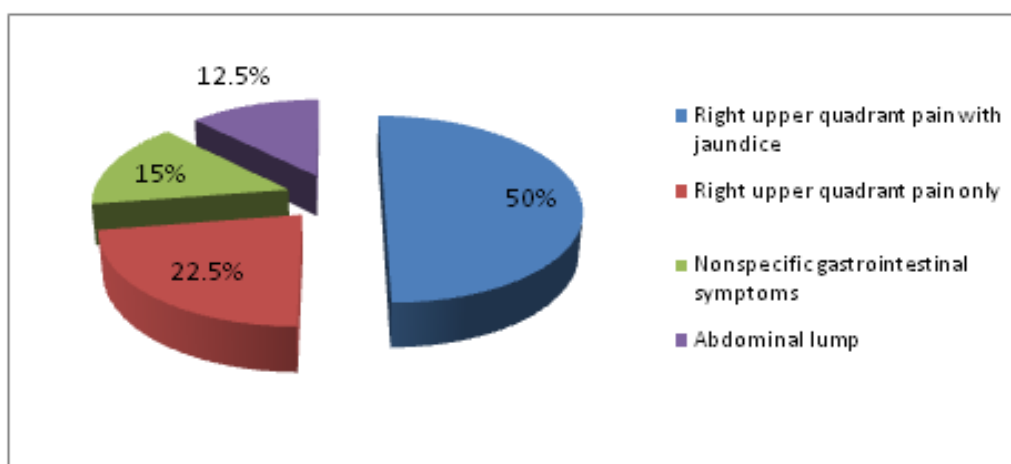
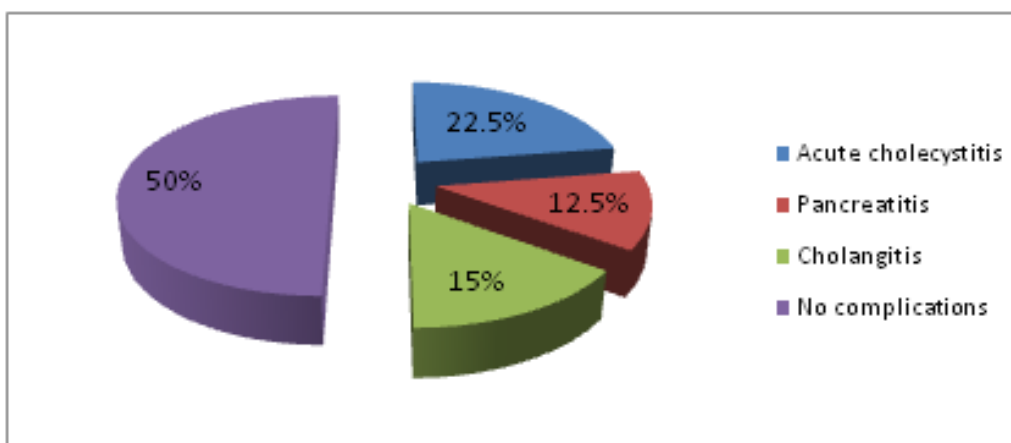
Finding	Number of Patients	Percentage (%)
Cholelithiasis	42	52.5
No gallstones	38	47.5
Total	80	100

**Table 5: Post-Endoscopic Complications (n = 80)**

Complication	Number of Patients	Percentage (%)
Acute cholecystitis	18	22.5
Pancreatitis	10	12.5
Cholangitis	12	15
No complications	40	50
Total	80	100

**Table 6: Time interval from ERCP to complications**

Complication	N	Mean $\pm$ SD (days)	Median	Minimum	Maximum
Acute cholecystitis	18	12.0 $\pm$ 5.8	10	3	27
Pancreatitis	10	2.5 $\pm$ 1.2	2	1	5
Cholangitis	12	8.0 $\pm$ 3.9	7	2	18

**Figure 1: Clinical Presentation (n = 80)****Figure 2: Post-Endoscopic Complications (n = 80)**

**Age Distribution (n = 80):** Out of 80 patients, 18 patients (22.5%) were in the age group of 18–30 years, 20 patients (25.0%) were in 31–40 years, 22 patients (27.5%) were in 41–50 years, 12 patients (15.0%) were in 51–60 years, and 8 patients (10.0%) were above 60 years.

**Gender Distribution (n = 80):** Out of 80 patients, 46 patients (57.5%) were females and 34 patients (42.5%) were males.

**Clinical Presentation (n = 80):** Out of 80 patients, 40 patients (50.0%) presented with right upper quadrant pain with jaundice, 18 patients (22.5%) had isolated right upper quadrant pain, 12 patients (15.0%) had nonspecific gastrointestinal symptoms, and 10 patients (12.5%) presented with an abdominal lump.

**Gallbladder Findings (n = 80):** Out of 80 patients, 42 patients (52.5%) had cholelithiasis, while 38 patients (47.5%) did not have gallstones.

**Post-Endoscopic Development of Acute Cholecystitis (n = 80):** Out of 80 patients, 18 patients (22.5%) developed acute cholecystitis following endoscopic common bile duct stone removal, while 62 patients (77.5%) did not develop this complication

**Time interval from ERCP to complications:** The time interval between endoscopic retrograde cholangiopancreatography (ERCP) and the development of post-procedural complications showed variability across different clinical outcomes. Acute cholecystitis was observed in 18 patients with a mean onset time of  $12.0 \pm 5.8$  days after ERCP, with a median of 10 days and a range of 3 to 27 days. Pancreatitis developed in 10 patients, occurring early after the procedure with a mean time of  $2.5 \pm 1.2$  days, median of 2 days, and a range of 1 to 5 days. Cholangitis was identified in 12 patients, with a mean onset time of  $8.0 \pm 3.9$  days, median of 7 days, and a range of 2 to 18 days. These findings indicate that post-ERCP pancreatitis tends to occur early, whereas acute cholecystitis and cholangitis present in a relatively delayed fashion following the procedure.

### Discussion

In the present study, we observed that the majority of patients belonged to the middle age group with a slight female predominance. This pattern is consistent with the epidemiological observations described by Everhart and Ruhl [11] and Shaffer [12], who reported that gallstone disease is more common in females due to hormonal influences such as estrogen, which promotes cholesterol supersaturation and gallstone formation.

We found that the most common clinical presentation was right upper quadrant pain with jaundice, followed by isolated pain and nonspecific gastrointestinal symptoms. This is in agreement with Stinton and Shaffer [13], who described biliary colic and jaundice as the classical presentation of gallstone-related disease. Similarly, Longo et al. [14] in *Harrison's Principles of Internal Medicine* highlighted that obstruction of bile flow leads to pain, jaundice, and, if persistent, inflammatory complications.

In our study, more than half of the patients had cholelithiasis, indicating that gallbladder stones are a major predisposing factor. This finding is supported by Portincasa et al. [15], who explained that gallstone formation results from bile supersaturation, nucleation, and impaired gallbladder motility. Likewise, Shaffer [16] emphasized that gallstones are a major cause of biliary complications due to their role in causing obstruction and inflammation.

We observed that a significant proportion of patients developed acute cholecystitis following

endoscopic common bile duct stone removal. This complication has been described by Freeman [17], who reported that ERCP, although highly effective, may lead to biliary complications due to procedural manipulation. Similarly, Testoni et al. [18] highlighted that ERCP-related adverse events include infection, inflammation, and obstruction due to edema or sludge formation.

We found that patients with gallstones had a higher risk of developing post-procedural cholecystitis. This observation is consistent with the findings of Bakker et al. [19], who reported that gallstones are a major risk factor for recurrent biliary events and complications. Additionally, Lee et al. [20] demonstrated that gallbladder dysfunction and impaired motility further increase the risk of inflammation in patients with cholelithiasis.

In some patients without gallstones, acute cholecystitis still developed, suggesting that other mechanisms are involved. This is supported by Andriulli et al. [21], who described that bacterial contamination during endoscopic procedures can lead to biliary infection. Furthermore, Leung et al. [22] demonstrated that organisms such as *Escherichia coli* and *Klebsiella* species commonly colonize bile and contribute to inflammation and infection.

We also observed that the majority of patients did not develop complications, indicating that endoscopic management is generally safe and effective. However, the occurrence of acute cholecystitis in a subset of patients highlights the need for vigilance. Chandrasekhara et al. [23] reported that although ERCP is widely used, it carries a risk of complications that can affect patient outcomes.

Preventive strategies, including early identification of high-risk patients and consideration of cholecystectomy in selected cases, are supported by Elmunzer et al. [24], who emphasized that appropriate patient selection and preventive measures can reduce post-ERCP complications.

Post-ERCP complications demonstrate distinct timing patterns. Pancreatitis occurs early (mean  $2.5 \pm 1.2$  days), consistent with findings by Freeman ML [17] and Andriulli A et al. [21], likely due to procedure-induced pancreatic injury. Acute cholecystitis presents later (mean  $12.0 \pm 5.8$  days), as described by Strasberg SM [1] and Kim GH et al. [9], related to cystic duct obstruction. Cholangitis shows intermediate onset (mean  $8.0 \pm 3.9$  days), supported by Leung JW et al. [8], and associated with biliary infection and inadequate drainage.

### Conclusion

The present study demonstrates that acute cholecystitis following endoscopic removal of

common bile duct stones is an important post-procedural complication, occurring in a notable proportion of patients. The development of this condition appears to be associated with identifiable risk factors, particularly the presence of gallbladder stones and pre-existing biliary symptoms. Female patients and those with underlying gallbladder pathology showed a higher tendency toward developing complications. Endoscopic removal of CBD stones remains an effective and minimally invasive therapeutic modality; however, it does not eliminate the risk of subsequent gallbladder-related complications. Patients with residual gallbladder stones or impaired gallbladder function are at increased risk and require careful monitoring after the procedure. Early recognition of high-risk patients, along with close clinical follow-up, is essential for timely diagnosis and management of acute cholecystitis. Preventive strategies, including consideration of cholecystectomy in selected high-risk patients, may help reduce morbidity. Additionally, post-ERCP complications exhibit variable timing: pancreatitis tends to occur early (mean  $2.5 \pm 1.2$  days), whereas cholangitis ( $8.0 \pm 3.9$  days) and acute cholecystitis ( $12.0 \pm 5.8$  days) typically present later. This highlights the need for both immediate and delayed surveillance following the procedure. In conclusion, a thorough understanding of risk factors and vigilant post-procedural surveillance are crucial in improving patient outcomes and minimizing complications following endoscopic common bile duct stone removal.

#### Reference

1. Strasberg SM. Acute calculous cholecystitis. *New England Journal of Medicine*. 2008 Jun 26;358(26):2804-11.
2. Ansaloni L, Pisano M, Coccolini F, Peitzmann AB, Fingerhut A, Catena F, Agresta F, Allegri A, Bailey I, Balogh ZJ, Bendinelli C. 2016 WSES guidelines on acute calculous cholecystitis. *World journal of emergency surgery*. 2016 Jun 14;11(1):25.
3. Freeman ML. Post-ERCP pancreatitis: patient and technique-related risk factors. *Jop*. 2002 Nov 1;3(6):169-76.
4. Cotton PB. Twenty more ERCP lawsuits: why? Poor indications and communications. *Gastrointest Endosc*. 2010 Oct 1;72(4):904.
5. Andriulli A, Loperfido S, Napolitano G, Niro G, Valvano MR, Spirito F, Pilotto A, Forlano R. Incidence rates of post-ERCP complications: a systematic survey of prospective studies. *Official journal of the American College of Gastroenterology| ACG*. 2007 Aug 1;102(8):1781-8.
6. Wachtel TL. From Former ABA President Thomas L. Wachtel, MD, MMM. *The Journal of Burn Care & Rehabilitation*. 1999 Mar 1;20(2):123-4.
7. Lee SP, et al. Gallbladder dysfunction. *Gut Liver*. 2010.
7. Testoni PA, Mariani A, Aabakken L, Arvanitakis M, Bories E, Costamagna G, Devière J, Dinis-Ribeiro M, Dumonceau JM, Giovannini M, Gyokeres T. Papillary cannulation and sphincterotomy techniques at ERCP: European Society of Gastrointestinal Endoscopy (ESGE) clinical guideline. *Endoscopy*. 2016 Jul;48(07):657-83.
8. Leung JW, Liu YL, Lau GC, Chan RC, Lai AC, Ling TK, Cheng AF. Bacteriologic analyses of bile and brown pigment stones in patients with acute cholangitis. *Gastrointestinal endoscopy*. 2001 Sep 1;54(3):340-5.
9. Kim GH, Ryoo SK, Park JK, Park JK, Lee KH, Lee KT, Lee JK. Risk factors for pancreatitis and cholecystitis after endoscopic biliary stenting in patients with malignant extrahepatic bile duct obstruction. *Clinical endoscopy*. 2019 May 28;52(6):598-605.
10. Huh J, Ham SJ, Cho YC, Park B, Kim B, Woo CW, Choi Y, Woo DC, Kim KW. Gadaxetate-enhanced dynamic contrast-enhanced MRI for evaluation of liver function and liver fibrosis in preclinical trials. *BMC medical imaging*. 2019 Nov 15;19(1):89.
11. Everhart JE, Ruhl CE. Burden of digestive diseases in the United States part I: overall and upper gastrointestinal diseases. *Gastroenterology*. 2009 Feb 1;136(2):376-86.
12. Shaffer EA. Epidemiology of gallbladder stone disease. *Best Pract Res Clin Gastroenterol*. 2006.
13. Stinton LM, Shaffer EA. Epidemiology of gallbladder disease: cholelithiasis and cancer. *Gut and liver*. 2012 Apr 17;6(2):172.
14. Longo DL, Fauci AS, Kasper DL, et al. *Harrison's Principles of Internal Medicine*. 20th ed. 2018.
15. Portincasa P, Moschetta A, Palasciano G. Cholesterol gallstone disease. *The Lancet*. 2006 Jul 15;368(9531):230-9.
16. Shaffer EA. Epidemiology of gallbladder stone disease. *Best Pract Res Clin Gastroenterol*. 2006
17. Freeman ML. Complications of endoscopic retrograde cholangiopancreatography. *Gastrointest Endosc*. 2002.
18. Testoni PA, Mariani A, Aabakken L, et al. ERCP-related adverse events. *Endoscopy*. 2016.
19. de Bakker JK, Suurmeijer JA, Toennaer JG, Bonsing BA, Busch OR, van Eijck CH, de Hingh IH, de Meijer VE, Molenaar IQ, van Santvoort HC, Stommel MW. Surgical outcome after pancreatoduodenectomy for duodenal adenocarcinoma compared with other periampullary cancers: a nationwide

- audit study. *Annals of surgical oncology*. 2023 Apr;30(4):2448-55.
20. Lee SP, et al. Gallbladder motility and dysfunction. *Gut Liver*. 2010.
  21. Andriulli A, Loperfido S, Napolitano G, Niro G, Valvano MR, Spirito F, Pilotto A, Forlano R. Incidence rates of post-ERCP complications: a systematic survey of prospective studies. *Official journal of the American College of Gastroenterology| ACG*. 2007 Aug 1;102(8):1781-8.
  22. Leung JW, Liu YL, Lau GC, Chan RC, Lai AC, Ling TK, Cheng AF. Bacteriologic analyses of bile and brown pigment stones in patients with acute cholangitis. *Gastrointestinal endoscopy*. 2001 Sep 1;54(3):340-5.
  23. Chandrasekhara V, et al. Adverse events associated with ERCP. *Gastrointest Endosc*. 2017.
  24. Elmunzer BJ. Prevention of ERCP-induced pancreatitis. *Pancreapedia: The Exocrine Pancreas Knowledge Base*. 2015 Jun 13;10.