

Research Article

## Acute Oral Toxicity of Lansioside D in Mice

Paula Angela N. Marfori<sup>1</sup>, Ma. Dalisay G. Maligalig<sup>1</sup>, Ma. Amelita C. Estacio<sup>2</sup>, Rohani B. Cena<sup>3</sup>, Mark Joseph M. Desamero<sup>2</sup>, Mary Jasmine C. Ang<sup>2</sup>, Eufrocino C. Marfori<sup>4\*</sup>

<sup>1</sup>*Institute of Biological Sciences, College of Arts and Sciences, University of the Philippines Los Baños, College, Laguna 4031 Philippines.*

<sup>2</sup>*Department of Basic Veterinary Sciences, College of Veterinary Medicine, University of the Philippines Los Baños, College, Laguna 4031 Philippines.*

<sup>3</sup>*Institute of Molecular Biology and Biotechnology, National Institutes of Health, University of the Philippines Manila, Pedro Gil St., Ermita, Manila 1000 Philippines.*

<sup>4</sup>*National Institute of Molecular Biology and Biotechnology, University of the Philippines Los Baños, College, Laguna 4031 Philippines.*

Available online: 1<sup>st</sup> May, 2016

---

### ABSTRACT

Lansioside D is a novel antimicrobial compound isolated from the peel of *Lansium domesticum*. This compound has a very remarkable activity against Gram-positive bacteria including Methicillin-resistant *Staphylococcus aureus* (MRSA). For the initial phase towards its development as a potential drug, a study to determine its acute oral toxicity was conducted. Forty male and 40 female ICR mice were equally distributed into three treatment groups and one control group. The treatment groups were administered with Lansioside D at various dose levels: 31.25 mg/kg body weight (low dose), 500 mg/kg body weight (middle dose) and 1000 mg/kg body weight (high dose). The control group was administered only with distilled water. Mortality within a 24-h period, as well as daily monitoring of food intake, water intake and body weight 14 days after the administration of the compound was done. Creatinine, urea nitrogen (BUN) and alanine aminotransferase (ALT) levels were also determined prior to treatment (day 0), on day 7 and on day 14. At the end of the 14-day observation period, animals were sacrificed and dissected. The stomach, kidneys and liver were isolated, their gross morphology and relative organ weights were determined, and thereafter subjected to histological evaluation. Results showed no mortalities after 24 h and no differences in all daily observed physiological parameters. Blood creatinine, BUN and ALT levels were normal prior up until the end of the experimentation. No differences were observed in the gross morphology of the stomach, kidneys and liver, as well as the relative organ weights among all the treatment and control groups. Histological examination of these organs revealed no significant abnormal findings. The above results suggest that Lansioside D is not toxic to mice and therefore has a potential to be developed as a new antibiotic.

**Keywords:** Lansioside D, *Lansium domesticum*, Lansones, Toxicity

---

### INTRODUCTION

Lansioside D (Fig. 1) is a new compound isolated from the fruit peel of *L. domesticum*<sup>1</sup>. It belongs to the family of triterpenoid glycosides, which are triterpenes that contain a glycosylated isoprene unit<sup>2</sup>. Its relative stereochemistry is similar to that of Lansioside C, a compound previously isolated from air dried fruit peel of *L. domesticum*<sup>3</sup> but differs from it by the presence of an additional carboxyl (C-22) and methoxyl (C-23) groups. Antimicrobial assay of Lansioside D showed remarkable activity against *Staphylococcus aureus* with a minimum inhibitory concentration (MIC) of 31.25 µg/mL. The compound exhibited promising activity against eight clinical strains of methicillin-resistant *S. aureus* (MRSA) remarkably comparable to that of Vancomycin<sup>4</sup>. Resistant strains of microorganisms like MRSA are said to be the major causal factors in the rising incidence of community-acquired and nosocomial diseases<sup>5</sup>. They can also cause an increase in treatment failure, resulting to poor patient outcomes and

ultimately increased mortality. Moreover, they increase the need for combination therapy which entails higher treatment costs<sup>6</sup>. Therefore, the development of Lansioside D as a therapeutic agent against MRSA must be pursued. Although the efficacy of Lansioside D has already been established<sup>1</sup>, no studies have yet been performed to assess its toxicity profile. As a new drug candidate, Lansioside D cannot be given to man unless it undergoes toxicity testing to certify whether or not it possesses some unexpected side effects. Thus, before its clinical trials may be initiated, it is essential to present experimental evidences that characterize and estimate the extent of toxicity it produces in relevant animal models<sup>7</sup>. In this regard, this study of the acute oral toxicity of Lansioside D in mice was conducted. This study was conducted from August 2014 to March 2015. The extraction of Lansioside D was done at the National Institute of Molecular Biology and Biotechnology, University of the Philippines Los Baños. Toxicity and

---

\*Author for Correspondence

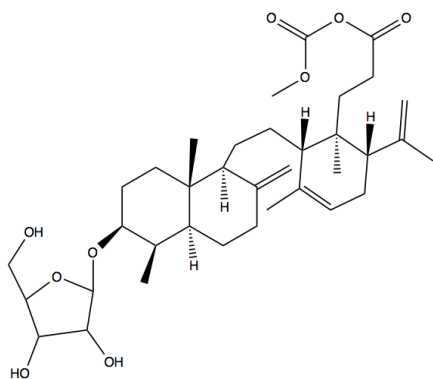


Figure 1: Chemical structure of Lansioside D.

histopathological assays were performed at the College of Veterinary Medicine, University of the Philippines Los Baños and National Institute of Health, University of the Philippines Manila, respectively.

## MATERIALS AND METHODS

### Plant material

*L. domesticum* fruit peels (about 10 kg fresh weight) were obtained from the province of Laguna, Philippines. They were air-dried for one week to yield approximately 150 g of the dried material. A sample plant specimen was sent to the Department of Botany, Institute of Biological Sciences, University of the Philippines Los Baños for authentication.

### Isolation of Lansioside D

Lansioside D was isolated following the procedures done by Marfori<sup>4</sup> et al. The dried fruit peels were chopped, soaked in methanol overnight and filtered. The filtrate was dried *in vacuo* below 40 °C. The residue was re-suspended in 100 mL distilled water and was adjusted to pH 4, then sequentially extracted with n-hexane and ethyl acetate. The ethyl acetate extract was evaporated to dryness and the resulting residue was fractionated by silica open column chromatography eluted with solvents of increasing polarity, in the following sequence: toluene, toluene:acetone (9:1), toluene:acetone (8:2), toluene:acetone (7:3), toluene:acetone (6:4), acetone and methanol. High pressure liquid chromatography (HPLC) of the acetone fraction using Inertsil ODS-3 preparative column eluted with 30-100% CH<sub>3</sub>CN at a flow rate of 1 mL/min was performed to obtain Lansioside D.

### Experimental animals

Healthy, six wk-old, specific pathogen-free (SPF), ICR-strain Swiss Webster mice, with weights ranging from 25-30 g, were obtained from the Research Institute for Tropical Medicine (RITM) in Alabang, Muntinlupa City, Philippines. All mice, forty males and forty females, were housed individually in plastic observation cages and were kept at the Small Animal Laboratory Facility of the College of Veterinary Medicine, UPLB. They were acclimatized for one week prior to the experiment proper. Rodent pellets and distilled water were provided *ad libitum* throughout the acclimatization and observation periods. All procedures conducted in mice were approved by the Institutional Animal Care and Use Committee of the

College of Veterinary Medicine, University of the Philippines Los Baños.

### Administration of treatments

Mice were divided into three treatment groups and one control group, with each group consisting of 10 males and 10 females. The treatment groups were orally gavaged with Lansioside D at various dose levels: 31.25 mg/kg body weight (low dose), 500 mg/kg body weight (middle dose), and 1000 mg/kg body weight (high dose), while only distilled water (vehicle) was gavaged to the control group.

Lansioside D was prepared as a 2% stock solution in distilled water. The volume of the stock solution administered to each mouse was computed using the formula:

$$V = \frac{db}{c}$$

; where V= volume of solution (in mL), d= dosage (in g/kg), b= body weight (in kg) and c= concentration of stock solution (in g/mL). In cases when volume of solution exceeded 1 mL, further administration was done 30 min after the first administration. All mice were starved of food and water three hours before the administration and two hours thereafter.

### Mortality, body weight, feed intake and water intake

For the first 24 h after the administration of the treatments, the mice were observed for mortality after every hour. They were also observed for any physical (*e.g.* wasting, hair loss), behavioral (*e.g.* ataxia, change in posture) and physiological (*e.g.* sweating/shivering, alteration of breathing pattern/heart rate/muscle tone, fecal characteristics) indications of toxic reaction. At the end of the 24 h toxicity assessment, all animals were subjected to daily monitoring of body weight, feed intake and water intake. In cases of mortality, the mice were immediately subjected to necropsy. Any signs of toxic syndromes for a period of two weeks were noted.

### Blood chemistry

Five male and 5 female mice per group were randomly selected for blood collection on the day before the administration of treatments (day 0), on day 7 and on day 14. Blood was obtained from the orbital sinus using a heparinized capillary tube. Collected blood (100 uL) was transferred to properly labeled 1.5 mL microcentrifuge tubes and was used for blood chemistry analyses which included creatinine and BUN for evaluation of kidney function, and ALT for assessment of liver function. Blood chemistry was performed using the Refletron blood chemistry analyzer following the manufacturer's instruction (Roche, USA).

### Histological assay

All surviving mice by the end of the experiment were sacrificed through cervical dislocation and were subjected to necropsies. The stomach, kidneys and liver of the treatment groups were excised and compared to the organs of the control group for any difference in the relative organ weight (*i.e.* the ratio of organ weight to body weight) and gross morphology. Excised organs were placed in cassettes and were immersed in a plastic container containing 10% formaldehyde for fixation. All samples were sent to the Philippine Kidney Dialysis Foundation (PKDF), Quezon

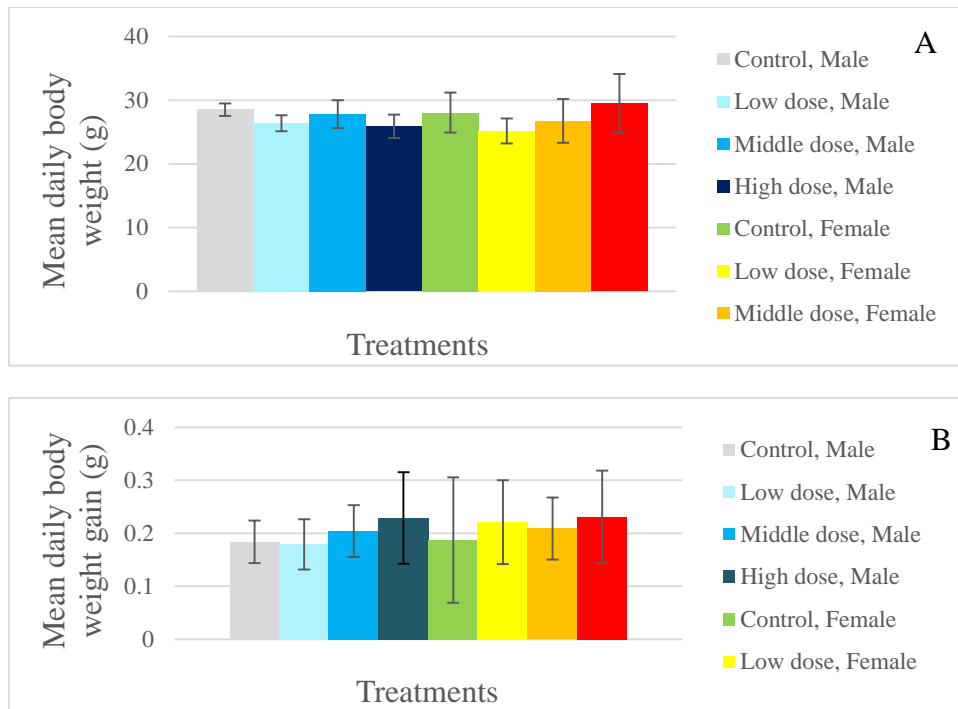


Figure 2: Mean daily body weight (A) and body weight gain (B) of male and female mice treated with distilled water (control) and Lansioside D at three dose levels (low dose= 31.25 mg/kg, middle dose= 500 mg/kg, high dose= 1000 mg/kg); n=10.

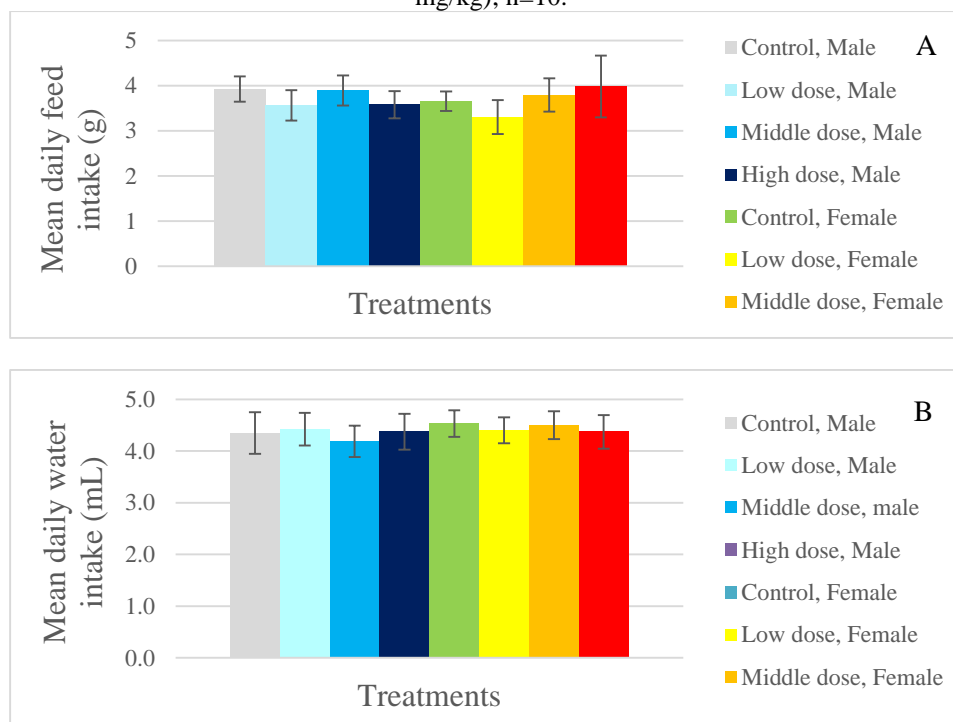


Figure 3: Mean daily feed intake (A) and water intake (B) of male and female mice treated with distilled water (control) and Lansioside D at three dose levels (low dose= 31.25 mg/kg, middle dose= 500 mg/kg, high dose= 1000 mg/kg); n=10.

City, Philippines for tissue processing, sectioning and staining with hematoxylin and eosin. The tissue sections were examined under the light microscope for any abnormalities such as congestion, inflammation, vacuolation and presence of artifacts.

*Statistical analysis*

Statistical analyses were conducted using Minitab version 17. Data were expressed as mean ± SD. The body weight, weight gain, daily feed intake and daily water intake, as well as the relative organ weights were compared using two-way ANOVA, considering the treatment group and the sex of the mice. The blood creatinine, BUN and ALT levels were compared using two-way ANCOVA,

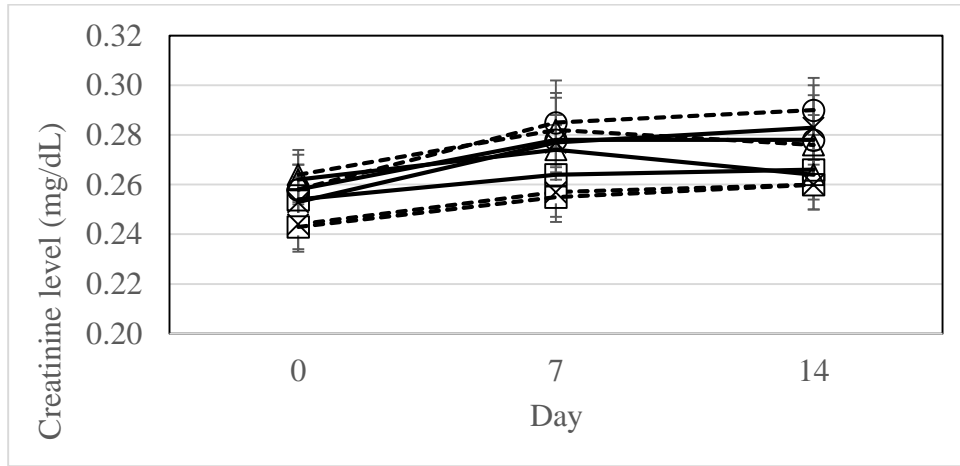


Figure 4: Creatinine levels (mg/dL) of mice treated with distilled water (×), and Lansioside D at low dose (○), middle dose (Δ) and high dose (□) levels. Broken lines represent those of male mice while solid lines represent those of female mice.

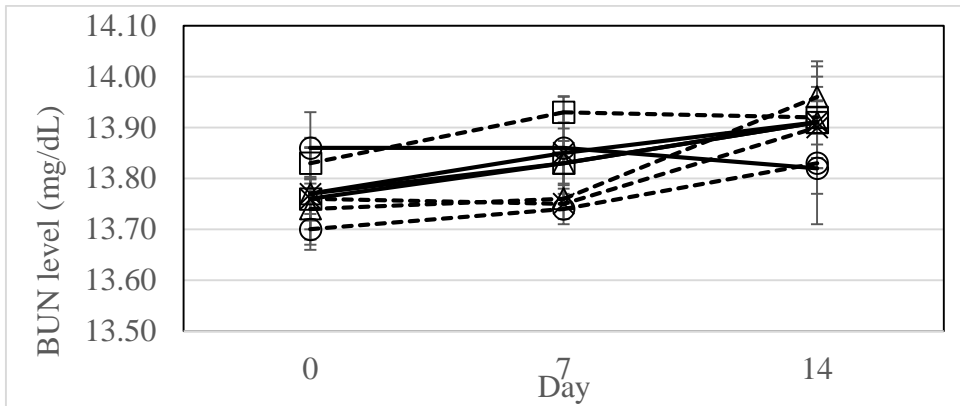


Figure 5: Blood urea nitrogen (BUN) levels of mice treated with distilled water (×), and Lansioside D at low dose (○), middle dose (Δ) and high dose (□) levels. Broken lines represent those of male mice while solid lines represent those of female mice.

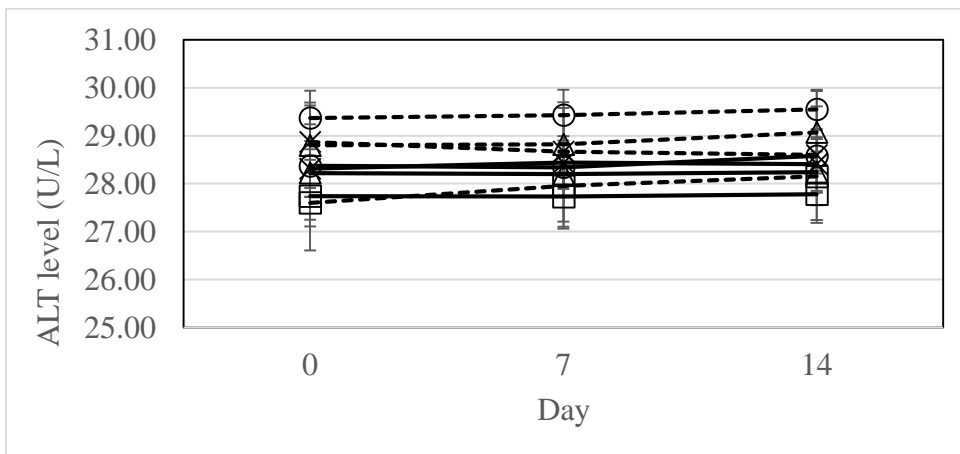


Figure 6: Alanine aminotransferase (ALT) levels of mice treated with distilled water (×), and Lansioside D at low dose (○), middle dose (Δ) and high dose (□) levels. Broken lines represent those of male mice while solid lines represent those of female mice.

considering the day of blood collection, treatment group and sex of the mice. Values of  $P < 0.05$  were considered statistically significant.

## RESULTS AND DISCUSSION

### Acute oral lethality

Lansioside D was administered to the treatment groups at three different doses. The low dose of 31.25 mg/kg body weight was based on the MIC of Lansioside D against *Staphylococcus aureus*<sup>1</sup>. The middle dose of 500 mg/kg

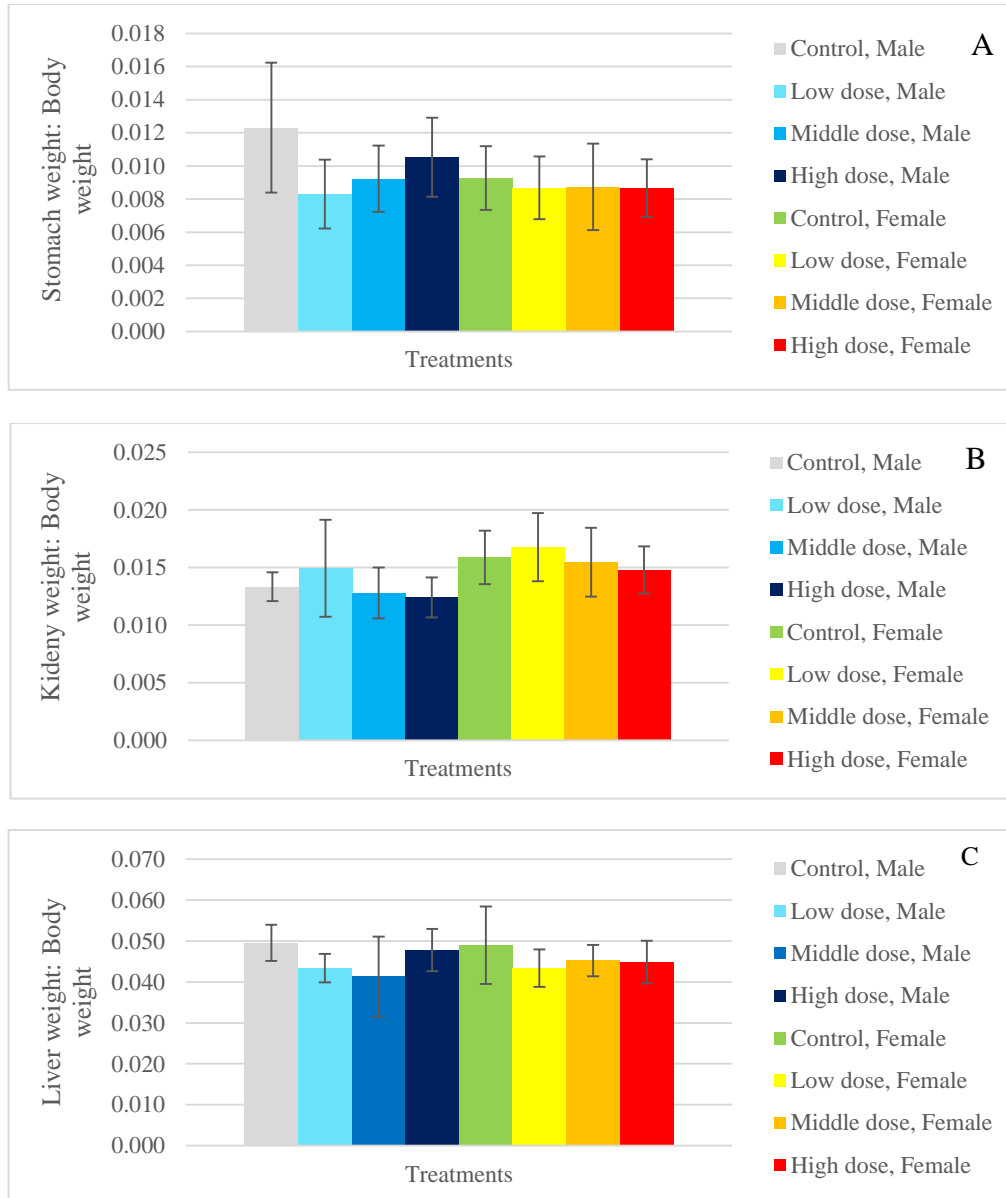


Figure 7: Relative weights of the stomach (A), kidneys (B) and liver (C) of male and female mice treated with distilled water (control) and Lansioside D at three dose levels (low dose= 31.25 mg/kg, middle dose= 500 mg/kg, high dose= 1000 mg/kg); n=10.

body weight was based on the recommended dosage of Vancomycin which is considered the drug of last resort for *S. aureus* infection<sup>8</sup>. The high dose of 1000 mg/kg body weight was twice the amount of the recommended dosage for Vancomycin and was set as the upper limit since Lansioside D started to become insoluble in water at a higher concentration.

Hourly monitoring for 24 h after a single oral administration of Lansioside D showed no mortality of the mice in the control and the treatment groups. There was also no physical, behavioral and physiological changes observed in the mice of the control and the treatment groups suggesting that Lansioside D has no acute oral toxic effect in mice when used up to 1000 mg/kg body weight.

#### Body weight and body weight gain

Figures 2A-B show the body weight and body weight gain of male and female mice during the 14-day observation period after a single oral dose of Lansioside D. No significant differences were observed in the body weight of mice among the groups ( $P=0.613$ ) and between the sexes ( $P=0.822$ ) within the observation period. All mice exhibited an increase in weight during the 14-day observation period. However, the body weight gain was not significantly different among all groups ( $P=0.560$ ) and between the sexes ( $P=0.671$ ) within the study period. These data suggest that Lansioside D does not affect the body weight and weight changes of mice.

#### Daily feed and water intakes

Figures 3A-B show the daily feed intake and daily water intake of male and female mice of the control and treatment groups. There was no significant difference



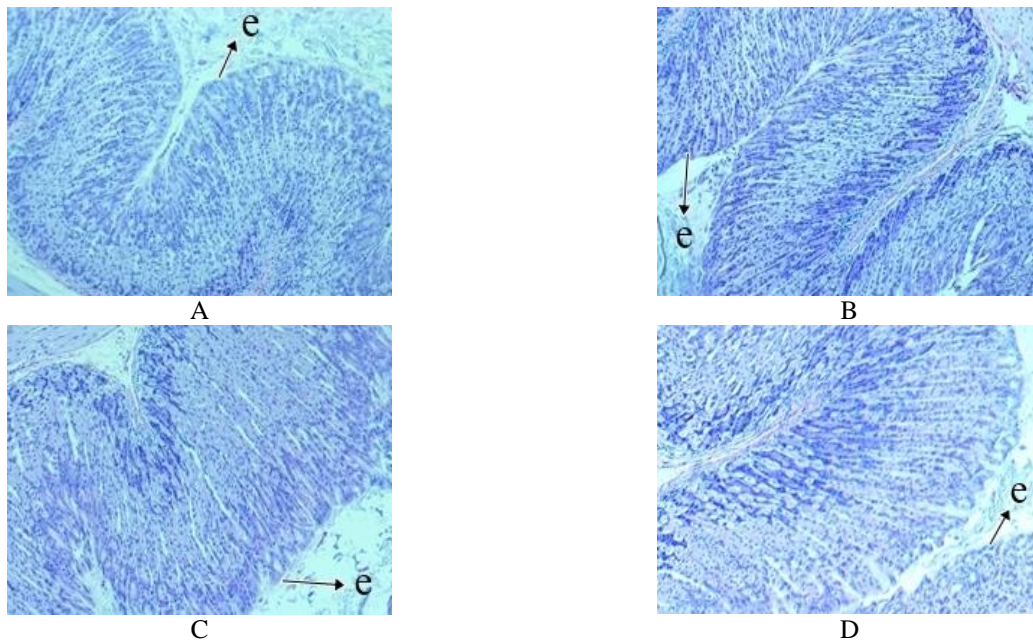


Figure 8: Stomach sections of mice treated with distilled water (control, A) and Lansioside D at three dose levels (low dose, B; middle dose, C; high dose, D) under the light microscope. (e = epithelial cells).

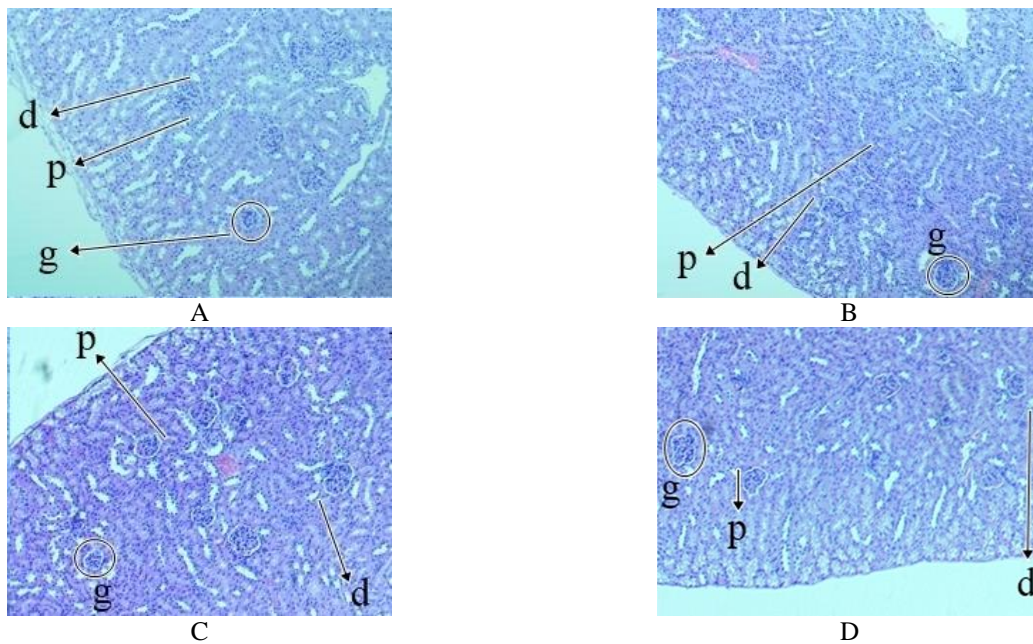


Figure 9: Kidney sections of mice treated with distilled water (negative control, A) and Lansioside D at three dose levels (low dose, B; middle dose, C; high dose, D) under the light microscope. (g = glomerulus, p = proximal convoluted tubule, d = distal convoluted tubule).

observed in the daily feed intake among the groups ( $P=0.328$ ) and between the sexes ( $P=0.524$ ). For the daily water intake of male and female mice, there was also no significant difference observed among all groups ( $P=0.114$ ) and between the sexes ( $P=0.129$ ).

**Blood chemistry**

Three key indicators were used to determine the effect of Lansioside D on kidney and liver functions, namely: creatinine, BUN and ALT levels. Creatinine is a chemical waste molecule produced from muscle metabolism. It is

carried through the bloodstream to the kidneys which filter out most of the creatinine and dispose of it in the urine. If kidneys are damaged, creatinine level in the blood will rise due to its poor excretion by the kidneys<sup>9</sup>. Figure 4 shows the creatinine levels of male and female mice in the control and treatment groups at days 0, 7 and 14. Values obtained from the control group were all normal and within the reported ranges<sup>10,11</sup>. Creatinine levels in all the treatment groups were not significantly different with the control group ( $P=0.160$ ) and no difference was observed between sexes ( $P= 0.451$ ) throughout the experimentation period.

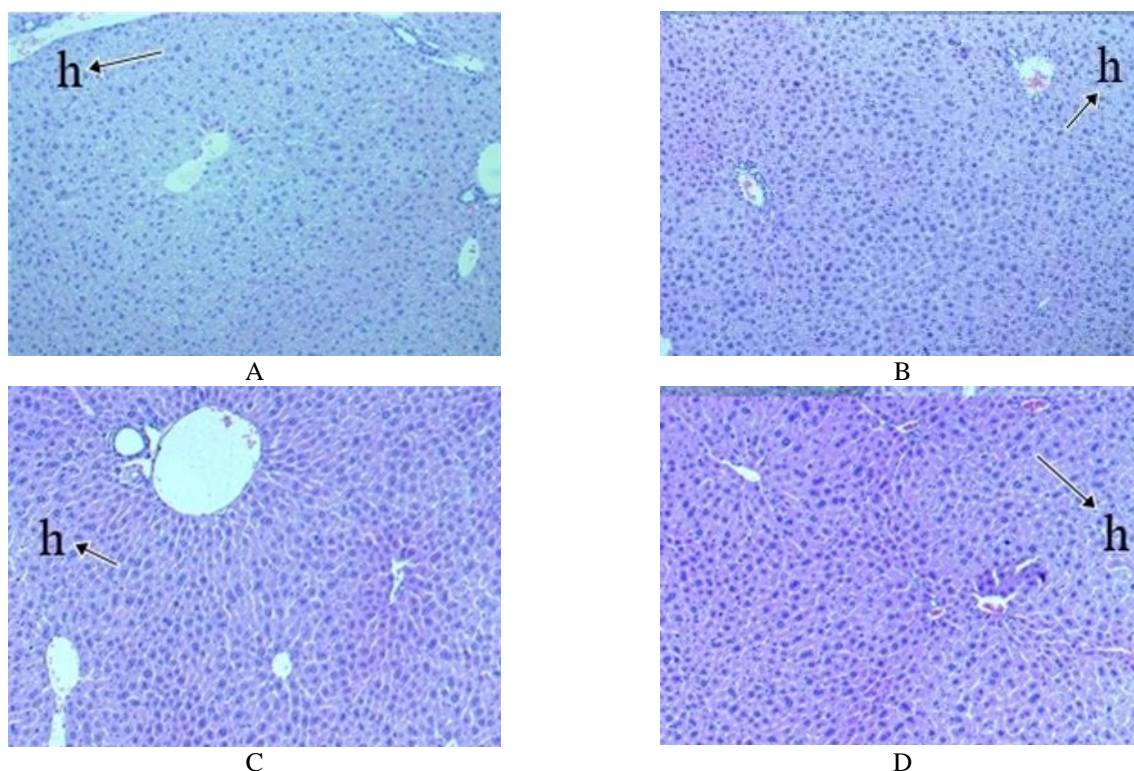


Figure 10: Representative liver sections of mice treated with distilled water (negative control, A) and Lansioside D at three dose levels (low dose, B; middle dose, C; high dose, D) under the light microscope. (h = hepatocytes).

BUN is another indicator of kidney function. Breakdown of protein in the liver produces ammonia which contains nitrogen. The nitrogen combines with carbon, hydrogen and oxygen to form urea. Urea travels from liver to kidneys through the blood stream. Healthy kidneys filter urea and remove other waste products. BUN levels higher than normal values indicate that kidneys are damaged. Figure 5 shows the BUN levels observed in mice of the control and treatment groups of both sexes on days 0, 7 and 14. All values fall within the normal range<sup>10,11</sup> and no significant difference ( $P=0.454$ ) was observed for the BUN levels between the control group and all the treatment groups.

Normal creatinine and BUN levels observed in mice of the control and treatment groups of both sexes suggest that Lansioside D causes no damage to kidney.

ALT is an enzyme associated with integrity of the liver. Normally, low levels of ALT are found in the blood. But when the liver is damaged, it releases ALT to the blood stream resulting to high ALT levels. Figure 6 shows the ALT levels of male and female mice in the control and treatment groups obtained at days 0, 7 and 14. Results showed that blood ALT levels from the control group were within the normal ranges<sup>10,11</sup>. No significant difference was observed in the ALT level of the control and treatment groups suggesting that Lansioside D at any tested concentration is not damaging to the liver.

#### *Gross morphology and weights of the organs*

Gross examination of the stomach, kidneys and liver of the mice in the control and treatment groups showed that they were intact and of normal sizes, with no apparent lesions, discoloration, nor evidence of necrosis. The relative organ weights are presented in Figures 7A-C. No significant

difference was observed in the relative stomach weight among all groups ( $P=0.388$ ) and between sexes ( $P=0.107$ ). There was also no difference observed in the relative kidney weight among all groups ( $P=0.077$ ) and between the sexes ( $P=0.061$ ). Similarly, no difference was observed in the relative liver weight among the groups ( $P=0.090$ ) as well as between the sexes ( $P=0.621$ ). Since there was no significant difference in the gross morphology and the relative organ weights of all the treatment groups and the control group, these data suggest that administration of Lansioside D had no noticeable effect on stomach, kidneys and liver of mice.

#### *Histological evaluation of the organs*

Photomicrographs of representative sections of the stomach, kidneys and liver taken from mice of the control and treatment groups are presented in Figures 8-10. Stomach sections (Fig. 8) of both the control and treatment groups have straight gastric pits lined by columnar epithelial cells with basally placed nuclei and dense, darkly eosinophilic cytoplasm. Kidney sections (Fig. 9) of both the control and treatment groups showed normal renal corpuscles, renal capsule and parenchyma. Similarly, the liver sections (Fig. 10) of both the control and the treatment groups showed normal architecture of the portal triad, as well as normal hepatocytes and sinusoids. In general, histological examination of these organs revealed no significant abnormal findings.

#### **SUMMARY AND CONCLUSION**

No mortality as well as deviations from normal, physical and behavioral activities was observed on mice of the treatment and control groups within the first 24 h of

observation. No significant differences were also observed on the body weight, body weight gain, as well as feed and water intakes. Blood creatinine, BUN and ALT levels all fall within the normal range for mice, and no significant difference was observed in mice of the treatment and control groups within the observation period. Gross morphological examination of the stomach, kidneys and liver showed no abnormalities caused by Lansioside D. Relative organ weights of the stomach, kidneys and liver also showed no significant differences among all treatment groups and the control group. Histological examination of these organs also showed no abnormalities. Based on the above results, it can be concluded that Lansioside D can be safely ingested up to doses as high as 1000 mg/kg body weight without affecting the parameters evaluated. These results could be used as a scientific basis for further development of Lansioside D as a potential new antibiotic.

#### ACKNOWLEDGEMENT

Authors gratefully acknowledged the financial support provided by the Department of Science and Technology of the Philippine government through PCAARRD and PCHRD project grants.

#### REFERENCES

1. Marfori, E.C., Kajiyama, S., Fukusaki, E. and Kobayashi, A. (2015). Lansioside D, a new triterpenoid glycoside antibiotic from the fruit peel of *Lansium domesticum* Correa. *J. Pharmacog. Phytochem.* 3(5):140-143.
2. Yannai, S. (2004). Dictionary of food compounds with CD-ROM: Additives, flavors and ingredients. Boca Raton: Chapman and Hall/CRC.
3. Nishizawa, M., Nishide, H., Kosela, S., and Hayashi, Y. (1983). Structure of Lansiosides: Biologically Active New Triterpene Glycosides from *Lansium domesticum*. *J. Org. Chem.* 48:4462-4466.
4. Marfori, E., Zulaybar, T., Kajiyama, S., Fukusaki, E. and Kobayashi, A. (2006). Isolation of the major antimicrobial compound from *Lansium domesticum* and its activity against methicillin-resistant *Staphylococcus aureus*. *Microbiology and Biotechnology: Roadmaps and Milestones for Enhancing Sustainable Productivity in the Asia-Pacific Region.* 297-300.
5. Crossley, K.B., Jefferson, K.K., Archer, G.L., and Fowler, V.G., Jr. (2009). *Staphylococci in Human Disease.* (2nd ed.). Oxford: Blackwell Publishing, Ltd.
6. Kable (2015). Impact of Antibiotic Resistance. Retrieved April 17, 2015 from <http://www.drugdevelopment-technology.com/projects/tygacil/tygacil3.html>.
7. Hayes, A.W. (2001). Principles and Methods of Toxicology. (4th ed.) Philadelphia: Taylor and Francis Group, LLC.
8. Cui, L., Iwamoto, A., Lian, J. Q., Neoh, H. M., Maruyama, T., Horikawa, Y., and Hiramatsu, K. (2006). Novel mechanism of antibiotic resistance originating in vancomycin-intermediate *Staphylococcus aureus*. *Antimicrobial Agents and Chemotherapy* 50(2): 428-438.
9. Haschek, W.M., Rousseaux, C.G. and Wallig, M.A. (2010). Fundamentals of Toxicologic Pathology, (2nd ed). San Diego: Academic Press.
10. Wolfensohn, S. and Lloyd, M. (1998). Handbook of Laboratory Animal Management and Welfare. Oxford: Blackwell Science Ltd.
11. Suckow, M.A., Danneman, P. and Brayton, C. (2001). The Laboratory Mouse. CRC Press, Inc.